ORIGINAL RESEARCH PAPER

Volume-8 | Issue-3 | March-2019 | PRINT ISSN No 2277 - 8179

INTERNATIONAL JOURNAL OF SCIENTIFIC RESEARCH

# FETUS-IN-FETU: A RARE DEVELOPMENTAL ANOMALY ( A CASE STUDY AND REVIEW OF LITERATURE)

**Radiodiagnosis**

**Dr. Anil Joshi** M.D., D.M.R.D., Prof. and Head, Dept. of Radiodiagnosis, Bharati Vidyapeeth (Deemed To Be University), Medical College and Hospital, Sangli, Maharashtra

**Dr. Rajani Joshi*** M.S., Prof. and Head, Dept. of Anatomy, Govt. Medical College, Miraj, Maharashtra. *Corresponding Author

## ABSTRACT

The fetus-in-fetu is a very rare abnormal embryogenesis of twinning where a malformed prasitic foetus is found in the body of its twin.
Case Study: This report presents a case of fetus-in-fetu diagnosed prenatally using Doppler ultrasonography.
Discussion: "Fetus-in-fetu" is estimated to occur in 1 in 5,00,000 live births. This rare congenital anomaly occurs due to aberration in the diamniotic monozygotic twinning with unequal division of inner cell mass of blastocyst leading to inclusion of small cell mass inside the developing host foetus. Only about 100 cases are reported worldwide. Various etiologies are discussed in the present study.
Conclusion: Fetus-In-Fetu is a rare entity that typically presents as an abdominal mass in infancy or early childhood. With recent advances in prenatal sonography, the diagnosis of Fetus-In-Fetu, as shown in this case, can be made more accurately in the prenatal period.

## KEYWORDS

Anomaly, Embryogenesis, Organogenesis, Teratoma, Twinning.

## INTRODUCTION:

Fetus-In-Fetu is a rare developmental anomaly in which a fetus is incorporated within its twin.

Incidence is 1 in 5,00,000 live births with fewer than 100 cases reported worldwide.[1] Males seem to be affected more than females. (2:1 male predominance is reported.)[2]

It was first described by Johann Friedrich Meckel in early 18th century.[3] First reported case was cited in 1808 by George William Young.[4] Very few cases of fetus-in-fetu were detected prenatally by Ultrasonography.

It represents a malformed monozygotic, diamniotic parastic twin internalized in a host twin.

**Synonyms:** Cryptodidymus, suppressed twin, double monster, dermocyma, endocyme fetus, fetiform teratoma, fetal inclusion.

It was defined by Willis in 1935 as a mass containing a vertebral axis often associated with other organs and limbs around this central axis.[5] Gonzalez – Crussi further defined Fetus-In-Fetu as 'any structure in which the foetal form is in a very high developmental stage of organogenesis' and linked it to the presence of a vertebral axis.[6]

The development of the encased foetus had advanced at least beyond the primitive streak stage (12 to 15 days of gestation) to a notochord, which is the precursor of the vertebral column.

The majority of the cases reported are found in early infancy, with the oldest reported case being that of a 47 year old man.[7]

### Localization:

80% of Fetus-In-Fetu masses were localized in the retroperitoneal[8] areas of upper abdomen. When located in testes, they may be intraperitonial. The affected testes are usually ectopic or undescended, probably because the added fetus-in-fetu impairs the migration of germ cells in testes.

Other sites reported are in Liver[9], Lesser Sac, Kidney, Pelvis, Mesentery, Sacrococcygeal region[10], inguinal region and testicles.[11] Atypical locations are Cranium [12], Scrotum[13], Mouth, Adrenal gland, Mediastinum, Lymph nodes, Lateral ventricles.

Fetus-In-Fetu is usually single, but upto 5 foetuses have also been reported. Daga et al had reported double fetus-in-fetu in an adult.[14]

## CASE STUDY

A 20 years old primygravida with approximately 18 weeks gestation came to a radiological diagnostic centre for a routine obstetric sonography examination. There was no history of consanguinity and no family history of multiple pregnancies. In the current pregnancy, there was no maternal illness, history of drug intake or exposure to radiation. The test was performed , on Samsung medison-accuvix 30, 4D Doppler machine and was reported by an experienced radiologist.

## OBSERVATIONS

Approximately 18 weeks fetus revealed, a well defined intra-abdominal cystic lesion measuring 30 mm x 40 mm simulating gestational sac in juxta umbilical region within host fetus, showing heterogeneous tissues suspended in fluid, including few of them simulating bones/spine within it. Doppler study revealed pulsatile beating rudimentary heart with a rate of 180 beats/min in it. This mass was attached to placenta by a cord showing pulsating connecting vessles. The embryonic age of this encased fetus was approximately of 8 weeks.

This was diagnosed as Fetus-In-Fetu since it showed derivatives of all three germinal layers viz. bones, soft tissues, beating heart, cartilages etc. Therefore diagnosis of Fetus-In-Fetu was more considered than highly differentiated teratoma.

The ability to detect fetus-in-fetu on prenatal ultrasonography was first reported by Nicolini et al in (1983).[15]

Presence of whole or part of vertebral column with other axial and/or appendicular bones and/or organs constitutes hall mark of Fetus-In-Fetu.

All reported cases of Fetus-In-Fetu concluded that 91% of cases had a vertebral column, 82.5% had limbs, 55.8% had a central nervous system, 45% had a gastrointestinal tract, 40% had vessels, and 26.5% had genito-urinary system. In all cases, the fetus was anencephalic and the lower limbs were more developed than the upper limbs. Now a days, Fetus-In-Fetu is not seen upto such developmental level due to prevelance of anomaly scans between 18 to 24 weeks of gestation.

## ULTRASONOGRAPHY IMAGES WITH COLOR DOPPLER

**Image No. 1**

Showing host twin's abdomen with gestational sac. The gestational sac was showing heterogenous mass suspended in fluid which is Fetus-In-Fetu. Posteriorly placenta and host twin's vertebra seen in transverse section.

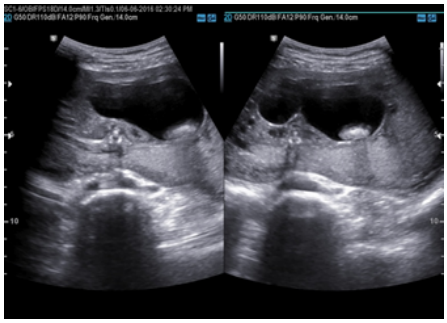

**Image No. 2**
Showing
A) Femur of host twin for estimation of gestational age.
B) Gestational sac with Fetus-In-Fetu in it.
C) Host foetal head.
D) Maternal cervical canal taken to measure its length.

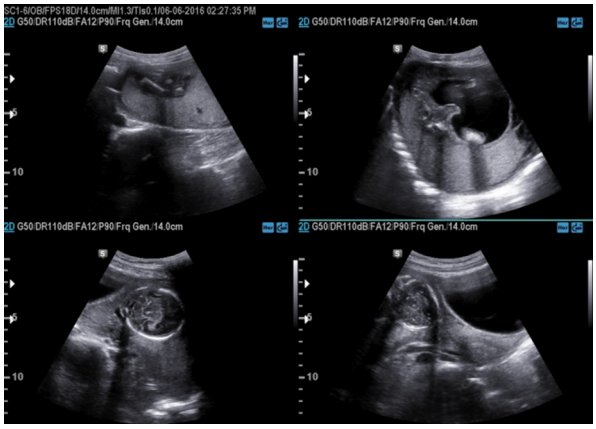

**Image No. 3 : Showing intact spine of host fetus with gestational sac in its abdomen.**

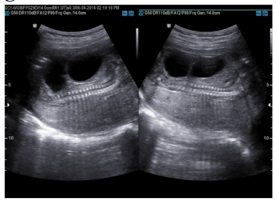

**Image No. 4 : Showing host twin's head. Normal ventricles and parenchyma seen in it.**

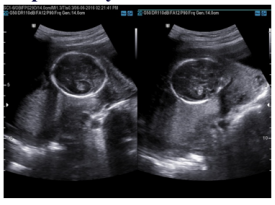

**Image No. 5: Note acoustic shadows indicating presence of bones / calcification.**

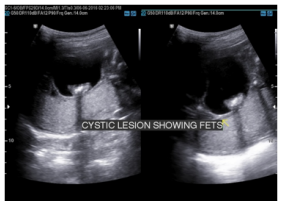


**Image No. 6 : Showing connection between host twin and Fetus-In-Fetu with pulsatile vessles.**

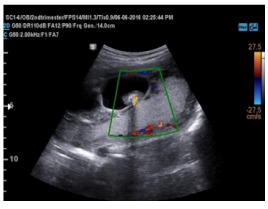

**Image No. 7: Showing cardiac activity of host twin. bdomen.**

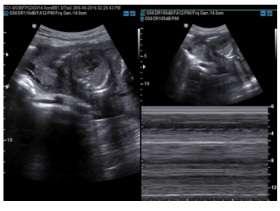

**Image No. 8: Color Doppler study to show rudimentary beating heart of Fetus-In-Fetu.**



## DISCUSSION

Fetus-In-Fetu is a rare congenital condition secondary to the abnormal embryogenesis in a monochorionic diamniotic pregnancy.

According to Spencer[16], fetus in fetu is defined by the presence of one or more of the following characteristics: (1) it is enclosed within a distinct sac; (2) it is partially or completely covered by normal skin; (3) it has grossly recognizable anatomic parts; and (4) it is attached to the host by a pedicle containing a few relatively large blood vessels, (5) either it is located immediately adjacent to one of the sites of attachment of conjoined twins or is associated with the neural tube or the G.I. system. The true etiology is unclear. Various theories have been postulated.

**Etiologies:**

- A primordial organizer defect was once thought to be underlying cause of Fetus-in-fetu.
- According to another theory, the germ cells of host may get evolevd on their own to form Fetus-in-fetu.
- According to continuum theory of monozygous twin, there occurs a progression from normal twin to parastic twin and then teratoma is hypothesized.
- A parathenogenetic origin has also been suspected. In this theory, normally located germ cells in retroperitoneal region are stimulated and get evolved into a rudimentary fetus.[17] Histocompatibility studies and gene markers do not support this etiology.
- In monochorionic twins, anastomoses between vitelline vessels are assumed to cause fetus-in-fetu. The cardiac development of affected twin is impaired leading to arrested grwoth of twin, and as the host twin grows, affected twin gets embedded withing host twin.
- In few cases intracrainal localization of fetus-in-fetu is found which is explained as due to, a second differentiation focus occuring in primitive knot or Hensen's node in the bilaminar embryo. This second focus grows slower than the primary focus, so gets engulfed in the invagination of cells and is arrested intracranially.
- Teratoma theory- Fetus in fetu may be a very highly differentiated form of mature teratoma.
- Parasitic twin theory-Fetus in fetu may be a parasitic twin fetus growing within its host twin. Very early in a monozygotic twin pregnancy, in which both fetuses share a common placenta, one fetus type wraps around and envelops the other. The enveloped twin becomes a parasite, in that its survival depends on the survival of its host twin, by drawing on the host twin's blood supply. The parasitic twin is anencephalic (without a brain) and lacks some internal organs, and as such is almost always unable to survive on its own. This is the most widely accepted theory.
- As described by Lewis[18], this abnormality results from an unequal division of totipotent inner cell mass of the developing blastocyst leading to the inclusion of a smaller cell mass within a maturing sibling embryo.
- Beaudoin's[19] theory states that there is defective implantation during the second week of development resulting in invasion of a second embryo into the extra-embryonic mesenchyme of the host fetus , instead of the uterine wall. Foetus-In-Fetu's organs have a blood supply from the host, and they all present critical defects.

It is a rare form of monozygotic twinning whereby an aberrant asymmetric twin becomes internalized in the other twin by unknown mechanism, thus acting like a parasite. There is arrest of further growth of the encased fetus due to improper blood supply or inherent defects of the encased twin. It has no prospects of any life outside of the host twin. Moreover, it poses clear threats to the life of the host twin on whom its own life depends.

Associated anomalies: In the host, complications due to the space-occupying nature of the lesion may be observed.

In fetus-in-fetu, essentially every anomaly resulting from hypoxia and arrested growth has been described. This is manifested by omphaloceles, major neural tube defects such as anencephaly, limb defects, Aplasia or hypoplasia of the organs derived from the mesoderm and ectoderm is invariably found in fetus-in-fetu.

The fetus-in-fetu is in the form of an encapsulated vertebrate tumour with a pedicle. Characteristically, it will be composed of a fiberous membrane (simulating chorioamniotic membrance) that contains some fluid (equivalent to the amniotic fluid) and a malformed fetus suspended by a cord or a pedicle.

The symptoms of foetus-in-fetu are those related to its site of presentation and its mass effects. In the abdomen, the symptoms are those of abdominal distention, feeding difficulties, vomiting, jaundice etc.

There is no report of recurrence. It is a benign disorder. Only one case of malignant transformation has been reported in literature.[20]

**Differential Diagnosis**

- • A highly differentiated teratoma - A teratoma is an accumulation of pluripotential cells in which there is neither organogenesis nor vertebral segmentation. It has got definite malignant potential. They are more likely to occur in the pelvis, ovary, sacrococcygeal

regions. They do not have body coelom. They show a female preponderance.
- Meconium pseudocyst - Meconium pseudocyst is usually associated with pneumoperitoneum, ascites or peritonitis.
- Neuroblastoma - To diagnose neuroblastoma, urine catecholamine profile is performed.

**Treatment:**
- Complete surgical excision should be performed and the excised Fetus-in-Fetu sent for detailed pathologic investigation including genetic testing.
- Excision with covering membrane is necessary, as a case of malignant transformation of left over membrane is reported in literature.
- These cases are monitored with tumour markers (alpha-feto protein) and beta-HCG (Human Choronic Gonadotropin) along with ultrasonography and other radiological investigations; at least for two years.

## • CONCLUSIONS

- Fetus-In-Fetu is a rare entity that typically presents as an asymptomatic slow growing abdominal mass in infancy or early childhood.
- With recent advances in prenatal sonography the diagnosis of Fetus-In-Fetu, as shown in this case, can be made more accurately in the prenatal period.
- Though it is a very rare entity, it can be diagnosed if it is kept in mind as a differential diagnosis for any fetal abdominal mass in infancy or in early childhood.
- Complete excision is curative and allows confirmation of the diagnosis.

## REFERENCES :


1 Grant R, Pearn JH. Foetus-in-foetu. Med J Aust 1969; 1:1016-20.
2 Federici S, Ceccarelli PL, Ferrari M, Galli G, Zanetti G, Domini R. Fetus in fetu: report of three cases and review of the literature. Pediatr Surg Int. 1991;6(1):60–5.
3 Luzzatto C, Talenti E, Tregnaghi A, et al: Double fetus in fetu: Diagnostic imaging. Pediatr Radio1 1994; 24: 602-03.
4 Young GW. Case of a foetus found in the abdomen of a boy. Med Chir Trans 1809; 1: 234-62.
5 Willis R. The structure of teratoma. J Pathol Bacteriol 1935; 40:1-36.
6 Gonzalez-Crussi F. Extragonadal teratomas. Atlas of Tumor Pathology. Washington DC: Armed Forces Institute of Pathology, 1982
7 Hoeffel C, Khoang Q, Tran T, Fornes P. Fetus in fetu: a case report and literature review. Pediatrics 2000; 105: 1335–44.
8 Eng HL, Chuang JH, Lee TY, Chen WJ. Fetus in fetu: a case report and review of the literature. J Pediatr Surg. 1989;24(3):296–9.
9 Al-Baghdadi R: Fetus in fetu in the liver: Case report and review of the literature. J Pediatr Surg 1992; 27: 1491-92
10 Karasimbarao KL, Mitra SK, Pathak IC: Sacrococcygeal fetus-in-fetu. Indian Pediatr 21: 820-2, 1984.
11 Alpers CE, Harrison MR: Fetus-in-Fetu associated with an undescended testis. Pediatr Pathol 437-46, 1985.
12 Kimmel DL, Moyer EK, Peale AR, et al: A cerebral tumor containing five human fetuses. A case of fetus-in-fetu, Anat Rec 106: 141-65, 1950
13 Kakizoe T, Tahara M: Fetus-in-fetu located in the scrotal sac of a newborn infant: a case report. J Urol 107:506-8, 1972.
14 B.V. Daga, V A Chaudhary et al: Double fetus in fetu: CT scan diagnosis in an adult; Indian J Radio Imaging; 2009 Aug. 19 (3):2016-2018.
15 Nicolini U, Dell' Agnola CA et al: Ultrasonic prenatal diagnosis of fetus-in-fetu. J Clin Ultrastruct 1983;11:321-2.
16 Spencer R. Parasitic conjoined twins: external, internal (fetuses in fetu and teratomas), and detached (acardiacs). Clin. Anat. 2001;14(6):428–44.
17 Grosfeld JL, Stepita DS, Nance WE et al: Fetus-in-fetu: as unusual cause for abdominal mass in infancy. Ann Surg 180:80-84, 1974.
18 Lewis RH. Foetus in foetu and the retroperitoneal teratoma. Arch Dis Child 1961; 36: 220-6.
19 Beaudoin S, Gouizi G, Mezzine S, Wann AR, Barbet P: Mediastinal fetus in fetu. Case report and embryological discussion. Fetal Diagn !er. 2004,19:453-455.
20 Hopkin KL, Dickson PK et al: Fetus in fetu with malignant recurrence. J Pediatr Syrg 1997; 32:1476-1479.