ORIGINAL RESEARCH PAPER

Volume-8 | Issue-4 | April-2019 | PRINT ISSN No 2277 - 8179

INTERNATIONAL JOURNAL OF SCIENTIFIC RESEARCH

FLOATING BALL SIGN: A RARE BUT SPECIFIC SIGN OF MATURE CYSTIC TERATOMA

Radiodiagnosis

Dr. Amala Ammu Mathew Second Year PG Student, Department Of Radiology. K. S. Hegde Medical Academy, Nitte University, Mangalore -575018

Dr. Rohini . A* Associate Professor, Department Of Radiology, K. S. Hegde Medical Academy, Nitte University, Mangalore -575018 *Corresponding Author

ABSTRACT

Mature cystic teratoma are the most common neoplasm of the ovary which includes at least two well – differentiated germ cell layers. The varying arrangements of tumor contents and combination of the mature tissue derivatives are responsible for spectrum of the imaging appearance of these lesions. However due to the presence of fat and calcification which forms the predominant content of the lesion, these tumors are readily identified by CT. However they are rarely missed on USG and MRI due to its classical tumor components and signs which were reported in various studies in the past. In this case report we presented a classical but rare presentation of cystic teratoma which was diagnosed by CT with further characterization by MRI.

KEYWORDS

Ovary, cyst, Teratoma, Dermoid, Fat ball.

INTRODUCTION:

Ovarian teratoma is the most common germ cell tumor which accounts for about 20% of all ovarian neoplasms and are derived from totipotent cells[1].They are further divided into sub-categories of mature cystic teratomas, immature cystic teratomas, monodermal (highly specialized) teratomas (struma ovarii, carcinoid tumors, neuroectodermal tumors , sebaceous tumors) and fetiform teratomas [2, 3]. Mature cystic teratoma is the most common lesion among these tumors. Histologically, they show at least two well differentiated, mature germ cell layers (ectoderm, mesoderm, endoderm), among which the ectoderm and mesoderm are the most common in the tumor wall; therefore, mature tissues of the skin and hair (from the ectoderm), fat and muscle (from the endoderm) usually make up the composition of mature cystic teratoma [2]. Because of the presence of fat and calcifications ovarian dermoids are easily picked up by CT and also by USG /MRI.

Cystic teratomas are classified into 3 categories depending upon the contents and configuration. Type 1 shows layering of the floating debris. Second type shows nodular or palm tree like mural protrusions within. The third type shows fat fluid levels.

Here we are reporting a case of Dermoid cyst which was diagnosed on USG and CT which showed none of the classical features and showed multiple floating fat balls, septations, hair like structures and no characteristic calcifications, no bone or tooth like structures.

CASE REPORT

A 42 year old female presented with a 4 year history of abdominal distension. Her menstrual history was unremarkable. The medical and surgical history was unremarkable.On examination she was found to have a palpable mass in lower abdomen. It was not associated with pain or tenderness. All laboratory investigations were within normal limits including CA 125. The patient was referred to radiology department for further investigation. Ultrasonography of abdomen and pelvis followed by CT abdomen and pelvis with IV contrast were done. Limited sections of MRI pelvis were done for further confirmation of the diagnosis.

Ultrasonography revealed a well-defined large thin walled anechoic mass lesion (Fig 1) in the pelvis, extending to abdomen up to Umbilical region, which showed multiple small well circumscribed echogenic spherical masses in the nondependent portion and ill-defined echogenic linear strands in the dependent portion. There was no internal vascularity/ calcifications / tooth /bone like structures within. The left ovary was not visualized. The right ovary showed simple cystic lesion.

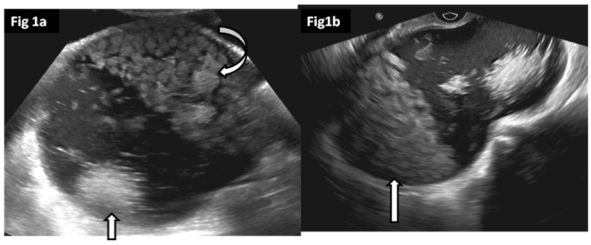

Figure1: USG image of pelvis shows anechoic lesion with multiple echogenic ball like structures in the non-dependent portion and echogenic linear strands along the dependent portion of the lesion.

Computed tomography was done for further characterization of the lesion, extent of the lesion and relation with other abdominal/pelvic structures. On contrast enhanced CT the lesion appeared as a well-defined, capsulated, non-enhancing hypodensity of mean 25HU in the pevi-abdominal region measuring 16 x14 x 12mm with multiple, floating, well-defined, round and oval, fat attenuating components (floating ball sign), largest measuring 2 cm in diameter [Fig 2]. There were no enhancing septations / solid components within. The mass was predominantly in the mid line pelvis with extension upto umbilicus and showed mass effect on the adjacent pelvic and intra-abdominal structures. The fat planes between the lesion and adjacent structures appeared well maintained. Left ovary was not separately visualized from the lesion.Right ovary showed a well defined cystic lesion measuring 3.5 cm.

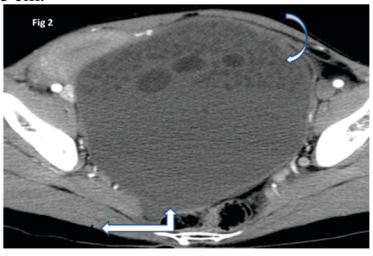

Figure: 2 CECT axial image of adnexal cystic lesion shows fat density spherical structures along the nondependent portion of the cyst.

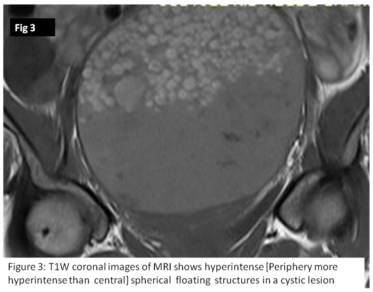

Figure 3: T1W coronal images of MRI shows hyperintense [Periphery more hyperintense than central] spherical floating structures in a cystic lesion

MRI evaluation was done in particular to confirm the origin of the lesion and for further characterization of the lesion.T1-weighted images (T1WI) showed a large cystic mass containing multiple hyperintense floating spherical structures within.The outer aspect of the spherules were hyperintense than the central part (Fig 3) .In T2–weighted images (T2WI) the outer aspect of the spherules were hypointense than the central part (Fig 4). T2 weighted fat suppressed images shows slightly decreased signal intensity, thus confirming that spherules were made up of lipid Leyden particles(Fig 5).

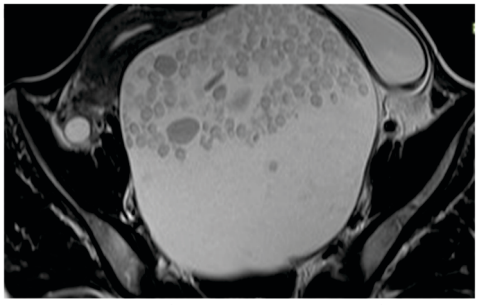

Figure 4: Axial T2W image of adnexal lesion shows hyperintense floating spherules which shows peripheral relatively hypointense rim compared to central portion of the spherules.

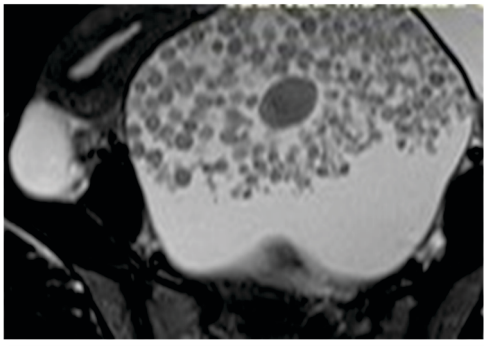

Figure 5: T2W fat suppressed image confirms fat content of the floating spherules.

Laparotomy revealed a large cystic mass in left ovary which measured 16 x 16 cm. Macroscopically the cyst had fatty fluid content and multiple white and yellow floating fat globules of varying sizes and little hair within.

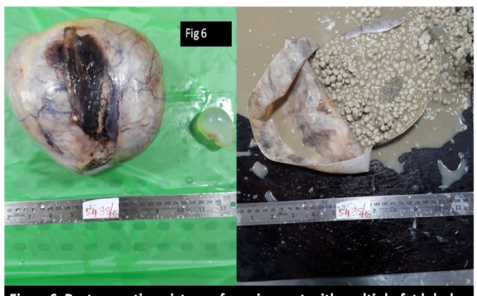

Figure6: Post operative picture of ovarian cyst with multiple fat lobules and fluid

DISCUSSION

Cystic teratomas are most common benign ovarian neoplasms [H 15%-25%]. They are derived from primitive germ cells of the embryonic gonad. They usually occur in active reproductive age group. They are rare before puberty and are infrequent in postmenopausal women. They contain derivatives of the “3” germ layers [ectoderm, mesoderm and endoderm]. However the ectodermal elements are predominant, hence are called dermoid cysts.

Melanocytes which are derivatives of ectoderm are distributed in hair matrix and they synthesize melanin, which gives color to the hair. The dermoid cysts are usually silent until they become palpable masses.Some cysts will be detected incidentally on plain radiographs due to clacification or tooth.Other complications are rupture [1%] or malignant transformation[2 %] which are rare [1,2,4,6]

In our case the women presented with abdominal pain secondary to mass effect of the large cyst compressing the abdominal and pelvic structures.

Cystic teratoma can be diagnosed readily by radiological investigations like USG, CT or MRI because of its cystic nature, contents, and solid component. Some specific features are important for diagnosis, which on USG are cyst with intracystic mural nodule [dermoid plug], fat fluid level, 'dermoid mesh sign' which is due to floating hair fibers gives appearance of multiple linear echogenic interface. Another specific feature is distal acoustic shadowing due to mixture of echogenic matted hair and sebum [tip of iceberg sign].

Our case did not show any of these classical signs. Instead showed a large cystic lesion with multiple floating balls with no calcification. This appearance of dermoid cysts was reported few in literature in different locations like inretroperitoneum, ovary and mediastinum. The composition of masses was different in different locations.The nodules of cystic teratomas of ovaries consist of sebaceous debris and hairs. In case of mature cystic teratomas of mediastinum the mobile globules contain paste like material, fat and hair. In case of mature cystic teratomas of retroperitoneum the fat deposition seen around the hair tissue.

In our patient the floating spherules consisted of paste like material, fat and some with hair. According to Kawamoto et al, this appearance of floating fat spherules in pelvic cystic mass was not seen in any other tuor and hence it is pathognomonic for cystic teratoma.

Computed tomography has a unique role in identifying tissues of different densities with precision like fat, cystic components and calcifications of the lesion which can be missed on USG and MRI. MRI has advantage over CT and USG because of its soft tissue contrast and Multiplanar imaging, and became an important diagnostic tool for pelvic imaging.

REFERENCES:

1. Rha SE, Byun JY, Jung SE, et al. Atypical CT and MRI manifestations of mature ovarian cystic teratomas. AJR Am J Roentgenol 2004; 183: 743–750.
2. Outwater EK, Siegelman ES, Hunt JL. Ovarian teratomas: tumor types and imaging characteristics. Radiogr Rev Publ Radiol Soc N Am Inc 2001; 21: 475–490.
3. Weiss JR, Burgess JR, Kaplan KJ. Fetiform Teratoma (Homunculus). Arch Pathol Lab Med 2006; 130: 1552–1556.
4. Hsiang C-W, Liu W-C, Huang G-S, et al. A floating ball: a pathognomonic sign of ovarian cystic teratoma. QJM Mon J Assoc Physicians 2014; 107: 319–320.
5. Choudhary S, Fasih N, Mc Innes M, et al. Imaging of ovarian teratomas: appearances and complications. J Med Imaging Radiat Oncol 2009; 53: 480–488.
6. Damarey B, Farine M, Vinatier D, et al. [Mature and immature ovarian teratomas: US, CT and MR imaging features]. J Radiol 2010; 91: 27–36.
7. Gürel H, Gürel SA. Ovarian cystic teratoma with a pathognomonic appearance of multiple floating balls: a case report and investigation of common characteristics of the cases in the literature. Fertil Steril 2008; 90: 2008.e17-19.