ORIGINAL RESEARCH PAPER

Volume-8 | Issue-1 | January-2019 | PRINT ISSN No 2277 - 8179

INTERNATIONAL JOURNAL OF SCIENTIFIC RESEARCH

GALACTORRHEA: A RARE PRESENTATION OF ACUTE CERVICAL INTERVERTEBRAL DISC PROLAPSE

Surgery

Susanta Meher* Department of Surgery, Vikash Multispeciality Hospital, Bargarh *Corresponding Author

Nishant Debta Department of Medicine, Vikash Multispeciality Hospital, Bargarh

Chandrakanta Nayak Department of Orthopaedics, Vikash Multispeciality Hospital, Bargarh

ABSTRACT

Galactorrhea can occur with or without hyperprolactinemia, however 90% of galactorrhea are associated with a high serum prolactin level. Stress is known to cause significant increase in prolactin level both in humans and experimental animal models. Hyperprolactinemia with galactorrhea following stress due to severe pain as a result of acute cervical prolapsed intervertebral disc with radiculopathy has not been mentioned in the literature. We report a case of a 32year multiparous female with normal menstrual cycle presenting with spontaneous galactorrhea with severe neck pain and radiculopathy.

KEYWORDS

Galactorrhea, Hyperprolactinemia, Stress, prolapsed intervertebral disc

Introduction

Galactorrhea or inappropriate milk secretion is a relatively common problem. Although exact incidence is not known, 20-25% of women experience this problem at some time of their life(1). Prolactin, a pituitary derived hormone is an essential factor for starting of lactation after child birth. An elevated level of prolactin has been found in 90% cases of galactorrhea(2). There is considerable evidence that acute stress can cause an increase in prolactin levels through the influence on hypothalamus and its neurotransmitters and neuromodulators(3). We present here a rare case of acute cervical intervertebral disc prolapse with radiculopathy presenting with spontaneous galactorrhea.

Case Report

A 32year multiparous female presented to our outpatient department with complain of severe neck pain and milky discharge from both the breast for five days. She started with sudden onset severe neck pain radiating to both upper limb, more on the right side. On the same day she complained of spontaneous milk discharge from both breast. There was no history of weakness or any sensory deficit on both upper limb. There was no history of headache, visual defect, or any previous history of drug intake. She was not a known case of any chronic illness like hypertension, renal failure, or hypothyroidism. She had no history of any surgical intervention of the breast or spine in the recent past. She had a normal menstrual cycle. Her youngest child was 4years old. On investigation she was found to have raised serum prolactin (104.5ng/ml) with normal TSH(1.41IU/ml) and serum creatinine (0.9mg/dl). All other routine laboratory investigations were within normal limits. Magnetic resonance imaging(MRI) of the cervical spine revealed mild poster bulge of C3-4, C4-5 and C5-6 compressing corresponding bilateral exiting roots at C5-6 and C6-7 levels [Figure 1a&b]. MRI of the brain with special evaluation of Sella did not reveal any obvious abnormality [Figure 1c]. Based on the findings of MRI and laboratory investigation a provisional diagnosis of acute cervical prolapsed intervertebral disc with stress induced hyperprolactinemia leading to galactorrhea was made. Patient was advised non steroidal anti-inflammatory drugs (NSAID) with muscle relaxant and physiotherapy. Neck pain improved, and breast discharge stopped after two weeks of treatment. A repeat serum prolactin after three weeks was normal(19ng/ml). After six months of follow up patient is doing well with no neck pain and galactorrhea.

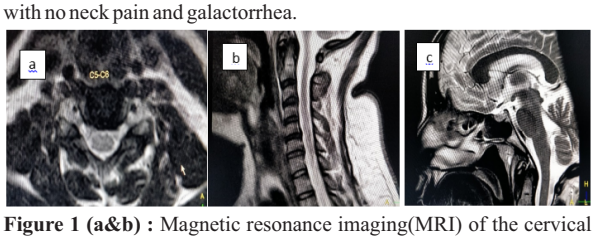

Figure 1 (a&b) : Magnetic resonance imaging(MRI) of the cervical spine showing mild poster bulge of C3-4, C4-5 and C5-6 compressing corresponding bilateral exiting roots at C5-6 and C6-7 levels. Figure 1(c): MRI of the brain with normal pituitary gland.

Discussion

Galactorrhea or inappropriate milk discharge from breast is estimated to be seen in 20 to 30% of female at some time in their life[(1)]. Cause of galactorrhea can vary from a long list of physiological to pathological conditions [Table 1][(4)]. Although the incidence is variable it can occur in 90% of patients with hyperprolactinemia[(2)]. Prolactin, a pituitary derived hormone is an essential factor in the production of milk after child birth. It is secreted by the anterior pituitary gland at a low basal rate, with the secretion being continuously suppressed by prolactin inhibiting factor (Dopamine) released from hypothalamus through hypothalamic-hypophysial portal system. Factors which stimulates prolactin secretion includes thyrotropin releasing hormone, Vasoactive intestinal peptide, opiates, estrogen, norepinephrine and possibly serotonin[(4)].

Table 1: Causes of Galactorrhea [(4)]

- **Physiologic conditions:** Pregnancy and postpartum state Breast stimulation "Witch's milk" in neonates
- **Neoplastic processes:** Pituitary adenoma (prolactinoma), Bronchogenic carcinoma, Renal adenocarcinoma, Lymphoma, Craniopharyngioma, Hypernephroma, Mixed growth hormone- secreting and prolactin- secreting tumors Null-cell adenoma
- **Hypothalamic-pituitary disorders:** Craniopharyngioma and other tumors Infiltrative conditions [Sarcoidosis, Tuberculosis, Schistosomiasis] Pituitary-stalk resection, Multiple sclerosis Empty-sella syndrome
- **Systemic diseases:** Hypothyroidism, Chronic renal failure, Cushing's disease, Acromegaly
- **Medications and herbs:** Antidepressant, Anxiolytics, Antihypertensive
- Chest wall irritation:Irritating clothes or ill-fitting brassieres Herpes zoster Atopic dermatitis Burns Breast surgery Spinal cord injury or surgery Spinal cord tumor Esophagitis Esophageal reflux
- **Idiopathic:** Hyperprolactinemia, Euprolactinemia

There is considerable evidence that stress has a role in prolactin secretion[(3)]. Hypothalamus with its neurotransmitters and neuromodulator play an important role in regulation of prolactin release. Stress having an important relationship with hypothalamic function, can influence prolactin release through its neurotransmitters. Recent studies have shown increase in serum prolactin level in acute stress, both in healthy man and women[(5)]. Although exact mechanism is not known, prolactin releasing peptide(PrRP) a stress modulator in central nervous system stimulates CRH mediated ACTH secretion. PrRP and norepinephrine together can modulate the hypothalamo-pituitary axis. Lennartsson A K et al proved in their study that magnitude of stress induced changes of prolactin strongly correlated with the magnitude of stress induced change in ACTH level[(5)]. Since both ACTH and prolactin are secreted from anterior pituitary gland and

their secretion is stimulated possibly by the same releasing factors, a high ACTH response during stress is expected to have a high prolactin response during stress. Thus acute severe pain being an established stressor can cause hyperprolactinemia and galactorrhoea.

Review of literature have shown galactorrhoea to be associated with spinal cord injury, spinal cord surgery and spinal cord tumour either as a complication or presenting symptoms[4]. Yarkony G M et al reported four cases of spinal cord injury presented with galactorrhoea[6]. The level of injury was T3, T6, T8 and T11 and the most probable cause of galactorrhoea was irritation of thoracic intercostal nerves, through the inhibition of dopamine release via autonomic nervous system (thoracic and cervical ganglion). The two most possible explanation of galactorrhoea in our case can be, stress induced hyperprolactinemia and inhibition of release of prolactin inhibiting factor dopamine through autonomic nervous system. Galactorrhoea can occur with or without hyperprolactinemia. A systematic evaluation with proper history, physical examination, laboratory investigations and imaging will help to identify the exact cause. There is considerable evidence that stress has a regulatory effect on prolactin secretion, however the exact pathophysiological mechanism of this response needs further evaluation.

Conflict of interest: None
Funding : None

REFERENCES

1. Patrascu OM, Chopra D, Dwivedi S. Galactorrhoea: Report of Two Cases. Mædica. 2015;10(2):136–9.
2. Colao A, Sarno AD, Cappabianca P, Briganti F, Pivonello R, Somma CD, et al. Gender differences in the prevalence, clinical features and response to cabergoline in hyperprolactinemia. Eur J Endocrinol. 2003 ;148(3):325–31.
3. Fava M, Guaraldi GP. Prolactin and stress. Stress Med. 1987;3(3):211–6.
4. Pena KS, Rosenfeld JA. Evaluation and Treatment of Galactorrhea. Am Fam Physician. 2001;63(9):1763.
5. Lennartsson A-K, Jonsdottir IH. Prolactin in response to acute psychosocial stress in healthy men and women. Psychoneuroendocrinology. 2011;36(10):1530–9.
6. Yarkony GM, Novick AK, Roth EJ, Kirschner KL, Rayner S, Betts HB. Galactorrhea: a complication of spinal cord injury. Arch Phys Med Rehabil. 1992;73(9):878–80.