ORIGINAL RESEARCH PAPER

Volume-8 | Issue-1 | January-2019 | PRINT ISSN No 2277 - 8179

INTERNATIONAL JOURNAL OF SCIENTIFIC RESEARCH

GIANT CELL TUMOR OF THE SECOND METATARSAL: A CASE REPORT AND BRIEF REVIEW OF LITERATURE

Orthopaedics

Saumya Pandey Senior Resident, Department of Pathology, Dr B.S.A. Hospital and Medical College, New Delhi

Pratima Khare Consultant, Department of Pathology, Dr B.S.A. Hospital and Medical College, New Delhi

Shailendra Khare* Consultant Orthopedic Surgeon, C.I.O., VMMC & Safdarjung Hospital, New Delhi *Corresponding Author

ABSTRACT

Giant cell tumor is a benign, locally aggressive tumor with features of local recurrences and potential of metastasis. GCT of small bones of hand and foot are of rare occurrence with very few case reports in the literature. Here, we report a case GCT of second metatarsal in an 18-year-old male. This patient had first surgery in the form of complete excision of tumor followed by free fibular graft. The recurrence occurred within six months of first surgery.

KEYWORDS

Giant cell tumor; metatarsal bones; destructive bony lesion; FNAC (Fine Needle Aspiration Cytology.

Introduction

Giant cell tumor (GCT) or osteoclastoma is an osteolytic, mostly benign, locally aggressive tumor with features of frequent local recurrences and the potential for the metastasis and the malignant transformation. It usually occurs in young adults of 16-35 years in the epiphyseal region. The male to female ratio is 3:5. Nearly 85-90% found in long bones, of which 50% occur in the region around knee, other frequent sites being distal radius, proximal humerus and fibula. 4% of GCT occurs in pelvic bone and spine. Involvement of small bones of hand and foot is very rare. Unni has reported an incidence of 2% in the hand and 1.5% in the foot (phalanges being more often involved than metacarpals and metatarsals)[1]. Here we report a case of GCT of 2nd metatarsal of right foot which is a very rare site for such tumor. The tumor was aggressive and widespread local recurrence of the tumor occurred within six months after en-block resection and free fibular graft. The patient was subsequently managed by above ankle amputation and is disease free at three years follow up.

Case Report

An eighteen years old male presented with chief complaints of swelling over the dorsum of right foot for the last 6 months which was gradually increasing in size. The swelling became painful for the last 3 months. The Pain was mild to moderate in intensity, dull aching, continuous, relieved by taking medicines and rest, aggravated by activities. There was no history of trauma or constitutional symptoms. Physical examination revealed a localized well defined oval shaped swelling over the dorsum of the right foot (8x5 cm.), opposing base of 2nd metatarsal [Fig 1A]. The skin overlying the swelling was stretched. There were no signs of inflammation. The second metatarsophalangeal joint was freely mobile but was painful on extreme movements.

X- Ray revealed an osteolytic lesion at base of second metatarsal of the right foot [Fig1B]. MRI revealed large multi-loculated expansile swelling with altered signals involving base and shaft of 2nd meta-tarsal, sparing the head. The overlying cortex was thinned out and scalloped. No other bone of the foot was involved. No definite diagnosis was made on MRI scan but the possibilities of Aneurysmal bone cyst (ABC) and Giant cell tumor (GCT) was suggested [Fig1C]. The fine needle aspiration cytology smears showed numerous osteoclastic giant cells and mononuclear cells [Fig 3A]. At places these giant cells were attached to the periphery of stromal fragments suggestive of Giant cell tumor. En-block tumor resection [Fig 2A] along with entire metatarsal was carried out, followed by free fibular graft [Fig2B]. The graft was fixed in place with K-wires [Fig 2C]. The tissue from the tumor was sent for histopathology. The section showed numerous osteoclast type giant cells scattered among uniform oval mononuclear cells, the diagnosis of giant cell tumor of bone was made on histopathology [Fig 3B]. The excised meta-tarsal ends were free from tumors on histopathology.

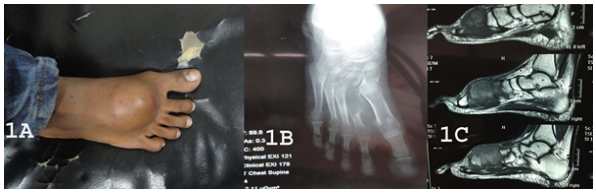

Fig1: [(1A: Swelling over dorsum of foot without any sign of inflammation); (1B: Lytic lesion at base of 2ND Meta-tarsal); 1C: MRI scan showing large multi-loculated expansile swelling of base of 2nd Meta-tarsal]

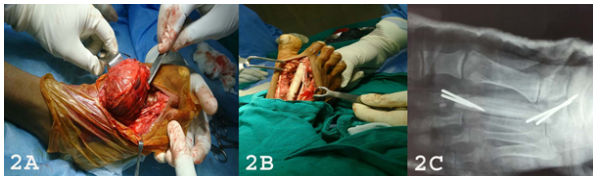

Fig2: [(2A: En-block tumor resection); (2B: Free fibular graft for Meta-tarsal); (2C: Fixation of graft with K-wires)]

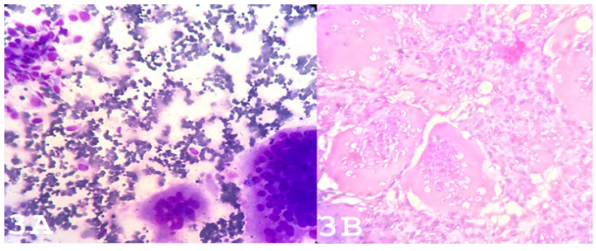

Fig3: [(3A: FNAC Giemsa stained smear showing osteoclast type giant cell and mononuclear cells) 10X40; (3B: Histopathological H&E stained section showing numerous osteoclast type giant Cells and uniform oval mononuclear cells in the background.)10X40]

Post-Operative period and recurrence: The immediate post-operative period was un-eventful. However, the patient had recurrence of swelling after about six months of the surgery in the same region of foot. After initial treatment at primary health center, the patient reported back to our center with an ulcerated lesion over previous surgical scar [Fig4A].

Further Management: The patient was thoroughly investigated. The radiological examination of the foot revealed destruction of the fibular graft, navicular, cuneiforms, part of 3rd Meta-tarsal and calcaneum bone, suggestive of aggressive nature of recurrence [Fig 4B]. Non-

Contrast Computerized Tomography (NCCT) right foot with 3 D reconstruction was carried out. This showed destructive lesion involving base of 2nd and 3rd metatarsal with adjoining cuneiform bones. Focal destruction of the margins of the cuboid, 1st metatarsal and inferior aspect of navicular was also seen .There was a well-defined lucent lesion seen in calcaneum. A diagnosis of recurrence of the tumor with destruction of fibular graft and adjoining small bones of foot with metastasis to calcaneum was made [Fig 4C]. Contrast- Enhanced Computed Tomography (CECT) Thorax and Abdomen were essentially normal with no evidence of metastasis. The patient was subjected to bone scan using 99mTc-MDP, which was suggestive of recurrence of tumor involving metatarsals and tarsal bones of the right foot. There was no evidence of skeletal metastasis over other parts of the body. In view of the non-salvageable stage of the foot, an above ankle amputation surgery was performed after informed consent. The gross examination of the amputated foot showed involvement of the bones of mid foot including 2nd and 3rd meta-tarsals, navicular [Fig 4D].grossly lesions were seen in calcaneum and cuboid as well. The histopathology of the lesion from foot showed features of giant cell tumor of bone. Margins of the amputated stump were free from tumor.

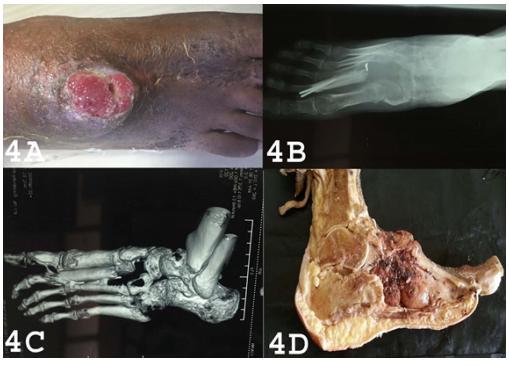

Fig4 [(4A: Ulcer over the old Surgical scar); (4B: X-ray showing destructive lesion of mid foot bones and fibular graft); (4C: 3D CT Scan showing destructive lesions of midfoot and a lesion in calcaneum) ; (4D: Amputated Foot showing lesions in midfoot involving navicular and 2nd Meta-tarsal and also a small lesion in calcaneum)]

Long term follow-up: Post-operative at three years in follow up, the patient is tumor free and is doing well on the prosthetic foot.

Discussion

Giant cell tumors (GCTs) of the small bones of the hands and feet are very rare[1-4]. GCTs found in the metatarsal bones tend to be more aggressive as compared to those originating in other bones[2,3]. The main subjective symptom of GCT of meta-tarsal is pain similar to the conventional GCT found in any other location[4]. The swelling is hard and non-mobile and on x-ray it appears as an expansile lytic lesion with thinned out cortex. Our patient had all these characteristic features. The lytic lesions of foot often have overlapping clinical features, and thus making the diagnosis a tough task. Therefore, a high index of suspicion is needed while evaluating any tumor of the foot because compact structure of the foot may delay diagnosis[5]. A GCT needs to be differentiated from other lytic lesions, such as tuberculosis, giant-cell reparative granuloma, aneurysmal bone cyst, Brown tumor of hyperparathyroidism. Clinical presentation (age, duration of symptoms) and imaging studies (site of lesion, extent of the tumor into surrounding soft tissue, expansile nature, absence of periosteal reaction and mineralized matrix) help in differentiating GCT from other lesions. Absence of fever, weight loss, anorexia and no response to anti-tubercular treatment helps in excluding tuberculosis. Aneurysmal bone cyst (ABC) is mostly seen in the second decade of life and presents as a firm, slowly enlarging mass[6]. Giant cell reparative granuloma is an uncommon, benign, intraosseous reactive lesion, usually located in meta-tarsal, where radiological and histological features may mimic GCT[7]. Radiographically, it appears as an expansile lytic lesion with thinned out cortex and cortical margins remain intact in majority of cases, unless a pathological fracture occurs. Brown tumor seen in patients of primary hyperparathyroidism, typically involves the diaphysis of long bones. The radiographic and histological features of Brown tumor, GCT, ABC and giant cell reparative granuloma are often indistinguishable. However, according to recent studies, Brown tumors have a much more lobulated architectural growth pattern as compared to GCT and giant cell reparative granuloma[8]. Hyperparathyroidism can be ruled out on the basis of normal serum calcium, phosphorus, and parathyroid hormone levels. Final diagnosis of these conditions is often made on cytopathology and histo-pathology. Wahane et.al. in their study of 122 cases, found cases found FNAC to be accurate up to the extent of 90.5% . FNAC obviated the need for biopsy in 63.8% cases and the therapeutic decision were made according to cytological findings[9].The diagnosis in our patient was based upon FNAC. Histo-pathological examination is the gold standard for final diagnosis of GCT.

Treatment modalities for GCT of the foot comprise curettage, curettage and bone grafting, irradiation, amputation, and resection with reconstruction[4,5]. We carried out en-block local resection of the affected metatarsal with ipsilateral free fibular graft.

Wold LE et.al in their study of GCT of small bones found that giant cell tumors of the small bones have a greater propensity for local recurrence than those of the long bones. These tumors are commonly multifocal, and are associated with higher risks for local recurrence and pulmonary metastasis[10]. Song et.al. also found the GCT involving small bones of the foot to be more aggressive with extensive destruction and high recurrence rate. Oliveira et.al. in their systematic review of literature on GCT of small bones in 2013 assessed the recurrence rate of these tumors after surgery. They found the recurrence rate of 72% (18 of 25) in those treated with isolated curettage, 13% (2 of 15) in those treated with curettage plus adjuvants, 15% (6 of 41) in those treated by resection and 10% (1 of 10) in those treated by amputation[11]. Our patient had recurrence after about six months of en-block tumor resection and autologous fibular graft of the defect. The above ankle amputation was performed in our patient as the limb was non- salvageable. Three years follow up after second surgery is uneventful. Long term follow up of patients with GCT of small bones is recommended due to high recurrence rate[10-11].

Conclusion

This case is being reported to emphasize the fact that although the foot is a rare site for GCT, the possibility should always be kept in mind. Early diagnosis is difficult because of the rarity of the lesion in this location and overlap in clinical presentations. Radiographic findings in all the expansile lytic lesions should essentially be supplemented with FNAC for establishing the diagnosis. The patients must be kept on regular follow-up as the recurrence rate is high in these GCT of small bones.

Conflict of Interest: None

Disclosure of Grants and Funding: The study is from department of Orthopedics Safdarjung Hospital, New Delhi (India) and from Dr. B.S. A. Hospital and Medical College, New Delhi (India). Both are government owned institutions and all services are provided free of cost to the patients. Informed consents for all interventional procedures including anesthesia, were taken as per standard protocol followed in the government hospitals.

REFERENCES:

1. Unni KK. Giant cell tumor. In: Unni KK, Ed. Dahlin's bone tumours: General aspects and data on 11,087 cases. 5th ed. Philadelphia, PA: Lippincott-Raven; 1996. pp. 263–83.
2. Song KS, Park CH. Giant Cell Tumor of the Talus: 19-Year Follow-Up of a Patient. J Foot Ankle Surg. 2015 Sep-Oct; 54(5):958-61.
3. Cavender RK, Sale WG 3rd. Giant cell tumor of the small bones of the hands and feet: metatarsal giant cell tumor. W V Med J. 1992 Aug; 88(8):342-5.
4. Michiro Yanagisawa, Kyoji Okada, Takahiro Tajino, Tomoaki Torigoe, Akira Kawai and Jun Nishida. A clinicopathological study of giant cell tumor of small bones: Ups J Med Sci. 2011 Nov; 116(4): 265–268.
5. Bos GD, Esther RJ, Woll TS. Foot tumors: Diagnosis and treatment. J Am Acad Orthop Surg 2002; 10:259-70.
6. Hsu CS, Hentz VR, Yao J. Tumours of the hand. Lancet Oncol 2007; 8:157-66.
7. Ratner V, Dorfman HD. Giant-cell reparative granuloma of the hand and foot bones. Clin Orthop Relat Res 1990; 260:251-8.
8. Rosenberg AE, Nielsen GP. Giant cell containing lesions of bone and their differential diagnosis. Curr Diagn Pathol 2001; 7:235-46.
9. Wahane R.N, Lele V.R, Bobhate S.K. Fine Needle Aspiration Cytology of Bone Tumors; Acta Cytologica 2007;51;711-720
10. Wold LE, Swee RG. Giant cell tumor of the small bones of the hands and feet : Semin Diagn Pathol. 1984 Aug;1(3):173-84.
11. V. C. Oliveira, L. van der Heijden, I. C. M. van der Geest, D. A. Campanacci, C. L. M. H. Gibbons, M. A. J. van de Sande, P. D. S. Dijkstra . Giant cell tumors of the small bones of the hands and feet Long Term Results of 30 Patients and a Systamatic Literature Review: The Bones and Joint Journal 2013;95-B:838–45