VOLUME-6 | ISSUE-2 | FEBRUARY-2017 • ISSN No 2277 - 8179 | IF : 3.508 | IC Value : 78.46

Giant Condyloma Acuminatum of Vulva- A Case Report.

Pathology

KEYWORDS: - condyloma , vulva , Human papiloma virus.

DR.BHARTI DEVI THAKER — SENIOR RESIDENT, DEPATMENT OF PATHOLOGY GMC JAMMU.

DR.SUBHASH BHARDWAJ — ASSOCIATE PROFESSOR ,DEPARTMENT OF PATHOLOGY GMC JAMMU.

ABSTRACT

Since Buschke and Lowenstein first described the giant condyloma in 1925(which subsequently was named as Buschke - Lowenstein tumour),there have been scatterd reports over the past 90 years describing presentation and different avenues of the treatment for patients with this condition. Anogenital warts (condyloma acuminatum or veneral warts) are a common sexually transmitted disease among females and males . The causal role of Human papiloma virus(HPV) in anogenital wart formation has been firmly established biologically and epidemiologically. The mode of treatment range from application of podophyllin to surgical excision . We present a case of 32 years old married female with a presentation of giant condyloma acuminata whose surgically excised specimen was received in our laboratory.'

Introduction

Anogenital warts (condyloma acuminatum or veneral warts) are a common sexually transmitted disease among females and males (1); The causal role of Human papiloma virus(HPV) in anogenital wart formation has been firmly established biologically and epidemiologically. Genital HPV infections are primarily transmitted through sexual contact, with a lifetime risk of 50-80% and highest rate of transmission identified in adults between 18 and 28 years of age (2,3). Giant condyloma acuminatum (GCA;Buséhke Lowenstein tumour) is an extremely rare clinical form of genital warts, characterized by large size with a propensity to ulcerate and aggressive down growth into underlying dermal structures(4,5) with a microscopically benign pattern . The estimated incidence is 0.1% in the general population with a ratio of 3:1 between men and women(6). The most common location is glans penis and foreskin but they may occur on the vulva and in the anal region .The lesion of Condyloma acuminate are usually diagnosed clinically based on their warty appearance with resemblance to a large aggregate of condyloma acuminata especially in its early stage. The hallmark of the disease is high rate of recurrence (66%) and of malignant transformation(56%)(7). The mode of treatment range from application of podophyllin to surgical excision. We present a case of 32 years old married female with a presentation of giant condyloma acuminata whose surgically excised specimen was received in our laboratory.

Case report

A specimen of vulvectomy was received in pathology laboratory. Patient was a 32 year old multiparous female, with 18 months long history of progressive vulval swelling associated with itching, contact bleeding and malodorous vaginal discharge. The swelling was so huge that she had difficulty in walking. Grossly the specimen was huge, measuring (15x12x3 cm), cauliflower like, partially covered with vulval skin. Histopathological examination shows a papillomatous growth characterized predominantly by epithelial hyperplasia, irregular acanthosis and hyperkeratosis with few vacuolated keratinocytes. Epidermis showed tremendous proliferation with displacement of underlying tissue, but with low nucleocytoplasmic ratio. The invasive strands of the tumour possessed a well developed basal cell layer.

Discussion

Giant Condyloma Acuminata was first described by Buschke and Lowenstein in 1925(8).This condition is described as large exophytic cauliflower lesion affecting the anogenital mucosal surface and is caused by human papilloma virus(HPV).It has a benign appearance and rarely metastasizes. Several studies have shown that condyloma acuminate expands by expansion rather than by infiltration. They are mostly associated with infection by low risk HPV 6 and 11(2). Often the giant condyloma have a rich blood supply and mild trauma on the surface may lead to severe bleeding that may be unresponsive to routine methods of acheiving haemostasis such as pressure, ligation or electric coagulation. These usually are not seen nowadays in developed nations but such cases are still common in underresourced countries.This is because most patients donot present early for treatment to the hospital. Our patient also presented with a huge swelling that she was unable to walk properly. Condyloma acuminata can be treated with medical therapy or surgical intervention. Medical therapy with podophyllin salts. Imiquimod, sinecatechins and Five flourouracil all have been used with varied results. Size of the growth is the major impediment to medical treatment. Surgical excision in the form of simple excision with a surgical margin of 1.5cm with either scalpel or laser is considered optimal treatment for giant condylomas. Other surgical options are carbon dioxide laser therapy, electro surgery and cryotherapy(9). Our patient had undergone simple vulvectomy and was discharged 10 days after the treatment. The case reported here is a rare entity and will help to increase awareness about this entity so that proper counseling of the patient is done. and they present to the hospital early for optimal treatment.



Gross Photograph of Lowenstein Buschke Tumour showing a multilobulated lesion.

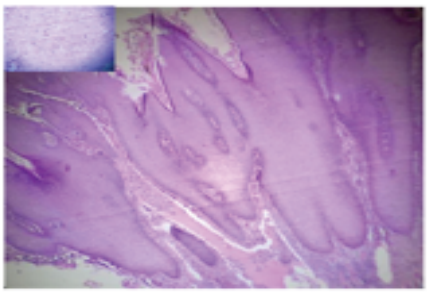

Photomicrograph of the above showing maked hyperkeratosis, irregular acanthosis and papillomatosis of epidermis. Marked koilocytic change also seen (inset) H&E (40x)

References:

1. Brentjens MH, Yeung-Yue KA, Lee PC, Tyring SK. Human papilomavirus: a review. Derrnatol Clin.2002:20:315- 31.(pubmed).
2. Koutsky L. Epidemiology of genital human papiloma virus infection.Am J Med.1997:102:3—8(pubmed).
3. Mac C, Hughes JP. Kiviat N Kuypers J, Lee SK, Adam DE, Koutsky LA. Clinical findings among young women with genital human papiloma virus infection. Am J Obstet Gynaecol.2003:188:677-84(pubmed).
4. Frei W. About carcinoma similar pointed condyloma on the penis. Arch Derm Syph. 1930;160:109-14.
5. Von Krogh G,Lacey CJ, Gross G, Barrasso R, Schneider A. European course on HPV associated pathology:guidelines for primary care physicians for the diagnosis and management of anogenital warts. Sex Transm Infect. 2007;76:162-8(pubmed).
6. Yemen l, Bozdag A.D, Derici H,Tansug T And Reyhan E.Verrucous carcinoma arising in a giant condyloma acuminate: twn year follow up. Annals of the academy of medicine Singapore,2011 Vol.40,no.2.pp'lO4-105
7. Levers Histopathology of the skin , 10m edition , page 656.
8. Buschke A and Loweenstein L. Uber die Bezeihungen von spitzen kondylomen zu kazenomen des oenis Dtsch. Med Wochenschr 1932;58:809-810.9. Yakasaki lA. Abubakar lS. Ibrahim SA. Ayyuba R. Unusual presentation of giant condyloma acuminate of the vulva-A wse report and review of the literature.Ann Trop Med Public Health.2012;5(5):508-10.