ORIGINAL RESEARCH PAPER
VOLUME-6 | ISSUE-6 | JUNE-2017 | ISSN No 2277 - 8179 | IF : 4.176 | IC Value : 78.46
INTERNATIONAL JOURNAL OF SCIENTIFIC RESEARCH

Giant mature cystic teratoma mimicking Term Pregnancy

Gynaecology

Dr. AbhipsaMishra (Assist Professor), Obstetric and Gynecology Department Kims Hospital Bhubaneswar Odisha India

Dr. Sudarshan Dash (Assist Professor), Obstetric and Gynecology Department Kims Hospital Bhubaneswar Odisha India

Dr S K Rath (Professor), Obstetric and Gynecology Department Kims Hospital Bhubaneswar Odisha India

ABSTRACT

Introduction: Mature cystic teratoma (Dermoid cyst) are the most common benign ovarian tumor associated with pregnancy. They are usually found in second trimester incidentally on ultrasound or present as acute abdomen due to torsion. They are usually unilateral but 10% cases can be bilateral. Giant size occupying whole abdomen mimicking a term size gestation with minimal symptom in second trimester is rare .
Case Report:A 21 year primigravida with 13 week gestation presented with mild abdominal discomfort and swelling, found out to be a giant Cystic teratoma on CTscan. Exploratory Laparotomy was done with complete removal of the mass without spillage. On Histopathology it was confirmed as Mature cystic teratoma. Patient was followed up till term and delivered a healthy fetus by Cesarean section due to fetal indication.
Conclusion: Early detection and intervention of ovarian mass leads to successful pregnancy outcome.

KEYWORDS:

Mature cystic teratoma, pregnancCorresponding Author:

Introduction: Adnexal mass in pregnancy is rare in occurrence. Most of the adnexal masess are ovarian in origin. Most common ovarian tumor associated with pregnancy is Mature cystic teratoma(Dermoid cyst).These are the most common type of primordial germ cell ovarian tumors are usually benign . They are present in 0.3% of pregnancies and usually present between16-20weeksofgestation.(1,2) They are usually present unilaterally but 10%cases are bilateral. Most of the cases are aymptomatic detected incidentally or presented as torsion. Gaint size dermoid cyst presented with early pregnancy mimicking full term gestation is a rare entity as in our case.

Case Report : A 21 yr old primi gravida with 13 wk of gestation came with complaint of mild discomfort in abdomen and swelling of abdomen since 4 days .She was an unbooked case.Her previous menstrual cycles were regular .Her LMP was 29/5/2016 and EDD : 1/3/2017 . She was married since 1 year and spontaneously conceived. There was no significant past history and family history.

On General examination, her weight was 70kg with Height 160cm.Her vitals were stable with mild bilateral pedal edema.

On per abdominal examination, Abomen was over distended.(Fig.1) There was a 36 week size firm immobile mass felt , non tender .Uterus size could not be appreciated .

On P/V examination : Cervix was closed and posterior.
On investigation, her routine blood parameters were within normal limits.

On ultrasound examination, there was a single live intrauterine gestation of 13 week 3 days with nuchal translucency of 1.1cm. There was a heterogenous huge complex right adnexal SOL of size 17.2 x 15.3 x 18.3 cm with solid and cystic components and calcification with internal septum . Minimal free fluids was seen in the peritoneal cavity . Upper abdomen ultrasound was normal.

On MRI examination : A solid cystic lesion of size 20 x 20 x 13 cm arising from right adnexa extending upto the peri pancreatic region . The lesion was causing peripheral displacement of bowel loops . Solid part of the lesion was heterogeneously hypointense in both T1 & T2.Cystic foci which was hyperintense in T2 and hypointense in T1 noted within the solid component. Peripheral cystic components were hypointense in T1 and hyperintense in T2. Few T1 and T2 hypointense septae were noted in the cystic component of (having width maximum 2-3 mm) solid part of the lesion show blooming in GRE, calcification. No definite diffusion , restriction foci seen in the solid part of the lesion. Low resistance high velocity flow in the solid part of the lesion. No evidence of retroperitoneal lymph nodes seen . No evidence of any distant metastasis. MRI was suggestive of malignant right ovarian mass.(Fig2)

Her serum CA125, CEA ,CA19.9 ,Serum alphafetoprotein, Beta HCG were within normal limits. .Her LFT and RFT was within normal limits.

Due to the giant size of ovarian mass decision for exploratory laparotomy was taken. Preoperative injectable progesterone was given.

She underwent exploratory laparotomy under spinal anaesthesia .Vertical midline incision was given . On opening the abdomen an encapsulated left ovarian mass of size 20x20x18 cm huge solid cystic mass was seen covering the whole abdomen .(Fig3)Moderate ascites of approx., 200ml clear fluid was found. No deposit in the peritoneal cavity was seen . Right ovary and tubes were normal. Uterus was 12-14 week size. Excision of left adnexal mass was done . On cut section of the mass multiple bossilated appearance found , cheesy structures, fetal skin like appearance, hair, gelatinous fluid seen.(Fig4) On frozen section, teratoma with mixed component was found. Omentectomy with bilateral pelvic peritoneal biopsy with ascitic fluid analysis was done
Post op recovery was good.

On Histopathological examination, benign cystic teratoma was found . Omentum , right fallopian tube , right and left pelvic peritoneum was within normal limits. Ascitic fluid analysis showed no malignant cells. Patient discharged on 15th post op day.

She followed up with us with regular antenatal checkup and delivered a healthy child by Cesarean section. She was discharged on 7th post op day uneventfully.

Discussion: Occurrence of adnexal mass in pregnancy is 4% .(3) Majority of adnexal masses are ovarian origin. Dermoid cyst and mucinous cyst are the most common ovarian mass in pregnancy. They are found constituting 60% of total adnexal mass during pregnanc . Incidence of complex or simple persistent cyst more than 6 cm is still rare ,only 0.07% .(4) The incidence of Dermoid cyst with pregnancy is approximately 37 %. It occurs in young women (20–30 years of age) in approximately 80% of the cases. Teratomas are derived from germ

cells and may contain structures from all three embryonic germ layers Most of them are benign and usually disappear by the 16 week of gestation. Most of them are benign in nature but can be malignant in 5% cases.(5) Most of them are asymptomatic and found incidentally during an ultrasound examination. Though they can presente as acute abdomen due to torsion in 15% cases . Dermoid cyst rarely grows more than 10 cm. Aymptomatic gaint dermoid cyst in early pregnancy is a rare entity as in our case ,she mimicked a full term gestation abdomen.

Detection of ovarian mass is usually done by ultrasound if the size is small .When the mass is very huge ,thought to be malignant and the origin is doubtful , MRI gives a clear picture and helps in further management. Though in our case MRI showed features of malignant ovarian mass. During pregnancy, tumor markers are not reliable to assess the risk of malignancy of ovarian masses .(6) During pregnancy, however, serum AFP, beta hCG and inhibin levels are all raised due to placental synthesis and thus the use of these markers in evaluating suspicious ovarian cysts is limited. due to increased pelvic vascularity in pregnancy, the degree of overlap of these indices in both benign and malignant lesions makes Doppler imaging unreliable in this setting.(7) Conservative management for small size asymptomatic dermoid cyst with regular follow up though there are many controversies regarding the management. Surgery is done for symptomatic small sized ovarian mass and giant size ovarian mass where suspicion of malignancy is there as in our case. Laparoscopic cystectomy is done in small sized mass preferably in second trimester. Laparotomy is the procedure of choice for such a giant dermoid cyst at second trimester. Complete removal of the mass, reduction of the risk of recurrence, prevention of the risk of tumor dissemination and preservationof healthy ovarian tissue should considered during the surgery of benign ovarian tumor.(8) The risk of miscarriage following surgery for ovarian tumor during pregnancy is estimated 2.8% .

Conclusion:Early booking of pregnant patient with through clinical examination with early ultrasound is very important in detecting Ovarian mass in pregnancy. Giant sized ovarian mass needs complete removal with minimal spillage by laparotomy. Early diagnosis ,timely interventation is the key to the successful fetomaternal outcome.



Figure 1-Preoperative view of abdomen

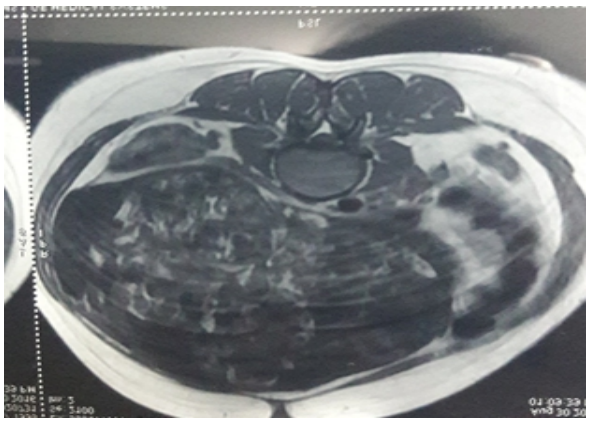

Figure 2 -MRI Showing the Mass

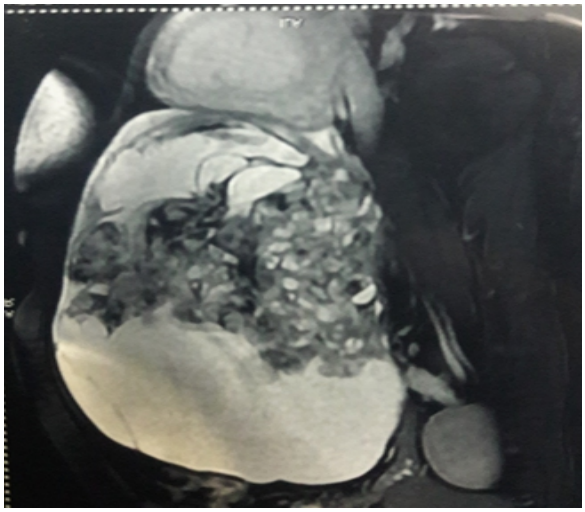

Figure 2.MRI Showing the Mass (side view)



Figure 3-Intra operative picture of Mass taken out in toto



Figure3- Intra operative picture of Mass taken out in toto



Figure 4-Inner surface of mass showing of caseating structures,hair.

Reference.

1. . . De Santis M, Licameli A, Spagnuolo T, Scambia G. Laparoscopic managementof alarge,twisted,ovariandermoidcystduringpregnancy: acasereport.JReprodMed. 2013;58(5-6):271–6
2. . . Attia L, Chachia A, Ben Temime R, Bennour G, Makhlouf T, Koubaa A. [Benignovariantumorsduringpregnancy.Areviewof26cases].Tunis Med. 2008;86(7):680–4.
3. . . Whitecar MP, Turner S, Higby MK. Adnexal masses in pregnancy: a review of 130 cases undergoing surgical management. Am J Obstet Gynecol 1999;181:19–24.
4. . . Nelson MJ, Cavalieri R, Graham D, Sanders RC. Cysts in pregnancy discovered by sonography. J Clin Ultrasound 1986;14:509–12.
5. . . Boulay R, Podczaski E. Ovarian cancer complicating pregnancy. Obstet Gynaecol Clin North Am 1998; 25:385-97.
6. . . Tariel O, Huissoud C, Rudigoz RC, Dubernard G. [Presumed benign ovarian tumors during pregnancy]. J Gynecol Obstet Biol Reprod (Paris). 2013;42(8):842–55.
7. . . Wheeler TC, Fleischer AC. Complex adnexal mass in pregnancy: predictive value of color Doppler sonography. J Ultrasound Med 1997;16:425–8.
8. . . Borghese B, Marzouk P, Santulli P, de Ziegler D, Chapron C. [Surgicaltreatmentsof presumedbenignovariantumors].JGynecolObstet Biol Reprod (Paris). 2013;42(8):786–93.