Research Paper

Volume : 2 | Issue : 10 | October 2013 • ISSN No 2277 - 8179

Growth Hormone Deficiency in Patient Suffering from Tuberculous (Tb) Meningitis

Medical Science

KEYWORDS :

Dr. Tejas Patel	Department of medicine, NHL medical college, Ahmedabad.
Dr. Priyesh Damani	Department of medicine, NHL medical college, Ahmedabad.
Dr.Mukund Pithiya	Department of medicine, NHL medical college, Ahmedabad.

ABSTRACT

Here we report a case of 30 year old male with previous history of seizure and altered sensorium 16 years back for which he was diagnosed as having tuberculous meningitis and not taken complete course of treatment. After this incidence his growth was persistently retarded. At this time patient presented with relapse of miliary TB complicated by TB meningitis and treated with AKT, steroids and growth hormone replacement.

Case presentation
History & examination
A 30 yr old male patient admitted with Fever with weight loss 20 days Altered sensorium 14 days.

Past history of similar episode 16 year back for which he was diagnosed as having tuberculous meningitis and not taken complete course of treatment. Despite of that his growth was persistently retarded. He is working as a laborer.

He was stupors with moving all four limbs on DPS. Planter B/l extensor. NR++. Tone was increased in all four limbs with brisk deep tendon reflexes in all limbs. Pupil was 6mm diameter sluggishly reacting to light.

His height was 125 cms and weight 32 kgs. Height of parents and siblings were normal. Mid –parental height was 164.25 cms.

Penile and testicular size was normal and sparse hair growth in axillary, pubic and facial area. Central obesity was there.

Investigations
Hb 8.96 gm/dl **WBC-** 9500/mm^3 **Apc** 3.66 lacs/mm^3

Creatinine 0.70 mg/dl, **BUN** 18 mg/dl **Na^+/K^+** 130/3.5 mleq/dl **SGPT** 10 **RBS** 114 mg/dl

ESR- 60 mm/hr (high)

CSF-:
Protein 57 mg/dl

Sugar 30mg/dl

Cells 80/mcl with 100% lymphocytes

CSF ADA (Adenosine Deaminase) 27.6I IU/L [high]

TSH- 2.1 micro IU/ml [normal].

FT3- 3.1 pg/ml [normal]

FT4- 1.0 ng/ml [normal]

GH- basal 0.07 microgram/lit[low]

After CST (Clonidine Stimulation Test) < 3 mcg/lit [low]

Plasma cortisol level- (fasting) 10 mcg/dl [Normal]

ABGA: PH 7.47, Pco_2 25.8, Po_2 113.7 Hco3 18.6, O_2 sat. 98.7%

HIV- Non reactive

HCV- Non reactive

HbsAg - Non reactive

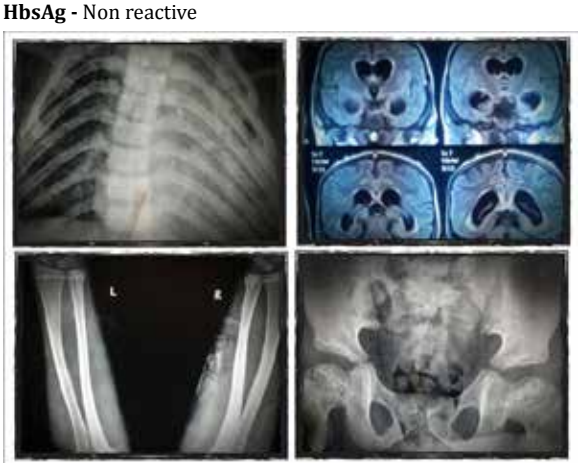

ECG NSRWNL
Chest X-Ray milliary mottling b/l lung fields with crowding of ribs X rays elbow wrist and pelvis shows non union of epiphysis suggestive of bone age < 16 years USG abdomen and thyroid local part was normal.

MRI brain P+C showing abnormal leptomeningeal enhancement along basal cistern s/o meningitis with Mild to moderate hydrocephalous. Pituitary gland shrunken in size.

Management
Pt was admitted in ICU with O_2 support. Pt was treated with I.V.fluids along with AKT Cat1 and dexamethasone and injectable GH (0.1 to 1.25 mg s.c./day). Pt gradually improved in form of gaining consciousness taking orally and on 14th day shifted to general ward.

DISCUSSION
TB of the central nervous system accounts for 5% of extrapulmonary cases.[1] It is seen most often in young children but also develops in adults, especially those infected with HIV.[2] Tuberculous meningitis results from the hematogenous spread of primary or post-primary pulmonary TB or from the rupture of a subependymal tubercle into the subarachnoid space. In more than half of cases, evidence of old pulmonary lesions or a miliary pattern is found on chest radiography. If not recognized, tuberculous meningitis may evolve acutely with severe headache, confusion, lethargy, altered sensorium, and neck rigidity. Typically, the disease evolves over 1–2 weeks, a course longer than that of bacterial meningitis. The ultimate evolution is toward coma, with hydrocephalus and intracranial hypertension.[3] Among neurological complications 10 out of 49 and 7 out of 49 patient were found having pan- hypopituitarism and growth hormone deficiency respectively.[4] Among those with growth hormone deficiency, a significant correlation($r=0.749$, $p<0.05$) was found between height SD score and age at diagnosis of TB meningitis.[5]

REFERENCE

1. Rieder HL, Snider DE Jr, Cauthen GM. Extrapulmonary tuberculosis in the United States. Am. Rev. Respir. Dis. 1990 Feb;141(2):347–51. | 2. Gray JM, Cohn DL. Tuberculosis and HIV Coinfection. Semin Respir Crit Care Med. 2013 Feb;34(1):32–43. | 3. Longo D, Fauci A, Kasper D, Hauser S, Jameson J, Loscalzo J, editors. Harrison's Principles of Internal Medicine. 18th ed. New York: McGraw-Hill Professional; 2011. | 4. Anderson NE, Somaratne J, Mason DF, Holland D, Thomas MG. Neurological and systemic complications of tuberculous meningitis and its treatment at Auckland City Hospital, New Zealand. J Clin Neurosci. 2010 Sep;17(9):1114–8. | 5. Lam KS, Sham MM, Tam SC, Ng MM, Ma HT. Hypopituitarism after tuberculous meningitis in childhood. Ann. Intern. Med. 1993 May 1;118(9):701–6.