Volume : 2 | Issue : 7 | July 2013 • ISSN No 2277 - 8179

Research Paper

Histopathological Changes in the Intestine of Indian Flying Barb (*Esomus danricus*) Exposed to Organochlorine Pesticide, Endosulfan (EC 35)

Environment

KEYWORDS : Teleost, chronic, organochlorine, inflammation, villi

Suchismita Das — Department of Life science and Bioinformatics, Assam University, Silchar, India

Abhik Gupta — Department of Ecology and Environmental Science, Assam University, Silchar, India

ABSTRACT

Indian flying barb (Esomus danricus) was exposed to sublethal concentrations of endosulfan (EC 35) for 28 days and intestinal histopathology was observed by light microscopy after staining with Haematoxylin-Eosine. In the exposed fishes, superficial erosion of mucosa, dense lamina propria, chronic inflammatory cell infiltration, vacuolation and haemorrhage of mucosa and submucosa were observed. Higher doses had severe effects.

INTRODUCTION

Endosulfan is a toxic organochlorine insecticide that is used to control insect pest of cereals, coffee, cotton, fruit, oilseeds, potato, tea, vegetables (Ghadiri, Rose & Connel 1995). It is also used as a wood preservative. The World Health Organisation (WHO) classifies endosulfan in Category II (moderately hazardous), while the US Environmental Protection Agency (US EPA) classifies it as a Category 1b (highly hazardous) pesticide (PANAP 1996). Although banned or restricted for use in many countries, endosulfan is still used in many developing countries (Shanahan 2003). The Indian flying barb, *Esomus danricus* (Hamilton-Buchanan) inhabits shallow water bodies of Northern India and is a cyprinid that is economically important both as an ornamental and food fish. This fish runs the risk of ending up as the non target victims of such pesticides that are being sprayed in agricultural crops. Histopathology provides a rapid method to detect the effects of such irritants in various organs (Johnson et al. 1993). Regarding the insecticide induced physiological disorders in the organisms, very little is known about the effects on the fish intestine which is believed to be the first organ that come into contact with food-borne contaminants (Braunbeck & Appelbaum 1999). Also, the intestine is one of the most important sites where toxicants enter the food chain and are absorbed together with food from the intestine (Hinton & Lauren 1990). Intestine plays a vital role in digestion and absorption of food and any interference by toxic substances may cause direct or indirect effect on the vitality of the organism. When fish habitat is exposed to toxic chemicals, its food also gets contaminated causing damage to the intestine. Therefore intestine can serve as a potent biomarker for assessing endosulfan toxicity in fish. The present study was thus, aimed to determine the histopathological effects of sublethal concentrations of endosulfan to Indian flying barb intestine after 28 days of exposure.

MATERIALS AND METHODS

Fishes of similar length (46.77 ± 4.30 mm) and weight (0.86 ± 0.16 g) were collected from unpolluted, freshwater ponds near Assam University campus, Barak valley, South Assam, India (Das & Gupta 2009). They were acclimatized under laboratory conditions seven days prior to experimentation. Temperature, pH, hardness and dissolved oxygen under laboratory condition were 29°C, 6.8, 30 mg l^{-1} and 5.5 mg l^{-1} respectively. A stock solution of commercial grade endosulfan (6,7,8,9,10,10-hexachloro-1,5,5a,6,9,9a-hexahydro-6,9-methano-2,3,4-benzodioxathiepin-3-oxide; Thiodan- endosulfan 35% EC, Bayer Crop Science, India) was prepared using double distilled water. Serial dilutions of stock solutions were prepared using tap water as per dilution techniques (APHA 2005). Static-with-renewal acute toxicity tests were conducted with ten fish in each graded concentration and 96 hours LC_{50} value was found to be 4.9 μgl^{-1} in a prior study. Three sub-lethal test concentrations *viz*., 0.49, 0.049 and 0.0049 μgl^{-1} were selected for inducing histological changes in fish liver. Ten fish for each concentration of test chemical were kept separately in three litres of toxicant treated media for 28 days. Food was given during the study period. Test water was renewed every 24 hrs. After 28 days of exposure, fish were sacrificed and intestine was removed immediately and kept in 10% Formalin, as fixative, for 24 h, dehydrated, embedded in paraffin and sections cut at 5 µm thickness and stained with Harris Haematoxylin and Eosin. Changes induced by treatment in the intestinal tissues were photographed and analyzed by light microscope at 10X eye piece magnification and 40X objective magnification {Olympus (model U-CMAD3) with Camera attachment of Samsung (model SDC-313B)}.

RESULTS AND DISCUSSION

The intestine of *Esomus danricus* shows four layers of tissues namely serosa, muscularis, submucosa and mucosa. The outermost serosa is followed by a well developed muscularis (longitudinal and circular muscle) embedded in loose connective tissue richly supplied with blood capillaries. It merges with tunica propria of the underlying mucosal coat. The mucosa is raised into several longitudinal folds (Fig.1). In 0.49µg l^{-1} endosulfan administered intestine, after 28 days of exposure shows breakage of microvilli, lymphocyte infiltration, vacuolation and haemorrhage (Fig. 2). In 0.049 µg l^{-1} of endosulfan exposed intestine, atrophy of epithelial cells, infiltration of lymphocytes and vacuolation could be observed (Fig. 3). Further, 0.0049 μgl^{-1} of endosulfan administered intestine of flying barb after 28 days of exposure, was almost normal with infiltration by a few lymphocytes (Fig. 4).

Fig 1: T.S of Control Intestine of *Esomus danricus*: (a) epithelium, (b) lamina propria, (c) muscularis, (d) serous membrane. H&E, 100×.

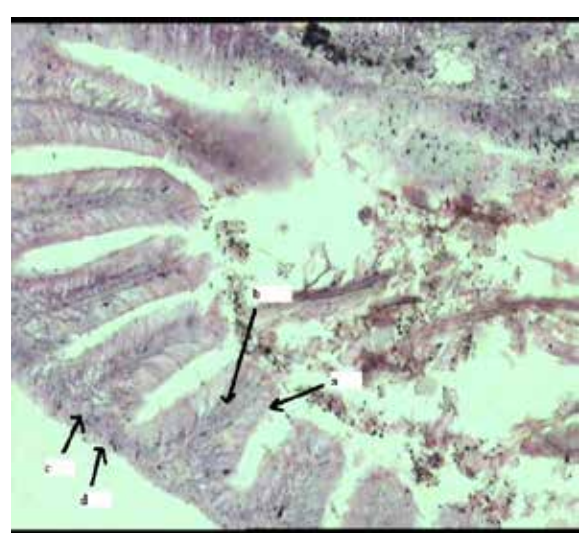

Volume : 2 | Issue : 7 | July 2013 • ISSN No 2277 - 8179

Fig. 2: T.S of Intestine of *Esomus danricus* **exposed to 0.49 µg l^{-1} Endosulfan: (a) breakage of microvilli, (b) lymphocyte infiltration, (c) vacuolation, (d) haemorrhage. H&E, 100×.**

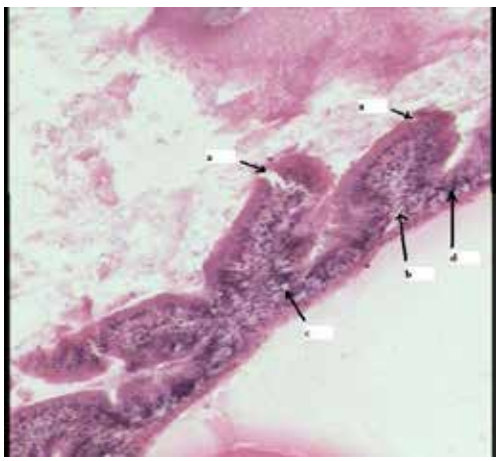

Fig 3: T.S of Intestine of *Esomus danricus* **exposed to 0.049 µg l^{-1} Endosulfan: (a) atrophy of epithelial cells, (b) infiltration of lymphocytes, (c) vacuolation. H&E, 100×.**



Fig. 4: T.S of Intestine of *Esomus danricus* **exposed to 0.0049 µg l^{-1} Endosulfan: (a)mild lymphocyte infiltration. H&E, 100×**

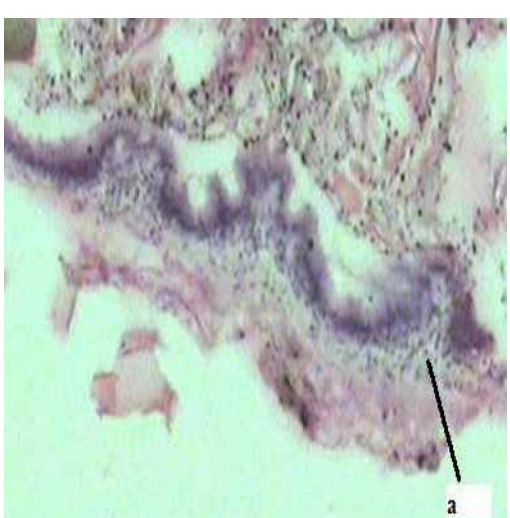

In the present study, the result of the effect of endosulfan on the gastrointestinal system of *Esomus danricus* clearly show that this pesticide exert toxic effects on the different layers of intestine. The alterations in the intestine of the flying barb were more severe in higher doses. Reactions like necrosis and degranulation of the cells of intestine, flattened, reduced in size, number and height of villi, degranulation in the absorptive cells, presence of large vacuoles in the submucosal region and detachment of tunica propria from columnar epithelium have been made by Mathur (1959) in *Ophiocephalus punctatus* on exposure to endosulfan. But in the present study, such changes could not be found. Rather, reactions like superficial erosion of mucosa, dense lamina propria and chronic inflammatory cell infiltration or transmural inflammation were observed in the toxicant exposed fish intestine. Braunbeck & Appelbaum (1999) have also found that in the intestine, exposure to endosulfan is associated with changes in the epithelial lining, which indicates disturbance of intestinal absorption. Cengiz, Unlu & Bale (2001) reported oedema, degeneration, accumulation of lymphocytes in the lamina propria, pycnotic state of nuclei and necrosis in the intestine of *Gambusia affinis* exposed to endosulfan. In *Channa punctatus* exposed to endosulfan, degenerative changes like fused microvilli, broken outer membrane of microvilli, haemorrhage in the sub mucosa region, swelled cells and vacuoles were recorded (Haloi, Kalita & Nath 2013). In another study, destruction of mucosa and particularly of columnar epithelial cells, granular degeneration, vacuolization and necrosis in intestine of *Rasbora daniconius* exposed acutely and chronically to endosulfan were found (Ghanbahadur & Ghanbahadur 2012). The present study also found profuse infiltration of lamina propria with lymphocytes, which is a mark of inflammation. According to Velmurugan et al. (2007), the changes observed in the different intestinal layers of the studied fish may be due to a direct effect of pesticides. The intestine of *Cyprinus carpio* exposed to chlorinated pesticides Aldrin, Dieldrin, BHC and DDT showed fusion of intestinal folds and acute epithelial necrosis (Satyanarayan, Satyanarayan & Verma 2012).The present results are in agreement with those observed by many investigators about the effects of organochlorine pesticides on fish intestine (Bakthavathsalam, Ramalingam & Ramaswamy 1984; Gad & Mohamed 2007; Ezemonye & Ogbomida 2010).

CONCLUSION

Thus, Indian flying barb intestine was adversely affected by endosulfan exposure which in turn might have impaired the growth rate of fishes. Hence, it is suggested that this pesticide in higher dosage will be lethal to fish population in general.

ACKNOWLEDGEMENT

We wish to thank Prof Arabinda Das, Principal Diphu Medical College, Assam for providing microscope facility.

REFERENCE

APHA (2005), Standard methods for the examination of water and wastewater, 21st Edn., Washington, DC: American Public Health Association, AWWA, WPCP. | Bakthavathsalam, R Ramalingam, R & Ramaswamy, A 1984, 'Histopathology of liver, kidney and intestine of the fish Anabas testudineus exposed to furadan,' Environ. Ecol., vol. 2, pp 243 - 247. | Braunbeck, T & Appelbaum, S 1999, 'Ultrastructural alterations in the liver and intestine of carp Cyprinus carpio induced orally by ultra-low doses of endosulfan,' Dis. Aquat. Organ, vol. 36, pp 183–200. | Cengiz, E Unlu, E & Bale, K 2001, 'The histopathological effects of thiodan on the liver and gut of mosquitofish, Gambmia affmis,' J. Environ. Sci. Health B. vol. 36, pp 75-85. | Das, S & Gupta, A 2009, 'Biometrics and growth features of Esomus danricus (Hamilton-Buchanan), from Barak Valley, South Assam,' J. Inland Fish. Soc. India, vol. 41, pp 81-83. | Ezemonye, L & Ogbomida, TE 2010, 'Histopathological Effects of Gammalin 20 on African Catfish (Clarias gariepinus),' Applied and Envtl. Soil Sci. doi:10.1155/2010/138019. | Gad, NS & Mohamed, FA 2007, 'Bioaccumulation and effects of organochlorine and pyrethroid pesticides residues on Oreockromis niloticus and Mugil cephaliis from some fish farms at El-Fayoum Governorate, Egypt,' Egypt. J Aquat. Biol. & Fish, vol.1, pp l21-148. | Ghadiri, H Rose, CW & Connel, DW 1995, 'Controlled environment study of the degradation of endosulfan in soils in Challenging the future,' in Constable, GA & Forrester, NW (eds.), Proceedings of the World Cotton Research Conference– 1, Brisbane, Australia, February 14-17, 1994, CSIRO, Melbourne, Australia, pp 583-588. | Ghanbahadur, A & Ghanbahadur, G 2012, 'Histopathological effect of organochloride endosulphan on intestine and stomach of larvivorous fish Rasbora daniconius,' DAV Intl.J. Sci., vol. 1, pp 126-127. | Haloi, K Kalita, M & Nath, R 2013, 'The study on the histopathological changes of stomach of Channa punctatus (Bloch) by used pesticide Endosulfan,' Glob. J. Sci. Frontier Res. Biol.Sci.,vol. 1, pp 1-6. | Hinton, DE & Lauren, DJ 1990, 'Integrative histopathological approaches to detecting effects of environmental stressors on fishes in Biological Indicators of Stress in Fish,' in Adams, SM (ed.), American Fisheries Symposium 8. American Fisheries Society, Bethesda, Maryland, pp 51–66. | Johnson, LL Stehr, CM Olson, OP Myers, MS Pierce, SM Wigren, CA McCain, BB & Varanasi, U 1993, 'Chemical contaminants and hepatic lesions in winter flounder (Pleuronectes americanus) from the Northeast Coast of the United States,' Environ Sci Technol., vol., 27, pp 2759-71. | Mathur, DS 1959, 'Toxicity on organic insecticides to certain fish', Proc. Nat. Acad. Sci. Ind., vol. 29, pp 380-382. | PANAP, (1996). Endosulfan datasheet. Pesticide Action Network – Asia and the Pacific, Penang, Malaysia. 6. | Satyanarayan, S Satyanarayan, JPKA & Verma, S 2012, 'Histopathological changes due to some chlorinated hydrocarbon pesticides in the tissues to cyprinus carpio', IOSR J. Pharmacy, vol., 2, pp 60-66. | Shanahan, M 2003, 'End of the Road for Endosulfan: A call for action against a dangerous pesticide. Environmental Justice Foundation Ltd. 4 p. | Velmurugan, B Selvanayagam, M Cengiz, EI & Unlu, E 2007, 'Histopathology of lambda-cyhalothrin on tissues (gill, kidney, liver and intestine) of Cirrhinus mrigala,' Envtl.Toxicol.Pharmacol., vol. 24, pp 286–291. |