Original Research Paper

VOLUME-6 | ISSUE-4 | APRIL - 2017 • ISSN No 2277 - 8179 | IF : 4.176 | IC Value : 78.46

Histopathological study of endoscopic gastro –esophageal biopsies in western India at a tertiary care centre.

Pathology

KEYWORDS: Upper GIT, Endoscopy, Biopsy, Histopathology

Preeti Rajeev Doshi

ABSTRACT

Background: The lesions of upper gastrointestinal tract are responsible for higher morbidity and mortality. Upper GI endoscopy in combination with biopsy plays an important role in the diagnosis of these lesions which aids in for further management.

Methods:A study was conducted on endoscopic biopsies of upper GI tract in a tertiary care hospital in Western Indian. The clinical details along with endoscopic findings were taken and correlated with histopathological findings.

Result: Stomach was the most frequent site of endoscopic biopsy (75%) followed by esophagus (25%). Majority of patients presented with dysphagia and abdominal pain. Mean age of presentation was 50 years. Esophageal malignancy was the commonest neoplastic lesion with squamous cell carcinoma being the dominant histological type. Interestingly, inflammatory conditions, chronic gastritis were more common in the stomach.

Conclusion: It was concluded that endoscopy is incomplete without biopsy and so the combination of methods provides a powerful diagnostic tool for better patient management.

INTRODUCTION

In the present era; gastroenterology is one of the most important and expanding branch of medicine. The era of modern endoscopy started in 1932 when a German instrument technician, Wolf with a Gastroenterologist, Rudolph Schindler, produced a safe, efficient, semi flexible endoscope.[1] The gastrointestinal flexible fibreoptic endoscope was first used in 1968 and proved to be a major breakthrough in the diagnosis of oesophago gastro duodenal lesions.[2]

Application and use of G-I endoscopy has continued to expand. Indeed a survey by the British society of gastroenterology showed that as many as 1% of the population undergo upper G-I endoscopy annually.[3]

Worldwide, gastric adenocarcinoma is the second most common cancer, and carcinoma esophagus is the sixth leading cause of death.[4,5] In India, according to the National Cancer Registry, esophageal and gastric cancers are the most common cancers found in men, while esophageal cancer ranks third among women after carcinoma of breast and cervix.[6]

Squamous cell carcinoma of esophagus is usually seen in the middle third of esophagus. Squamous cell carcinoma of the oesophagus occurs mainly through a sequence of chronic-esophagitis, with progressive dysplasia, carcinoma in situ, finally invasive carcinoma (Munoz et al. 1982).

In the stomach, the great concern is to pick the early gastric lesions on histopathology of the gastric mucosal biopsies (early gastric cancer) that does not extend beyond the mucosa or submucosa even though there may be lymph node metastasis in contrast to the invasive gastric carcinoma which extend beyond muscularis propia where the prognosis is poor.[7]

It has been confirmed that the development of gastric cancer spans several decades sequentially starting from the H. pylori infection, development of chronic active gastritis to development of glandular atrophy and intestinal metaplasia in a subset of patients.[8]

Endoscopy provides numerous small mucosal biopsies to diagnose and monitor the course of a variety of gastrointestinal tumours. It allows the biopsy under direct vision and correlation of histologic features in both early and advanced phases. In cases where the GI mucosa appears visually normal with endoscopy, the use of biopsy may still be beneficial in determining microscopic disease.[9,10]

Thus, the role of upper gastrointestinal mucosal biopsies for the histopathological identification of the earlier stages of various gastrointestinal tumours by endoscopy allows an early therapeutic decision without unnecessary delay.

MATERIALS AND METHOD

The patients attending the gastroenterology clinic who were clinically suspected with lesions in the upper gastrointestinal tract were subjected to endoscopic examination.

The initial suspicion of malignancy and other lesions was based on clinical history, which included the age, sex and presenting symptoms of the patients along with nonsteroidal anti-inflammatory drug (NSAID) or aspirin use or any other drugs like anticoagulants were taken. Biopsies obtained were oriented, fixed in 10% neutral formaldehyde and routinely processed. Approximately 5µm thick serial sections were cut and stained with hematoxylin and eosin (H&E). In addition, a special stain Giemsa was performed to confirm the presence of H. pylori.

For detection of H. pylori induced lesions, the surface epithelium and foveolar lumen were searched for curved bacilli in H&E. Giemsa stain was used to facilitate their recognition. Organisms were searched under oil immersion (100X).

RESULTS

Demographic characteristic and clinical presentation of the population under study

In this study, 100 patients of upper gastrointestinal symptoms were subjected to endoscopy and appropriate biopsy was obtained in a tertiary care centre. The duration of this study was for one year. There were 64 (64%) males and 36 (36%) females in this study and age range varied from 21 years to 70 years.

Majority of the patients either presented with dysphagia (75%) or abdominal or epigastric pain (37%). 52 % patients had non-specific symptoms such as nausea, vomiting, weight loss, hemetemesis, anaemia etc.

Spectrum of Lesions of the population under study:

Of all the 100 cases, majority of the biopsies were taken from stomach with a total of 75 (75%). This is followed by esophagus from where 25 (25%) tissue samples were taken as illustrated in figure 1. On histology assessment, the total number of esophageal lesion was 25 of which the maximum diagnosed cases found were malignant cases was 19 (76%) and 11 (15%) cases were gastric carcinoma (Table no 01 & 02). The gastric lesions were classified against modified Sydney classification (Table- 02) and showed that most of them have chronic non specific gastritis (51%) followed by adenocarcinoma (15%). A contrasting pattern was seen in esophageal cases where most of the lesions (76%) were malignant while rest were either inflammatory (4%), dysplastic (16%) as illustrated in Table-01. Of the esophageal carcinoma the most common malignancy was moderately

differentiated squamous cell carcinoma (68%) followed by well differentiated squamous cell carcinoma (21%) (Table no 03). Of the gastric carcinoma the most common malignancy was moderately differentiated adenocarcinoma (54%) followed by well differentiated adenocarcinoma (23%) (Table no 04).

Correlation of Endoscopic and histopathology findings of the population under study:

In this study, we have classified the lesion into inflammatory, malignant and others and have found that the endoscopic lesion, inflammatory and malignant were well correlated with histopathological lesions (Table no 5 and 6).

DISCUSSION

Current standard care for most patients with symptoms of upper GIT with suspicious lesions consists of initial endoscopic examination followed by histopathology. The individual accuracy and sensitivity of these techniques in the diagnosis of any lesions is subjective to the operator's ability to target site pathology. It is also equally important to look at common diseases that affect people in our part of the world in order to understand various risk factors involved in the pathogenesis of these conditions.

Most of the patients presenting with the symptoms were males and presented in the third to fifth decade of life. A similar male predominance was also observed by Shennak MM et al [10] which attributed to greater degree of male subjects to various risks factors and higher attendance to OPD than the females patients. Also predominance of age had similar trends as reported in other groups studies. [10, 11, 12] The patients with the symptoms of dysphagia or abdominal pain mostly had a lesion suspected in stomach followed by esophagus. Despite the fact that majority of lesions were suspected in stomach, most of these were identified as benign or inflammatory in nature. Chronic gastric (51 %) was the most common diagnosis. Similar findings were observed by Shennak MM et al. [10] The distribution of non-neoplastic lesions and malignant neoplasms correlated with similar findings made by Rupendra et al [13] in their study of 100 gastric biopsies. Thirteen cases of gastric malignancies were diagnosed on histopathology as gastric adenocarcinoma in line with other studies Parloor K et al.[14] in their study shows 56% of gastric malignancy. Eighteen cases of esophageal carcinoma were diagnosed as squamous cell carcinoma of esophagus and one case of adenocarcinoma esophagus with similar findings made by Uzma B et al. [15,16]

Finally, the two techniques for diagnosis of these lesions were compared. Our data suggested that in case of visible growth or malignancy, the two techniques correlated well with almost similar number of cases detected by each. However, histopathology significantly seen was improved diagnosis in inflammatory lesions and malignant lesions for their subtypes and grading. Thus the two techniques complement each other in the management of patients with the suspected upper GIT lesions.

CONCLUSION

This study shows a good correlation between endoscopic and histopathology diagnosis.

Biopsy sampling of upper gastrointestinal mucosa at diagnostic endoscopy provides useful information. A variety of non - neoplastic and neoplastic lesions were reported in the present study across a wide range of age and site distribution. In our study, the commonest site for upper endoscopic biopsy was from the stomach (75%) and common lesion of the stomach was chronic gastritis. The second commonest site was esophagus (25%) and commonest lesion was carcinoma esophagus. Limitations in diagnostic interpretation are encountered at times due to tiny biopsy material, handling and processing artifacts. However, multiple bits of endoscopic biopsies from abnormal looking mucosa are recommended to establish a definitive diagnosis.

Whenever there was a disagreement, the histopathological appearances served to correct a mistaken endoscopic finding. Endoscopic biopsies can detect changing patterns in the spectrum of lesions besides detecting upper GI mucosal lesions at an early stage especially atrophy intestinal metaplasia and dysplasia so as to prevent progress of these lesions to invasive cancer. We therefore conclude that endoscopy is incomplete without biopsy and so the combination of methods provides a powerful diagnostic tool for better patient management.

ACKNOWLEDGMENT

The authors are grateful to authors / editors / publishers of all those articles, journals and books from where the literature for this article has been reviewed and discussed.

FUNDING:

There is no source of funding.

COMPETING INTERESTS:

Nil

FIGURES

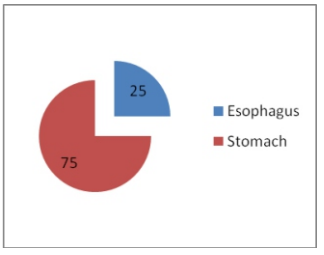

Figure 1: Upper GI biopsy Distribution site

Table No: 01

Frequency and percentage of types of histopathologic lesions in Esophagus

LESIONS	No of Cases (25)	Percentage (%)
Chronic Non Specific Esophagitis	1	4
Dysplasia	4	16
Squamous cell Carcinoma	18	72
Adenocarcinoma	1	4
Inadequate	1	4

Table No: 02

Frequency and percentage of types of histopathologic lesions in Stomach

LESIONS	No of Cases (75)	Percentage (%)
Chronic Non Specific Gastritis	38	51
Chronic Non Specific Gastritis with H Pylori	4	5
Acute Non Specific Gastritis	7	9
Gastric Polyp	4	5
Eosinophilic Gastritis	1	1
Dysplasia	2	3
Adeno Carcinoma	11	15
Inadequate	8	11

Table No: 03

Histopathological grading of esophageal carcinoma

Types of lesion	Grade	Type	No. of cases	Percentage (%)
Carcinoma of esophagus	I	Well differentiated squamous cell	4	21
	II	Moderately differentiated squamous	13	68
	III	Poorly differentiated squamous cell	1	5
		Adenocarcinoma	1	5

Table No: 04

VOLUME-6 | ISSUE-4 | APRIL - 2017 • ISSN No 2277 - 8179 | IF : 4.176 | IC Value : 78.46

Histopathological grading of Gastric Adenocarcinoma

Type of lesion	Grade	Type	No. of cases (13)	Percentage (%)
Carcinoma of stomach	I	Well differentiated Adenocarcinoma	3	23
	II	Moderately differentiated Adenocarcinoma	7	54
	III	Poorly differentiated Adenocarcinoma	1	8
		Mucin secreting Adenocarcinoma	2	15

Table No: 05

Correlation of Esophageal endoscopic and histopathological findings:

Endoscopic Findings	No of Cases	Percentage (%)	Histopathology Findings	No of Cases	Percentage (%)
Inflammation	4	16	Inflammation	1	4
Malignancy	21	84	Malignancy	23	92
			Inadequate	1	4

Table No: 06

Correlation of Stomach endoscopic and histopathological findings:

Endoscopic Findings	No of Cases	Percentage (%)	Histopathology Findings	No of Cases	Percentage (%)
Inflammation	56	75	Inflammation	50	67
Polyp	5	7	Polyp	4	5
Malignancy	14	19	Malignancy	13	17
			Inadequate	8	11

REFERENCES

1. Spaner SJ, Warnock GL. A brief history of endoscopy, laparoscopy, and laparoscopic surgery. J Laparoendosc Adv Surg Tech A. 1997;7:369–373.
2. Blackstone MO. Endoscopic interpretation. Normal and pathologic appearances of Gastrointestinal tract. New York: Raven Press; 1984. P 13--5.
3. Quine MA, Bell GD, McCloy RF, et al. Prospective audit of upper gastrointestinal endoscopy in two regions of England: safety, staffing, and sedation methods. Gut 1995;36:462–7
4. Zhang XF, Huang CM, Lu HS, Wu XY, Wang C, Guang GX et al. Surgical treatment and prognosis of gastric cancer in 2613 patients. World J Gastroenterol 2004; 10: 3405-3408.
5. EnzingerPC, Mayer RJ. Esophageal cancer. N Engl J Med 2003; 349: 2241-52.
6. National Cancer Registry Programme. First All India Report 2001-2002. Vol. 1. Indian Council of Medical Research Bangalore, India. April 2004.
7. Evan's D. MD, Craven JL, Murphy F and Clearly BK. Comparison of early gastric cancer in Britain and Japan. Gut 1978; 19: 1-9.
8. C.S Goodwin, JA Armstrong, BJ Marshall. Campylobacter pyloridis, gastritisand peptic ulceration. J Clinic Pathol 1986; 39: 353-365.
9. Liacouras C. A., Spergel J. M., Ruchelli E., et al. Eosinophilic esophagitis: a 10-year experience in 381 children. Clinical Gastroenterology and Hepatology. 2005;3(12):1198–1206. doi: 10.1016/s1542-3565(05)00885-2
10. Oxentenko A. S., Grisolano S. W., Murray J. A., Burgart L. J., Dierkhising R. A., Alexander J. A. The insensitivity of endoscopic markers in celiac disease. American Journal of Gastroenterology. 2002;97(4):933–938. doi: 10.1016/S0002-9270(02)03968-0.
11. Shennak MM, Tarawneh MS, Al Sheik. Upper gastrointestinal diseases in symptomatic Jordanians: A prospective study. Ann Saudi Med 1997; 17(4):471--474.
12. Khar HB, Umar M, Khurram M, Khan M, Mohammad Z, Goraya F et al. Endoscopic and histopathological evaluation of 306 dyspeptic patients.Pak j Gastroenterol 2003; 17: 4--7.
13. Paymaster JC, Sanghvi LD, Ganghadaran P. Cancer of gastrointestinal tract in western India. Cancer 1968; 21: 279-87.
14. Rupendra T, Mamta L, Pradeep KY, Prakash K, Choodamani A, Kamana S. Histopathological Study of endoscopic biopsies. J Nepal Med Assoc 2013;52(190):354--6.
15. Parloor K, Sarpangala MK. Narik RCN. Histopathology diagnosis of gastric biopsies in correlation with endoscopy a study in a tertory care centre. Adv lab Med Int 2013; 3(3); 22-31.
16. Uzma Bukhari, Rahim Siyal, Fayaz Ahmed, Javed Hussain Memon, Oesophageal carcinoma. A reveiw of endoscopic biopsies, Pak J Med Sciences 2009; 25 (5); 845-848
17. Bhurgari Y, Faridi N. Kazi LA, Ali SK, Bhurgari H. Usman A et al, cancer esophagus Karachi 1995-2002; epidemiology risk factors and trends J Pak Med Assoc. 2004;54 (7):345-8.