ORIGINAL RESEARCH PAPER

Volume-7 | Issue-6 | June-2018 | PRINT ISSN No 2277 - 8179

INTERNATIONAL JOURNAL OF SCIENTIFIC RESEARCH

HOLT-ORAM SYNDROME RARE HAND-HEART DISORDER

Paediatrics

Dr. Anita B sethi * From Department of Paediatrics, Modern Government Maternity Hospital, Osmania Medical College, Hyderabad (Telangana) *Corresponding Author

Dr.J.S. Ashwini Jyothi From Department of Radiology Modern Government Maternity Hospital, Osmania Medical College, Hyderabad (Telangana)

ABSTRACT

Back ground: Holt-Oram is rare autosomal disorder, clinically characterised by congenital cardiac defects and morphological abnormalities of the upper limbs.
Case characteristics:10 days old neonate born to first degree consangunious parents presented with upper limb anomaly and cardiac defects.
Obseravations : Hypoplastic left thumb with ASD, VSD and PDA was present.
Message- Neonate with upper limb anomaly should be evaluated for congenital hear disease.

KEYWORDS

Congenital heart defects, upper limb anomaly Holt-Oram syndrome.

Holt oram syndrome (also called atrio digital syndrome, atrio-digital dysplasia, cardiac-limb syndrome, heart-hand syndrome type1, HOS, ventriculo radial syndrome) is an autosomal dominant disorder that affects bones in the arms and hands(the upper limb) and often causes heart problems. It is rare disorder seen in 1 per 100,000 cases.

Case Report: 10 days old female baby weight of 2.4 kg,HC-33cm, L-52cm born to first degree consangunious marriage came in the out patient department for follow up. On examination there was systolic murmur in the parasternal area, without any signs of failure.

*Echocardiography was done and it showed ASD with subaortic VSD with PDA, moderate tricuspid atresia,moderate PAH.

*Left wrist had hypoplastic thumb with varus deformity.
The X-ray of left upperlimb showed the length of radius is less than ulna in the left fore arm s/o radius hypoplasia, medial deviation of wrist on left side s/o varus deformity. There was absence of 1st metacarpal bone, soft tissue protrusion in the place of left thumb with absence of phalangeal bones S/o hypoplasia of thumb.

Baby again came at the age of one month with the signs of congestive heart failure so it was referred to higher centre for further management.



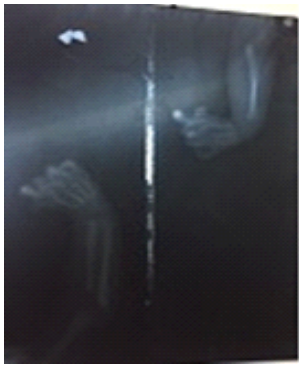

Discussion:
Holt- Oram syndrome is an autosomal dominant disorder most of the cases are of familial transmission. New mutations account for 40-85% of cases. It is due point mutation in TBX5 gene located on chromosome 12q 24.1. This results in transcription of dysfunctional protein in structural protein, resulting in phenotypic constellation with cardiovascular anomalies(3).TBX5 gene plays a key role in controlling the growth of bones in the hand and the arm. This gene also plays an important role in the course that segments the heart into four chambers. (4)Arm and hand defects – Abnormality in the bones of hand or arm is common. Commonly it is seen in the carpal bone of the wrist and thumb bones. Other defects are syndactyly, under developed radius (as in our case) ulna defects, humerus defects, reduced range of elbow, shoulder movements, Narrow shoulders, clavicle defects, scapula defects, sternum defects, hypoplasia of thumb, split thumbs, tripahalangeal thumbs, absence of first metacarpal, finger like thumb, Phacomelia, partial or complete absence of fore arm bones etc.

These skeletal defects may affect one or both of the upper limbs and bone abnormalities can be same or different on each side. The skeletal abnormalities are more common and severe on left side than on right side.

Cardiac defects – About 75% individuals have cardiac defects. Common defects are atrial septal defect and ventricular septal defect. Almost every type of cardiac anomaly has been reported either singly or as part of a complex heart disease. Rare but other cardiac associations include pulmonary stenosis, mitral valve prolapse, arrhythmias, conduction block, anomalous pulmonary venous return, tetralogy of fallot, AVSD (2).

To establish the extent of disease upper limb and hand radiograph and thorough cardiac evaluation with X-ray, ECG and echocardiography should be done.

The management of individuals with HOS involves a multidis ciplinary team approach with specialist in medical, genetics, cardiology and orthopedics.

The differential diagnosis include duane-radial ray syndrome (DRDS), acro-renal ocular syndrome (AROS), ulnar- mammary syndrome, Townes- Brocks syndrome, fanconi anemia, thrombocytopenia , absent radius syndrome (TAR), VACTERL disorder, teratogen exposure to thalidomide, valproate.

Conclusion: Family screening with X-ray of hands and electro cardiogram should always be done even if no clinical deformity is present and parents should be counselled (8).
Neonates with any visible birth defects should be screened for possible internal defects.

References:

1. Familial heart disease with skeletal malformation. Article in heart 22(2) 236-42 may 1960, Source: Pub med.
2. Dr. Shivani Rao, Dr. P.C. Nagi, Dr. Kunal mahajan, Holt-Oram syndrome . Revisted. Clinical images journal of cardiology 2017, 3(1) 21-22.
3. Avery's Neonatology (7th Edition) Pg no. 488.
4. Holt-Oram Syndrome Genetics home reference June 2014. http//ghs.nlm.nih.gov/condition/holt-oram syndrome accessed 9/16/2014.
5. Holt- oram syndrome, a case report and review of literature Virdis G, Dessole M, Dlessole S, Clin. Exp obstet gynecol 2016, 4391) 137.9
6. Basson CT, et al, the clinical and genetic spectrum of the Holt – Oram syndrome, N. Engl, J. Med. 1994; 330(13) 885-91.
7. Sinha R, Nemac, Rare cardiac defects in Holt –Oram syndrome, cardiovasc J. Afr.2012 (2) 83-4.
8. Shahid – Aktar, Siddiqui, et al Holt – Oram syndrome in an infant presenting with heart failure, Indian journal of child Health, Jan2017.