ORIGINAL RESEARCH PAPER
Volume-6 | Issue-10 | October-2017 | ISSN No 2277 - 8179 | IF : 4.176 | IC Value : 78.46
INTERNATIONAL JOURNAL OF SCIENTIFIC RESEARCH

IDIOPATHIC DECIDUAL CHANGE IN POSTMENOPAUSAL WOMEN- RARE CASE REPORT.

Pathology

DR. KULDIP SINGH CHAHAL	Department of pathology GMC, Amritsar
DR.NAVPREET KAUR	Department of pathology GMC, Amritsar
DR.SWATI	Department of pathology GMC, Amritsar

ABSTRACT

Decidualization of the endometrial stroma is an essential feature of the implantation stage of pregnancy. It denotes the transformation of endometrial stromal fibroblasts into specialized secretory decidual cells that provide a nutritive and immunoprivileged matrix essential for embryo implantation and placental development. progesterone induce secretory differentiation in endometrial glands and decidual-type change in the stroma . In the absence of a progestational stimulus , a decidual reaction in a postmenopausal women is very uncommon and encountered as an incidental finding . Common causes of postmenopausal bleeding includes endometrial atrophy, endometrial hyperplasia, endometrial carcinoma, In our case there is no evident exogenous and endogenous source of progesterone . After excluding all the causes of bleeding in postmenopausal, this report presents a case of idiopathic decidual change in an postmenopausal women which itself is the cause of bleeding. Diagnosis was achieved by histopathology and ultrasonography. we are presenting this case with the aim that decidual change in postmenopausal can be idiopathic and associated with bleeding with relevant review of literature.

KEYWORDS

decidulization, postmenopausal, idiopathic.

INTRODUCTION:

Decidualization is a process that results in significant changes to cells of the endometrium in preparation and during pregnancy. This includes morphological and functional changes to endometrial stromal cells (ESCs), the presence of decidual white blood cells , and vascular changes to maternal arteries. The sum of these changes results in the endometrium changing into a structure called the decidua. In humans, the decidua is shed during the third phase of birth Decidualization of uterine tissues is essential for protection of the conceptus against environmental and immunological insults and to ensure hemostasis and tissue integrity during deep trophoblast invasion. Postmenopausal bleeding is a common problem representing 5% of all gynaecology outpatient (1) . Common causes of postmenopausal bleeding includes senile atrophy .(2) Use of HRT, Endometrial hyperplasia: Nonatypical and Atypical, Endometrial cancer. The probability of a woman presenting with PMB having endometrial cancer is 10%. However, 90% of women with endometrial cancer present with PMB, Endometrial polyps or cervical polyps.(2) Cervical cancer Uterine sarcoma are rare causes. Ovarian cancer, especially oestrogen-secreting (theca cell) ovarian tumours, Vaginal cancer and Vulval cancer . Non-gynaecological causes including trauma or a bleeding disorder. In this case we did not find any above cause except decidual chane in endometrial biopsy.

CASE REPORT:

A 65-year-old married lady presented with a history of dysfunctional uterine bleeding on and off from 6 months. She is postmenopausal from 20 years. H/o pain lower abdomen present. On ultrasonography uterus is bulky, ms 8x6x6cm, no mass is seen, endometrial thickness is 28mm.No adnexal or ovarian mass is appreciated. On general physical examination patient's height is 5'2", weight is 68kg ,non obese, non diabetic, non hypertensive , euthyroid. The patient underwent D & C with a thought to rule out endometrial hyperplasia or carcinoma or some benign pathology but Microscopic findings revealed complete decidual transformation of stroma. The appearance of decidual cells are similar to that of decidual cells during pregnancy or after the administration of progesterone. Cells are characterized by sheets of large, polygonal cells with abundant amphophilic to eosinophilic cytoplasm with large nucleus and nucleoli seen. No e/o of mitoses or atypias seen.

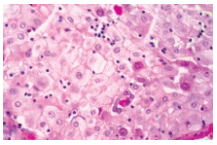

Decidual change reaction showing central nucleus with abundant cell cytoplasm with prominent cell border.

DISCUSSION:

An endometrial decidual reaction is in the absence of progesterone stimulation is very rare, to our best knowledge we have been able to find only four cases with decidual change recorded in postmeno pausal women, out of which 2 cases came out to be malignant, one was on hormones for pituitary tumour and other died due to liver disease (3) . Te Linde and Henriksen (4) reported 11 cases of premenopausal patients, 22 to 48 years of age, with an idiopathic intrauterine decidual reaction , in most of these cases the endometrial glands exhibited a secretory or hypersecretory appearance. None had received hormones. In all these cases, the possibility of intrauterine and extrauterine pregnancy was excluded and considered extremely unlikely. The authors speculated that the decidual reaction in their patients was probably secondary to prolonged or excessive function of corpus luteum. (5)

In contrast to extreme rarity of an idiopathic decidual reaction in the endometrium of postmenopausal women, a similar process is occasionally encountered in the ovaries of women in this age group. Ectopic decidua in such patients is said to be encountered most often on microscopic examination of otherwise unremarkable ovaries. (6-8). According to us, decidual change in ovaries in postmenopausal is usually explainable, causes include the granulosa cell tumour, hilus cell hyperplasia . Several cases of ovarian ectopic decidual reaction were not associated with a functioning ovarian lesion, but followed irradiation to the pelvis or were idiopathic.

The pathogenesis of decidual reaction in the patients described in this report is speculative. There is no history of progesterone intake. Functioning ovarian or adrenal lesions, which are possible sources of progesterone (9-13) are excluded or very unlikely. In this case ovarian lesions are ruled out as normal ovaries and adnexa on USG findings . Although functional adrenal tumors secrete progesterone, androgens, gluco or mineralocorticoids dominates the clinical picture (10,14). In our case hormonal studies are done showing normal progesterone levels suggests that decidual reaction was not a result of elevated levels of circulating progesterone.

In this case , we have described a decidual reaction in the endometrium who presented with postmenopausal bleeding. Although an endometrial decidual reaction is almost always a reflection of elevated circulating levels of progesterone, but an exogenous or endogenous source of progesterone excess could not be identified in this patient

CONCLUSION

After ruling out all the above causes of postmenopausal bleeding with the help of histopathology, USG, hormonal studies , we came to this conclusion that decidual change itself is the cause of post menopausal bleeding which is idiopathic.

REFERENCES

1. Moodley M, Roberts C; Clinical pathway for the evaluation of postmenopausal bleeding with an emphasis on endometrial cancer detection. J Obstet Gynaecol. 2004 Oct;24(7):736-41.
2. Munot S, Lane G: Modern management of post menopausal bleeding. Trends in Urology, Gynaecology and Sexual health. Vol 13. Issue 5. Sept 2008
3. Clement PB, Scully RE. Idiopathic postmenopausal decidual reaction of the endometrium. A clinicopathologic analysis of four cases. Int J Gynecol Pathol Off J Int Soc Gynecol Pathol. 1988;7(2):152–61.
4. Te Linde RW,Henriksen E. Deciduallike changes in the endometrium without pregnancy. Am j Obstet Gynecol 1940;39:733-49.
5. Reinhart HL. Diffuse decidual hyperplasia of the endometrium in the absence of pregnancy. Am J Clin Pathol 1935;5:365-70.
6. Bassis ML. Pseudodeciduosis. Am J obstet Gynecol 1956;72:1029-37.
7. Boss Jh, Scully Re, Wegner Kh, Cohen RB. Structural variations in the adult ovary-clinical significance. Obstet Gynecol 1965,25:747-63.
8. OberWB, Grady HG, Schoenbucher AK. Ectopic ovarian deciduas without pregnancy. Am J Pathol 1957;33:199-214.
9. Backstrom T, Mahlck C, Kjellgren O. Progesterone as a possible tumor marker for "nonendocrine" ovarian malignant tumors. Gynecol Oncol 1983;16:129-38.
10. Bertagna C, Orth DN. Clinical and laboratory findings and results of therapy in 58 patients with adrenocortical tumors admitted to a single medical center (1951to 1978). Am J Med 1981;71:855-74.
11. Jolls CJ, Beeson Jh, Abbott T. Progesterone production in adenocarcinomoma of the colon metastatic to the ovaries. Obstet Gynecol 1985;65:853-7.
12. Sasano N, Ojima M, Masudas T. Endocrinologic pathology of functioning adrenocortical tumors. In: Sommers SC, Rosen PP, eds. Pathology annual, 1980 part 2. New York: Appleton-century- crofts, 1980:105-41.
14. Tracy SL, Askin FB, Reddick RL, Jackson B, Kurman RJ. Progesterone secreting sertoli cell tumor of the ovary. Gynecol Oncol 1985;22:85-96.