Research Paper

Volume : 2 | Issue : 6 | June 2013 • ISSN No 2277 - 8179

Imidacloprid-Induced Nephrotoxicity in Male Rats

Medical Science

KEYWORDS : Imidacloprid, nephrotoxicity, vitamin C.

S. Soujanya — Department of Veterinary Pathology, College of Veterinary Science, Rajendranagar, Hyderabad 500 030, Andhra Pradesh, INDIA

M. Lakshman — Department of Veterinary Pathology, College of Veterinary Science, Rajendranagar, Hyderabad 500 030, Andhra Pradesh, INDIA

ABSTRACT

Protective role of vitamin C was assessed against imidacloprid-induced nephrotoxicity. Forty eight male Sprague dawley rats were divided into four groups of 12 animals in each. Group 1 served as control, while groups 2 and 4 were administered with imidacloprid (80 mg/kg b.wt) daily by oral gavage for 28 days. In addition to imidacloprid, group 4 also received vitamin C @ 10 mg/kg/oral daily for 28 days. Group 3 was maintained as vitamin C control (dose as above). At the end of 14th day, six rats from each group and the remaining at the end of 28th day were sacrificed. Blood samples were collected before sacrifice for sero-biochemical analysis. In group 2, a significant (P<0.05) increase in serum creatinine and decrease in GSH concentration in kidney was observed. In group 2, histological examination revealed pathologically significant changes. Co-treatment with vitamin C significantly (p<0.05) reversed the imidacloprid-induced nephrotoxicity.

INTRODUCTION

Imidacloprid, a neonicotinoid insecticide, is extensively used in agriculture for control of the sucking insects and coleopteran beetles (Cox, 2001) and also used as foliar treatment for soil and for seed dressing (Felsot, 2001). In Veterinary Medicine, it is used as flea control agent on dogs and cats (Hutchinson, Jacobs and Mencke, 2001). It is one of the fastest sold insecticide across the world because of its high selective toxicity in insects and apparent safety in humans. It acts on nervous system by blocking post synaptic acetylcholine receptors, which kills the insect (Tomizawa, Lee and Casida, 2005).

Vitamin C plays an important role in protection against insecticide-induced toxicity as an antioxidant agent and prevents the effect of free radicals on vital cells (Abd-El-Ghaney, 2002). Present study was conducted to evaluate the serum biochemical, tissue antioxidant, histopathological alterations induced by imidacloprid in kidney of male rats and protective role of vitamin C against imidacloprid-induced toxicity was also assessed.

MATERIALS AND METHODS

Chemicals

Imidacloprid was procured from GSP crop science Pvt. Ltd., Gujarat and Vitamin C was obtained from Abbott Health Care Pvt. Ltd., Bhiwandi.

Animals

Forty eight male Sprague dawley rats weighing 200-250 g were procured from National Institute of Nutrition (NIN), Hyderabad. The experiment was conducted as per CPCSEA guidelines and approved by the Institutional Animal Ethics Committee (Approval No. I / 3 / 2012).The rats were housed at lab animal house in the Department of Pharmacology & Toxicology, College of Veterinary Science, Hyderabad and were maintained in controlled environment (Temperature 20-22^{0}C). All the rats were provided ad libitum with standard pellet diet (procured from NIN) and water throughout the experimental period.

Experimental design

Following an acclimatization period of one week, the animals were divided into four groups consisting of 12 in each. Group 1 served as control, group 2 was treated with imidacloprid at the rate of 80 mg/kg b.wt, group 3 was treated with vitamin C at the rate of 10 mg/kg b.wt and group 4 was treated with both imidacloprid and vitamin C. These drugs were administered by oral gavage every day consequently for 28 days. At the end of 14th day, six rats from each group and remaining at the end of 28th day were sacrificed by cervical dislocation. Before sacrifice, blood was collected from retro-orbital plexus for studying serum creatinine levels.

Sero-biochemical markers

Creatinine was estimated in serum by using the standard diagnostic kits.

Antioxidant markers

Reduced glutathione (GSH) was estimated based on a reaction of reduced glutathione with 5-5 ditiobis-2-nitrobenzoic acid (DTNB) (Moron, Depierre and Mannervik, 1979).

Histopathology

For histopathological examination, the formalin fixed tissues were dehydrated through ascending grades of alcohol, cleared in three changes of xylene, and were embedded in paraffin. 5-micron thickness sections were cut and stained with H and E as per standard protocols (Luna, 1968).

Statistical analysis

The data were subjected to statistical analysis by applying one way ANOVA. Differences between means were tested using Duncan´s multiple comparison test and significance was set at P < 0.05.

RESULTS

In group 2, a significant (p<0.05) increase in mean values of creatinine (2.40 ±0.05 mg/dl) and reduction in GSH concentration (203.26 ± 0.18 µM/mg protein) was observed on day 14 and a similar trend was observed on day 28 following imidacloprid administration. Co-administration of vitamin C significantly (p<0.05) reversed the above values (Table 1).

H and E sections of kidney in imidacloprid treated group revealed cystic dilation of tubules, shrunken glomeruli [Fig. 1], vacuolation, presence of moderate inter tubular haemorrhages [Fig. 2] on 14th day, haemorrhages in glomeruli [Fig. 3] and hyaline casts [Fig. 4] on day 28. In group 3, no lesions of pathological significance were observed, whereas in group 4 animals, few inter tubular heamorrhages and vacuolation inside the tubules [Fig. 5] were observed.

DISCUSSION

In the present study, reduced GSH concentration was observed in group 2. This signifies the generation of free radicals that induced oxidative stress following imidacloprid treatment and this might be attributed to direct utilization of GSH as an antioxidant in terminating the free radical reaction resulting in exhaustion of the GSH, which was evident from significant increase in serum creatinine levels, histological alterations of pathological significance in kidneys of group 2 animals.

In group 2, kidney sections revealed cystic dilatation of tubules, shrunken glomeruli, vacuolation, inter tubular haemorrhages and hyaline casts. These results are in accordance with earlier

reports (Bhardwaj, Srivastava, Upasana and Srivastava, 2010) & (Kammon, Brar, Banga and Sodhi, 2010).

Vitamin C plays primary role in neutralizing free radicals. The free radicals will seek out an electron to regain their stability, vitamin C is an excellent source of electrons so it can donate electrons to free radicals such as hydroxyl and superoxide radicals and quench their reactivity (Bindhumol, Chitra and Mathur, 2003). In the present study, supplementation of vitamin C brought moderate protection in all the above parameters. The results of the present study were in agreement with previous studies, where supplementation of vitamin C brought improvement in histo architechture of kidney in Japanese quail (Omiama, 2004).

CONCLUSION

In conclusion, the study revealed that exposure to imidacloprid (80 mg/kg) in male rats affected renal function, which was evident from biochemical, tissue antioxidant, histological alterations in kidney. However, vitamin C supplementation along with imidacloprid to rats, manifested significant protective effects.

icotinoid insecticide toxicology, mechanisms of selective action. Annuals of Revised Pharmacology & Toxicology, 45, p. 247-268.

Table 1: Effect of vitamin C on serum biochemical and tissue antioxidant (GSH) parameters against imidacloprid induced toxicity in male rats

Group 1	Serum Creatinine (mg/dl)		GSH Concentration in kidney (µM/mg protein)	
	14th day	28th day	14th day	28th day
1	1.36 ± 0.01[c]	1.44 ± 0.01[c]	235.7 ± 0.22[a]	235.3 ± 0.18[a]
2	2.40 ± 0.05[a]	2.81 ± 0.03[a]	203.26 ± 0.18[c]	184.51 ± 0.18[c]
3	1.40 ± 0.02[c]	1.49 ± 0.01[c]	235.26 ± 0.18[a]	234.86 ± 0.10[a]
4	1.91 ± 0.04[b]	2.25 ± 0.07[b]	219.4 ± 0.20[b]	204.76 ± 0.17[b]

Values are mean ± SE; n=12; One way ANOVA
Means with different superscripts differ significantly (P<0.05).

Figure 1: Photomicrograph of kidney showing cystic dilation of tubules and shrunken glomeruli (Group 2, day 14): H&E X200

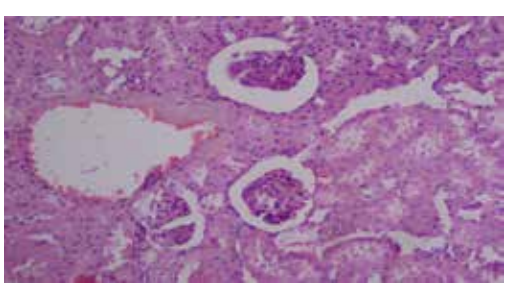

Figure 2: Photomicrograph of kidney showing vacuolation and moderate inter tubular haemorrhages (Group 2, day 14): H&E X200

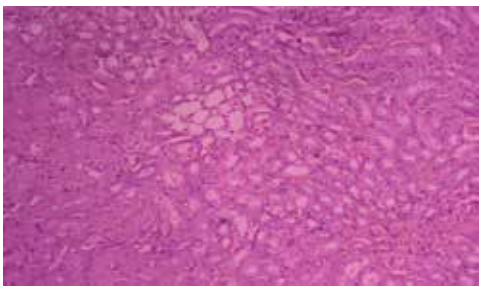

Figure 3: Photomicrograph of kidney showing haemorrhages in glomeruli (Group 2, day 28): H&E X200

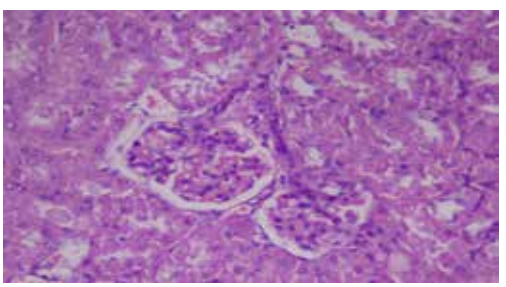

Figure 4: Photomicrograph of kidney showing hyaline casts, degenerated tubular epithelium and vacuolation in tubules (Group 2, day 28): H&E X 200

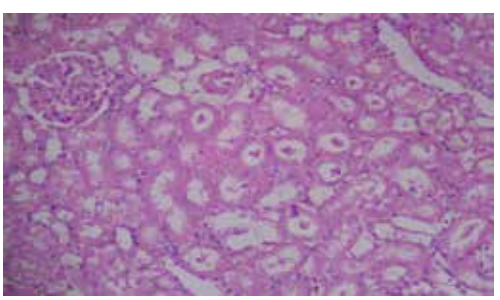

Figure 5: Photomicrograph of kidney showing few inter tubular heamorrhages and vacuolation inside the tubules (Group 4, day 28): H&E X 200

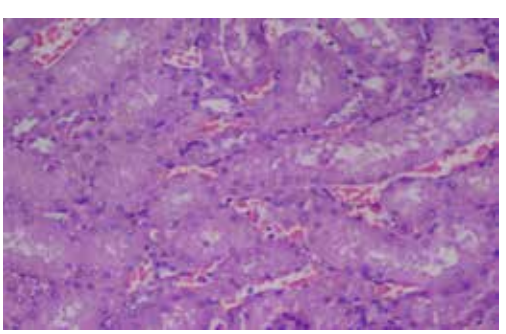

REFERENCE

1. Abd-El-Ghaney A. (2002) Study the effect of imidacloprid insecticide on some physiological parameters in Japanese quail. Thesis for M.Sc. Faculty of science, Al-Azhar University. | 2. Bhardwaj S., Srivastava M. K., Upasana K. and Srivastava L. P. (2010). A 90 days oral toxicity of imidacloprid in female rats morphological, biochemical& histopathological evaluation. Food and chemical toxicology, 48(5), p. 1185-1190. | 3. Bindhumol V., Chitra K. C. and Mathur P. P. (2003). A induces reactive oxygen species generation in the liver of male rats. Toxicology, 188, p. 117-124. | 4. Cox C. (2001). Imidacloprid- Expert overview. Germany. Bayer; | 5. Felsot A. (2001). Admiring risk reduction. Agrichemical Environmental News, 186. | 6. Hutchinson M. J., Jacobs D. E. and Mencke N. (2001). Establishment of the cat flea (Ctenocephalides felis) on the ferret (Mustela putorius furo) and its control with imidacloprid. Med. Veterinary Entomology, 15(2), p. 212-214. | 7. Kammon A. M., Brar R. S., Banga H. S. and Sodhi S. (2010). Pato biochemical studies on hepatotoxicity and nephrotoxicity on exposure to imidacloprid in layer chickens. Veterinarski arhiv, 80(5), p. 663-672. | 8. Luna G. L. H. T (1968). Manual of histological and special staining techniques. The Blakistone Divison McGraw-Hill Book Company, Inc. New York, Toronto London, 2nd edn., p. 1-5 and 9-34. . | 9. Moron M. S., Depierre J. W. and Mannervik B. (1979) Levels of glutathione, glutathione reductase and glutathione S transferase in rat lung and liver. Biochim Biophys Acta, 582, p. 67-78 | | 10. Omiama S. E. (2004). Protective effect of vitamin C and glutathione against the histopathological changes induced by imidacloprid in the liver and testis of Japanese quail. Egyptian journal of Hospital Medicine, 16, p. 39-54. | 11. Tomizawa M., Lee D. L. and Casida J. E. (2005) Neonicotinoid insecticide toxicology, mechanisms of selective action. Annuals of Revised Pharmacology & Toxicology, 45, p. 247-268. |