ORIGINAL RESEARCH PAPER
VOLUME-6 | ISSUE-6 | JUNE-2017 | ISSN No 2277 - 8179 | IF : 4.176 | IC Value : 78.46
INTERNATIONAL JOURNAL OF SCIENTIFIC RESEARCH

immediate implant placement along with bone augmentation and provisionalisation in esthetic zone-a case report

Dental Science

Dr Manoj Shetty
Dr Chethan Hegde
Dr Prashant kumar

KEYWORDS:

INTRODUCTION

Restoration of missing teeth in the esthetic zone is a great challenge for a clinician. The modern dentistry aims to restore the patient to normal contour, function, comfort, esthetics, speech, and health. There is loss of structural balance, inefficient oral function, poor esthetics and positional changes of remaining natural teeth whenever there is tooth loss. The adverse effects of tooth loss can be reduced by the replacement of teeth. The normal function, esthetics, comfort, or speech of patient cannot be recovered completely with a traditional removable prosthesis. The oral rehabilitation of edentulous and partially dentate patients by endosseous osseointegrated implants provides a predictable technique and outcome of final prosthesis.

When dealing with implant supported restorations, success, to a large extent, depends on the esthetic outcome. The "esthetic zone", represents the anterior region of maxillary jaw due to its high visibility and influence on facial appearance.[1] Thus the demand for good esthetic outcomes, for both the professional and the patient becomes an essential part and also a challenge in implant therapy.

Nowadays shortening the overall treatment period and minimising the number of surgical interventions in implant dentistry are expected by patients and clinicians with more emphasise given in the esthetic zone.[2] While restoring single missing tooth in the anterior maxilla, partial or total loss of interproximal papilla is one of the most common esthetic complications that we come across. Missing papilla would surely cause a cosmetic deficiency also known as the black triangle, as well as as phonetic problem. Thus the ultimate goal in restorative dentistry is to attain the "pink esthetics" in the esthetic zones. "Pink esthetics" includes the surrounding soft tissues, which comprises of interdental papilla and gingiva that can enhance or diminish the esthetic result.

Immediate restorations of dental implants may have many advantages, especially while restoring the anterior region, which is also known as esthetic zone. Although this zone may vary from person to person, it generally includes the maxillary and mandibular incisors, canines and premolars. Restoring teeth in this area is highly demanding, and it is in this region that immediate fixed restorations are of greatest benefits .

In addition to saving time , the potential to maximally preserve hard and soft tissues is another rationale for immediate implant and provisionalisation. The original midfacial gingival and interdental papilla can be mechanically supported by the provisional restoration and bone augmentation.

The purpose of this article is to present a case of immediate implant placement combined with simultaneous bone augmentation in a freshly extracted site followed by immediate provisionalisation.

CASE REPORT

A 40 year old female patient complained of mild discomfort and gingival problems in 11 region . She was in good general health, and her medical history was unremarkable. A clinical inspection of the oral cavity revealed a gingival swelling on the facial side of tooth 11, which had been restored with a provisional resin crown This symptomatic tooth had been treated with cast post and core and single crown. The periapical radiograph demonstrated a filled root canal cemented with a large metal post and core with no periapical radioluscency. Vertical bone levels of adjacent



PREOPERATIVE VIEW

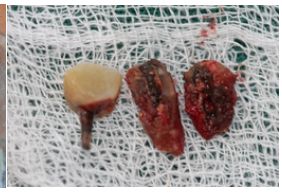

EXTRACTED TOOTH



OSTEOTOMY SITE PREPARED



IMPLANT PLACED



ALLOPLASTIC GRAFT MATERIAL IN SOCKET GAP



ABUTMENT PLACED



TEMPORISATION



FINAL PROSTHESIS

roots were well maintained.Immediate implant placement and provisionalization were the recommended treatment because of the patient's desire for a minimal number of surgical interventions and the maintenance of an esthetic appearance during the treatment procedures. The patient was informed about all relevant aspects of the proposed treatment, and she agreed to it.

The first step was the careful extraction of tooth 11 under local anesthesia using a 2% lidocaine solution with a vasoconstrictor. The metal post and core was dislodged at the beginning of this procedure, and then a full-thickness flap extended to the adjacent teeth using a sulcular incision was raised to extract the residual root. Root fragments were carefully removed with a periotome and appropriate forceps . The extraction socket was thoroughly debrided with caution to prevent infection and preservation of thin buccal plate. Implant site preparation was completed by following standard protocols using incremental

sharp spiral drills and copious saline. An ideal three-dimensional implant position was obtained. The drill was extended 3 to 4 mm apically to obtain minimum primary stability of 35-40 newton. The implant platform was planned to be located approximately 2 to 3 mm apical to the midfacial mucosal margin of the future implant crown. A 11 mm with 4.5 mm diameter tapered ANKYLOS implant was put in place .The implant achieved excellent primary stability. A small bony defect at the buccal site and a horizontal osteogenic gap between the residual buccal plate and implant body was found. A localized procedure was then undertaken using Bone substitute which was applied directly to the marginal gap between the buccal plate and implant surface and was filled with bone graft material . A temporary abutment was simultaneously inserted and tightened. A composite resin crown was fabricated chair-side and cemented into the implant abutment and adjusted with no occlusal contacts . The patient received analgesics and antibiotics for 3 days postsurgically. No complications were noted during the postsurgical healing period. After 3 months of temporary crown , the implant site had favorably healed. A periapical radiograph also confirmed that the implant was well-integrated after six months of follow up. Subsequently, the temporary abutment was replaced with a definitive full ceramic crown. The follow-up examination revealed stable, healthy peri-implant soft tissue profile . The patient was also satisfied with the esthetic outcome.

DISCUSSION

Successful clinical results has been achieved by submerging an implant in a freshly extracted tooth socket followed by immediate provisionalisation using composite resin within 48 hours of implant placement.Excellent esthetic outcomes were reported with immediate provisional restorations following immediate implant placements. One of the advantages of provisionalization following immediate implant placement is that it maintains better interproximal soft tissue height around the implant restorations. The maxillary anterior region is usually termed as an esthetic zone due to the high visibility and its influence on the appearance. Replacement of a single tooth in this region is one of the most important and difficult tasks to achieve. Implant supported single-tooth prosthesis can be a viable treatment option to restore a single missing tooth with an optimal esthetic outcome. The present case report is intended to evaluate the papillary fill and gingival zenith and the changes that is being brought about by the bone augmentation in the implant socket gap. The peri implant soft tissue was periodically evaluated at three months and six months follow up. At the end three months of follow up the result showed increase in the papillary volume along with no negative effect of recession of zenith of gingiva.

Interdental papilla can be mechanically supported by the provisional restoration and underlying bone grafting material grafted in the socket gap.This increase in volume can be attributed to maintenance of integrity of the socket walls. The placement of grafted material at the osteogenic gap helps in providing mechanical stability, better quality and faster bone formation along with delayed resorption of buccal plate of socket wall. Thus preventing the flattening of the interdental papilla and recession of zenith of gingiva.

References

1. Guido Schiroli. Immediate tooth extraction, placement of a tapered Screw-Vent® implant, and provisionalization in the esthetic zone: A Case Report. Implant Dent 2003; 12: 123-131.
2. Albrektsson T, Bra°nemark PI, Hansson HA, Lindstrom J.Osseointegrated titanium implants. Requirements for ensuring a long-lasting, direct bone-to-implant anchorage in man. Acta Orthop Scand 1981;52:155-70.
3. Lazzara RM. Immediate implant placement into extraction sites: surgical and restorative advantages. Int J Periodontics Restorative Dent 1989;9:333-43.
4. Chen S, Wilson Jr TG, Ha¨mmerle CH. Immediate or early placement of implants following tooth extraction: review of biologic basis, clinical procedures, and outcomes. Int J Oral Maxillofac Implants 2004;19(Suppl):12-25.
5. Chen S, Buser D. Advantages and disadvantages of treatment options for implant placement in post-extraction sites. In:Buser D, Wismeijer D, Belser UC, eds. ITI Treatment Guide.Implant Placement in Post-extraction Sites e Treatment Options, vol. 3. Berlin: Quintessence, 2008:36.
6. Jemt T. Restoring the gingival contour by means of provisional resin crowns after single-implant treatment. Int J Periodontics Restorative Dent 1999;19:20-9.
7. Degidi M, Piatelli A, Gehrke P, Carinci F. Five-year outcome of 111 immediate nonfunctional single restorations. J Oral Implantol 2006;32:277-85.
8. Schwartz-Arad D, Laviv A, Levin L. Survival of immediately provisionalized dental implants placed immediately into fresh extraction sockets. J Periodontol 2007;78:219-23.
9. Schroeder A, van der Zypen E, Stich H, Sutter F. The reactions of bone, connective tissue, and epithelium to endosteal implants with titanium sprayed surfaces. J Maxillofac Surg 1981;9:15-25.
10. Branemark PI. The Branemark Novum protocol for same-day tooth: a global perspectives. Chicago: Quintessence, 2001.9-29.
11. Ferrara A, Galli C, Mauro G, Macaluso GM. Immediate provisional restoration of postextraction implants for maxillary single-tooth replacement. Int J Periodontics Restorative Dent 2006;26:371-7.
12. Cornelini R, Cangini F, Covani U, Wilson Jr TG. Immediate restoration of implants placed into fresh extraction sockets for single-tooth replacement: a prospective clinical study. Int J Periodontics Restorative Dent 2005;25:439-47.