ORIGINAL RESEARCH PAPER VOLUME-6 | ISSUE-8 | AUGUST - 2017 | ISSN No 2277 - 8179 | IF : 4.176 | IC Value : 78.46

INTERNATIONAL JOURNAL OF SCIENTIFIC RESEARCH

IMMUNOHISTOCHEMICAL EXPRESSION OF PODOPLANIN IN ORAL EPITHELIAL DYSPLASIA.

Oral Pathology

Dr. Snehal Dilip Lunawat Senior lecturer, SMBT Institute of Dental Sciences and Research, Dhamangaon, nandihills, Nashik

Dr.Nilima Prakash Professor, MGV's KBH Dental college and hospital.Nasik

Dr.Pradeep G.L Reader, MGV's KBH Dental college and hospital. Nasik

Dr. Smita Jembu Chaware MDS Oral Pathology

Dr. Sushil Shivajirao Pawar MDS Oral Pathology

ABSTRACT

Introduction: The presence of epithelial dysplasia is generally accepted as one of the most important predictors of malignant development in pre – malignant lesions. Hence, evaluating the degree of dysplasia is important to envisage their potential for malignant transformation. Thus challenging the available methods of prognosis assessment and encourages the search for new and better molecular markers that relate comprehensively with known alterations of tumour initiation and progression.

Aim: To assess the expression of podoplanin (D2-40) in histopathologically confirmed cases of oral epithelial dysplasia and clinically normal oral mucosa.

Materials and Method: 30 histopathologically confirmed cases of oral epithelial dysplasia and 30 cases of clinically normal oral mucosa were immunohistochemically analysed for expression of podoplanin (D2-40).

Results: High expression of podoplanin was noted in the basal and suprabasal layers of oral epithelial dysplasia whereas the expression in normal oral mucosa was absent. The results of the study were statistically significant on analysis using One – Way ANOVA test in individual groups and Tukey's post hoc test for pairwise comparison.

Conclusion: Correct diagnosis and timely treatment of potentially malignant disorders may help prevent malignant transformation in oral lesions. The present study found statistically significant results in association with podoplanin expression in various grades of oral epithelial dysplasia (OED), thus providing insights into the onset and progression of the diseases.

KEYWORDS:

podoplanin, oral epithelial dysplasia, OSCC, malignant transformation

Introduction:

Oral squamous cell carcinoma (OSCC) is the second most frequent form of cancer and cause of death from cancer among males in South-East Asia. One third of global cases and one half of deaths from oral cancer occur in this region.[1] Oral squamous cell carcinoma (OSCC) can be preceded by the appearance of lesions which have the potential either to develop into cancer, or portend the development of cancer in the oral cavity.[2] These potentially malignant disorders can be detected up to 15 years, prior to their change to an invasive carcinoma.[3] The probability of malignant transformation of these lesions increases, when the epithelium shows severe dysplastic changes. Therefore, evaluating the degree of dysplasia is important to predict the potential for malignant transformation of oral potentially malignant disorders.[4] Correct diagnosis and timely treatment of potentially malignant disorders may help to prevent malignant transformation in oral lesions. Thus, most cancers and their related complications could be prevented through early detection.[5]

Podoplanin a 40 kDa O-linked sialoglycoprotein, expressed in lymphatic endothelial cells (LECs) can be recognized by a specific monoclonal antibody named D2-40. Podoplanin expression is completely restricted to LECs in vascular system, that allows to distinguish lymphatic vessels from blood vessels immunohistochemically.[6] Recent research has revealed the expression of podoplanin in some hyperplastic and dysplastic lesions adjacent to the primary oral cancers, suggesting that expression of podoplanin may occur in early oral tumourigenesis and may play a role in the malignant transformation[7]. However further studies are needed to fully define the functional role of podoplanin in oral cancer initiation and disease progression [8]. Hence, the present study attempts to assess the expression of podoplanin in oral epithelial dysplasia to investigate its possible role as a potential biomarker.

Materials and method:

The present study was a comparative study and sampling was done by convenient sampling method. An Ethical clearance was obtained from the institutional ethical committee and an informed consent was obtained from patients for the present study. The study group comprised of 30 histopathologically diagnosed cases of OED and 30 cases of normal oral mucosa. The normal oral mucosa samples were obtained during crown lengthening and disimpaction procedures.

Grading of oral epithelial dysplasia was done according to the system suggested by WHO (2005) [9]. Immunostaining with Podoplanin[10] (DAKO cytomation; monoclonal mouse; Anti human D2-40; Clone : D2-40 ;Isotype : IgG1,kappa; Ready-to-use) was performed using Sensitive novalink Polymer DAB detection kit[11].

Procedure:

Two sections of oral epithelial dysplasia of 3-4 µ thickness were obtained from formalin fixed paraffin embedded tissues using a semi-automated microtome (Thermoscientifics, Microm HM 340E). One section was stained with hematoxylin and eosin and another was immunostained with primary antibody against Podoplanin (D2–40).

Immunohistochemical staining:

Sections were placed on hot plate at 60°C for 10 minutes. Dewaxing was done using xylene followed by rehydration in ethyl alcohol. Then the slides were rinsed with distilled water for 5min.

Antigen retrieval:

Tri sodium citrate buffer solution (1000 ml distilled water with 2.94 grams of Tri sodium citrate buffer) at pH 6 was used for antigen retrieval.

Immunostaining[11]:

Blocking: The slides were covered with 3% hydrogen peroxide block (RE7165) reagent. The sections were incubated for 10min at room temperature in humid chamber and rinsed well with buffer wash. The tissues were then covered with protein block reagent (RE 7166) and incubated for 5-10 min at room temperature in humid chamber. The tissues were then gently blotted.

Labelling:
Tissues were covered with primary antibody (Anti human D2-40, Mouse monoclonal IgG1 kappa Dako USA, Ready-to-use). The slides were incubated for 1 hour at room temperature in humid chamber and rinsed well with wash buffer. Tissues were covered with post primary (RE7167) reagent and incubated for 30 min at room temperature in the humid chamber. The slides were then rinsed well with wash buffer. Sections were covered with Novalink polymer Horse Radish Peroxidase (HRP) (RE7168) reagent and incubated for 30min, at room temperature in the humid chamber. The slides were then rinsed well with wash buffer.

Tissues were covered with Substrate Solution [1µl Diaminobenzidine (DAB) chromogen] DAB- 3-3 (RE7169) reagent mixed with 6 µl of substrate buffer DAB (RE 7171) reagent and incubated for 10min, at room temperature in the humid chamber. The slides were rinsed well with wash buffer. The sections were counterstained with haematoxylin (RE 7172), dehydrated, cleared and mounted.

The immunopositivity of podoplanin was determined by presence of brown stained cells in the tissue sections with respect to cytoplasmic and membranous immunoreactivity suggested by Yaun P et al .,2006 [7]. The recommended positive control tissue was normal skin tissue.

Podoplanin positive cells quantification: [7]
For the quantitative analysis of Podoplanin positive cells, immunostained slides were examined under high power magnification (400x) of light microscope (Olympus CH 20*i*).

Podoplanin positive cells were counted manually per 1000 positive epithelial cells in oral epithelial dysplasia on randomly selected 10 microscopic fields. The slide was moved in a single direction to avoid repetition of already examined fields. Cell counting was performed by two examiners independently to avoid intraobserver bias.

The number of positively stained cells were quantified as a percentage of total number of positive cells counted to calculate the % positivity of cells in dysplasia.

$$\% \text{ positivity of epithelial cells} = \frac{\text{Number of Podoplanin positive cells}}{\text{Total number of cells observed (1000)}} \times 100$$

Statistical analysis:
Percentage distribution was used for demographic data. Descriptive statistics was used for discrete variables and summarized as mean with standard deviation and as number with percentage. Kruskal Wallis ANOVA, pair wise Tukey's post hoc test were applied to evaluate the differences among the mean values in different groups.

Results and observation:
On computing the demographic details pertaining to the age group in oral epithelial dysplasia, majority of the patients with oral epithelial dysplasia 16(53.33%) were in the age group of 20-40 years with a mean age of 42.66 years. On analysing the demographic data pertaining to the gender in oral epithelial dysplasia a definite male predominance was noted accounting for 26(86.66%) cases. On studying the site distribution of the lesions, buccal mucosa 18(60.00%) was the predominant site for oral epithelial dysplasia followed by gingivobuccal sulcus 5(16.66%) labial mucosa 5(16.66%) and alveolus 2(6.66%). (table 1)

Table 1: Distribution of oral epithelial dysplasia according to age group, gender and site.

	Age (years)			Gender		Site				
	20 - 40	41 -60	>60	Male	Female	Buccal mucosa	Gingival sulcus	Labial mucosa	Alveolus	Tongue
Total no. of cases (%)	16 (53.33)	12 (40.00)	2 (6.66)	26 (86.66)	4 (13.34)	18 (60.00)	5 (16.66)	5 (16.66)	2 (6.66)	0
Total (%)	30 (100)			30 (100)		30 (100)				

Table 2: Comparison of Podoplanin expression with histologic grades of oral epithelial dysplasia using One - Way ANOVA and pairwise comparison by Tukey's Post Hoc Test.

	Grades of oral epithelial dysplasia	n	Mean	Std. Dev.	ANOVA f value	p value
Percentage of Podoplanin positive cells	Mild	15	5.980	1.5548	65.050	0.000
	Moderate	9	23.911	12.7032		
	Severe	6	44.833	3.9707		
PAIR WISE COMPARISONS BY TUKEY'S POST HOC TEST						
Mild Vs. Moderate				0.000		
Mild Vs. Severe				0.000		
Moderate Vs. Severe				0.000		

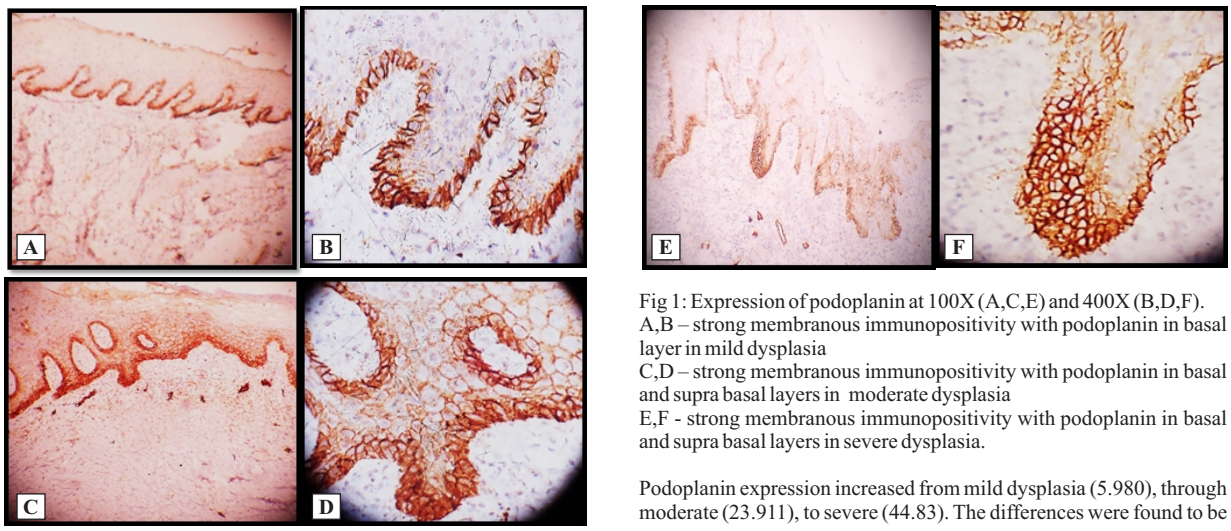

Fig 1: Expression of podoplanin at 100X (A,C,E) and 400X (B,D,F).
A,B – strong membranous immunopositivity with podoplanin in basal layer in mild dysplasia
C,D – strong membranous immunopositivity with podoplanin in basal and supra basal layers in moderate dysplasia
E,F - strong membranous immunopositivity with podoplanin in basal and supra basal layers in severe dysplasia.

Podoplanin expression increased from mild dysplasia (5.980), through moderate (23.911), to severe (44.83). The differences were found to be

statistically significant ($p<0.05$). Pair wise comparisons of Podoplanin expression and the histologic grade was found to be **statistically significant** ($p<0.05$) among groups under study.(table 2, fig 1)

Immunohistochemical positivity was absent in the normal oral mucosa tissue.

Discussion:

Podoplanin is a 38-KDa mucin type I transmembrane glycoprotein consisting of 162 amino acids, nine of which form the intracellular domain. The extracellular domain is highly O-glycosylated with sialic acid, α-2, 3 linked to galactose, forming the main part of the protein carbohydrate moieties.[12]

The concept of a step-wise transition from oral potentially malignant disorders (OPMD) to oral squamous cell carcinoma (OSCC) is well established, but it can be difficult to predict if and when an OPMD will undergo full transformation and result in a tumour. The presence of epithelial dysplasia in OPMD is generally accepted as one of the most reliable predictors of development of malignancy. However, histopathologic diagnosis is subjective and lacks sensitivity.[13]Thus, the challenge in the field of oral precancer is to predict which lesions will eventually develop into carcinoma.[14]

Hence, recent research is focused on identifying various markers for early cancer detection and prognostication.[6]

In the present study, podoplanin expression was assessed in normal oral mucosa and histological grades of oral epithelial dysplasia.

Expression was absent in normal oral mucosa. The difference in podoplanin expression was found to be statistically significant among histopathologic grades of oral epithelial dysplasia ($p<0.05$). Podoplanin expression progressively increased with the severity of dysplasia with the highest expression in severe oral epithelial dysplasia (fih 1 E, F). Pairwise comparison of podoplanin expression and the histopathologic grade of oral epithelial dysplasia was found to be statistically significant ($p<0.05$) among the various groups in our study. Our results are in concordance to a study performed by Li YY et al (2015)[15] where the podoplanin expression was enhanced as the severity of dysplasia increased.

Funayama et al (2011)[16] found statistically significant relationship between the histologic grade and podoplanin expression in oral epithelial dysplasia. It was related to the severity of oral precancerous lesions.

The expression of podoplanin has been found to be upregulated in a number of different human cancers, including squamous cell carcinoma of the lung, the cervix, the oesophagus, and the skin and oral cavity, in dysgerminomas of the ovary and granulosa cell tumour, in mesothelioma, and in many tumour of the central nervous system (CNS).[17] The high expression of podoplanin in severe dysplasia may reflect potential clonal expansion and a high risk of malignant potential. In fact, podoplanin has been identified as a marker of tumour-initiating cells (TICs) in squamous cell carcinomas. Tumourigenicity and capability of recapitulating human Squamous cell carcinoma are by definition properties of TICs. Premalignant lesions with podoplanin expression beyond the basal cell layer may represent truly early neoplastic lesions, enriched in TICs and with a higher risk of progression to invasive cancer.[17]

Limitations and Future perspective :

Some variances exist in our study which could result from the differences in the sample size, lack of uniformity in selection of grades of oral epithelial dysplasia Also, our study had a relatively small sample size and was unicentric. For clinical application, prospective studies involving larger numbers of patients are needed to further evaluate the clinical utility of podoplanin as a biomarker for oral cancer risk assessment providing additional value beyond the clinical and histological marker. On establishment of the role of podoplanin on invasion and tumourigenesis, podoplanin can serve as an effective therapeutic target.

Conclusion:

Assessment of podoplanin expression in oral epithelial dysplasia may aid in identifying the patients with higher risk of tumour initiation, progression and developing regional metastasis to determine whether overexpression of podoplanin in oral premalignant lesions may serve as a biomarker to predict the development of invasive cancer. Unlike all the previous studies done, the present study is novel as we have analysed intragroup podoplanin expression histological grades of oral epithelial dysplasia

References

1. Petti S, Masood M, Scully C. The Magnitude of Tobacco Smoking-Betel Quid Chewing-Alcohol Drinking Interaction Effect on Oral Cancer in South-East Asia. A Meta-Analysis of Observational Studies. PLOS ONE. 2013; 8(11):1-8.
2. Mithani SK, Mydlarz WK, Grumbine FL, Smith IM, Califano JA. Molecular genetics of premalignant oral lesions. Oral Diseases 2007; 13: 126–133.
3. Mahawar P, Anand S, Sinha U, Bansal M, Dixit S. Screening For Premalignant Conditions In The Oral Cavity Of Chronic Tobacco Chewers. National Journal of Community Medicine 2011; 2 (1): 82 -85.
4. Kujan O, Oliver RJ, Khattab A, Roberts SA, Thakker N, Sloan P. Evaluation of a new binary system of grading oral epithelial dysplasia for prediction of malignant transformation. Oral Oncol. 2006; 42(10):987-93.
5. Mortazavi H, Baharvand M, Mehdipour M. Oral Potentially Malignant Disorders: An Overview of More than 20 Entities. J Dent Res Dent Clin Dent Prospect. 2014; 8(1):6-14.
6. Logeswari J, Malathi N, Thamizhchelvan H, Sangeetha N, Nirmala SV. Expression of podoplanin in oral premalignant and malignant lesions and its potential as a biomarker. Indian J Dent Res. 2014; 25:305-10.
7. Yaun P , Temam S, El- Nagger A, Zhou X, Liu DD, Lee JJ, Mao L. Overexpression of Podoplanin in Oral Cancer and Its Association With Poor Clinical Outcome. Cancer 2006; 107(3):563 -569.
8. De Vicente JC, Rodrigo JP, Santa marta TR, Fernandez PL, Allonca E, Gracia-Pedrero JM. Podoplanin expression in oral leukoplakia: Tumourigenic role. Oral Oncology 2013; 49:598-603.
9. Barnes L, Eveson JW, Reichart P, Sidransky D, editors. Pathology and Genetics of Head and Neck Tumours. Lyon: IARC Press; 2005. World Health Organization Classification of Tumours.
10. Primary monoclonal antibody [package insert].California, USA: Dako Denmark.
11. Polymer detection system [package insert]. Newcastle, United Kingdom: Leica Biosystems.
12. Kashyap B, Reddy S. An Insight into Podoplanin – Emphasizing its Role in Oral Diseases. J Clin Exp Pathol. 2015; 5(3): 1-4.
13. Majeed A, Farah CS. Can Immunohistochemistry Serve as an Alternative to Subjective Histopathological Diagnosis of Oral Epithelial Dysplasia? Biomarkers in Cancer 2013; 5: 49–60.
14. Reibel J. Prognosis of oral pre-malignant lesions: significance of clinical, histopathological, and molecular biological characteristics. Crit Rev Oral Biol Med. 2003; 14(1):47 – 62.
15. Li YY, Zhou CX, Gao Y. Podoplanin promotes the invasion of oral squamous cell carcinoma in coordination with MT1-MMP and Rho GTPases. Am J Cancer Res. 2015; 5(2): 514-529.
16. Funayama A, Cheng J, Maruyama S, Yamazaki M, Kobayashi T, Syafriadi M et al. Enhanced expression of podoplanin in oral carcinomas in situ and squamous cell carcinomas. Pathobiology 2011; 78: 171-180.
17. Rodrigo JP, Carracedo DG, Gonzalez MV, Mancebo G, Fresno MF, Pedrero JG. Podoplanin expression in the development and progression of laryngeal squamous cell carcinomas. Molecular Cancer 2010; 48: 1-9.