Volume : 5 | Issue : 9 | September 2016 • ISSN No 2277 - 8179 | IF : 3.508 | IC Value : 69.48

Original Research Paper

Impact of Surgery on the Result of Anterior Mediastinal Tumors, a Variability

Medical Science

KEYWORDS : Anterior Mediastinum, Tumors

*** Dr Balaji Aironi**	Dr. PK Sen Department of Cardiovascular & Thoracic Surgery, Seth GS Medical College and King Edward Memorial Hospital, Parel, Mumbai, India.* Corresponding Author
Dr Rohit Shahapurkar	Dr. PK Sen Department of Cardiovascular & Thoracic Surgery, Seth GS Medical College and King Edward Memorial Hospital, Parel, Mumbai, India.
Dr Abhishek Joshi	Dr. PK Sen Department of Cardiovascular & Thoracic Surgery, Seth GS Medical College and King Edward Memorial Hospital, Parel, Mumbai, India.
Dr Ketak Nagare	Dr. PK Sen Department of Cardiovascular & Thoracic Surgery, Seth GS Medical College and King Edward Memorial Hospital, Parel, Mumbai, India.

ABSTRACT

The mediastinum is the chest cavity that separates the lungs from the rest. It contains heart, esophagus, trachea, thymus, and aorta. The mediastinum is divided into the anterior, the middle, and the posterior. The most common mediastinal masses are neurogenic tumors (20% of tumors), usually found in the posterior mediastinum, followed by thymoma (15-20%) located in the anterior mediastinum. Anterior mediastinal tumors include thymoma, lymphoma, pheochromocytoma, germ cell tumors including teratoma, thyroid tissue, and parathyroid lesions. Masses in this area are more likely to be malignant than those in other compartments. Thus, the diagnosis and the appropriate treatment of the tumors is a necessity. In benign tumors complete resection causes a good result. Surgical treatment is highly recommended in patients with locally recurrent tumors Hereby, a retrospective study was done to evaluate the various types of the anterior mediastinal tumors and the surgical impact on outcome, at our institute.

Introduction:

The mediastinum is divided into the anterior, the middle, and the posterior. The most common mediastinal masses are neurogenic tumors (20% of mediastinal tumors), usually found in the posterior mediastinum, followed by thymoma (15-20%) located in the anterior mediastinum.[5] Anterior mediastinal tumors include thymoma, lymphoma, pheochromocytoma, germ cell tumors including teratoma, thyroid tissue, and parathyroid lesions[3].

Thymomas, germ cell tumors, congenital cysts, lymphomas, neurogenic tumors, and thyroid tumors are usually seen in adult patients[1].

Germ cell tumor, lymphoma, congenital cysts, and thymomas rarely are found in the pediatric patients[1].

There was a significant higher incidence of neurogenic tumors and a lower incidence of thymomas and thyroid tumors in children than adults[1].

Patients are usually asymptomatic but can present with myasthenia gravis-related symptoms, substernal pain, dyspnea, or cough. The relation between thymoma and myasthenia gravis is intricate[4].

Invasive thymic tumors can produce compression effects such as superior vena cava syndrome[7,8.] Thymoma's are diagnosed with CT or MRI revealing a mass in anterior mediastinum. The decisive prognostic and therapeutic criteria depends on the Masaoka staging[1], WHO classification, and R0 status. Therapy in stage I tumors consists of surgical resection with good prognosis. Stage II-III requires maximal resection possible followed by radiation. Stage IV disease requires addition of cisplatin-based chemotherapy in addition to those in stage II and III. For those with invasive thymoma, treatment is based on induction chemotherapy, surgical resection, and post-surgical radiation. The benign thymoma was much better in the resectability and survival rate than the malignant thymoma. Surgical treatment of thymoma is the gold standard, and median sternotomy is the most frequently applied approach.

Lymphoma is the second most common primary anterior mediastinal mass in adults. Most are seen in the anterior compartment. Treatment of mediastinal Hodgkin's involves chemotherapy and/or radiation. Primary mediastinal B-cell lymphoma have exceptionally good prognosis.[10,11,12] Of all cancers involving the same class of blood cell, 2% of cases are mediastinal large B cell lymphomas.[13]

Common symptoms include fever, weight loss, night sweats, and compressive symptoms such as pain, dyspnea, wheezing, Superior vena cava syndrome, pleural effusions [12,13.]

Minority of patients with a mediastinal teratoma (including dermoid cyst) may cough up hair.[8]

Diagnosis is usually by CT showing lobulated mass. Confirmation is done by tissue biopsy of accompanying nodes either by, mediastinoscopy, mediastinotomy, or thoracotomy or CT guided FNA biopsy. But the tissue obtained by FNAB is usually not adequate [12,13].

Impact of surgery on the result of mediastinal tumors is variable:

In benign tumors such as teratoma, congenital cyst, intrathoracic struma and neurogenic tumor, a complete resection causes a good result.

Since complete resection of the invasive thymoma promises a good prognosis, excision of all the tumor and invading tissues followed by radiation therapy is recommended in the treatment of thymoma.

In pure seminoma resection and radiation therapy is the treatment of choice, while in non-seminomatous germ cell tumor, aggressive chemo- and radiation therapy should be performed, until tumor markers such as AFP and HCG become negative[1]. The operation is to be followed afterwards.

Volume : 5 | Issue : 9 | September 2016 • ISSN No 2277 - 8179 | IF : 3.508 | IC Value : 69.48

Bronchogenic cysts always require resection because of their high complication rate (66%) after conservative treatment. In these cases complete resection is necessary due to the probability of recurrence.

Surgical treatment is highly recommended in patients with locally recurrent tumors.

Hence, we have done a retrospective study of the patients presenting to us with anterior mediastinal mass, there morphological types and the surgical outcome of the patient in regard to the different types of masses.

Aims and objectives:
A retrospective study was done to evaluate:

- The morphological type of the anterior mediastinal mass.
- The impact of the surgery for the tumor and the modalities of the treatment available.
- 6 months Follow up of the patients.

Materials and methods:
A retrospective study of the patients those were operated at our institute was done from the period of 2010 to 2016.

Inclusion criteria:
1. All the patients who were diagnosed with the anterior mediastinal mass were included in the study. (CT guided biopsy)
2. The modality of the treatment given, to the patients were recorded.
3. All the patients were followed up regularly with 6 months duration.

Exclusion criteria:
The patients with mass other than the anterior mediastinum were excluded from the study.

The patients those were included in the study were given appropriate treatment as the protocols suggested for their respective tumors. The patients histopatholgy was studied after the surgery and were followed up 6 monthly. CT chest was done in some of the patients during the follow up.

Results:
120 patients were studied retrospectively who were the diagnosed cases of Anterior Mediastinal masses. All the patients had FNAB done prior to the surgery. 62(51.66%) patients were female and 58(48.34%) patients were male showing the female dominance. The mean age was 33.8 years with the lowest being 3 years of age. 110(91%) were of adult age group were as 10(9%) were pediatric patients.

73(60.83%) patients had diagnosed Thymoma's of which 61(50.83%) were non-invasive and 12(10%) were invasive. Of the Invasive Thymoma's 3(2.5%) were in Masaoka stage I, 7(5.8%) in stage II and 2(1.67%) were in stage III who presented with SVC syndrome. 65(54.17%) patients had associated symptoms of Myasthenia Gravis. Stage I cases were operated with complete excision of the tumor. While stage II were sent for radiation and followed who eventually lost for follow up.

All the non-invasive and stage I invasive were operated with complete excision of the mass and none showed recurrence after follow up. Patients with SVC syndrome needed emergency decompression.

Table 1: types of the anterior mediastinal tumors seen in the study.

Type	Sub-type	No. of cases	Total	Percentage
Thymoma	Non invasive	61	73	60.83%
	invasive	12		
Lymphoma	Hodgkin's	15	20	16.67%
	Non-Hodgkin's	4		
	B cell	1		
Teratoma		6	8	6.67%
	Dermoid cyst	2		
Bronchogenic cyst		6	7	5.83%
	CCAM	1		
Mediastinal cyst		4	6	5%
	Pericardial	2		
Germ cell tumors	Seminomas	2	6	5%
	Non Seminomas	3		
	Mixed malignant	1		

20(16.67%) cases were diagnosed as lymphoma's, 15(12.5%) of which were Hodgkin's type and 4(3.33%) cases were non-Hodgkin's. 1(0.83%) patient had B cell lymphoma. All these were given chemotherapy and were referred to medical oncology for further management.

8(6.67%) patients had Teratoma of which 2(1.67%) had Dermoid cyst and had underwent complete excision of the tumor.

6(5%) patients had Germ cell tumors, of which 3(2.5%) were of Seminoma and were treated with radiation. 2(1.67%) patients were non-Seminomatous germ cell tumors and were treated with chemo and radiation therapy as per the AFP and HCG levels. One (0.83%) patient had inconclusive diagnosis which after surgery the histopathology turned out to be germ cell tumor with high grade mixed malignancy. This patient was referred for chemo and radiation therapy post operatively and had very high levels of AFP and HCG.

6(5%) patients had congenital mediastinal cyst and 2(1.76%) of which were pericardial cysts and all underwent surgery.

7(5.83%) patients were diagnosed as bronchogenic cysts of which 2(1.67%) were giant occupying the whole of the lung field. All were operated with 1(0.83%) turned out to be Congenital Cystic Adenomatoid Malformation (CCAM).

In the pediatric age group 4(3.33%) were thymoma's, 2(1.67%) were pericardial cysts, 2(1.67%) were mediastinal cyst, 2(1.67%) were non-Hodgkin's lymphoma's who were referred to oncology for chemotherapy.

Table 2: Pediatric Anterior Mediastinal Tumors

Type of tumor	Subtype	No. of cases	Percentage	
Mediastinal cysts	Pericardial	2	1.67%	
	simple	2	1.67%	
Non Hodgkin's		2	1.67%	
Thymoma	Non invasive	4	3.33%	

Discussion:

Anterior mediastinal tumors include thymoma, lymphoma, pheochromocytoma, germ cell tumors including teratoma, thyroid tissue, and parathyroid lesions[3]. Thymoma is the most common primary anterior mediastinal tumor (20% of all mediastinal) in adults but rarely seen in children[2].

Our study also showed the same, with almost 60.83% cases of thymoma's and 39.17% cases of lymphomas (16.67%) as compared to others. Thymomas can be classified as lymphocytic, epithelial, or spindle cell histologies, but the clinical significance of these classifications is controversial.[9] Tonofibrils seen under electron microscopy can differentiate Thymoma from other tumors such as carcinoid, Hodgkin's, and seminoma. All the noninvasive and stage I invasive tumors were operated with complete resection with no recurrence and mortality. Thus, surgery provided complete excision of thymoma's. 5-year survival for invasive thymoma is between 12-54% regardless of any myasthenia gravis [1,9,10].

Hodgkin's usually present in 40-50›s with nodular sclerosing type [11,] and non-Hodgkin's in all age groups. This was seen in our studies also were only one pediatric case had non-Hodgkin's and all others were in the age group of 40 yrs. All of these patients were referred for chemotherapy. 5 year survival is now around 75% [(15).] Large-cell type may have somewhat better prognosis. Surgery is generally not performed because of invasive nature of tumor.

6.67% patients had Teratoma of which 1.67% had dermoid cyst which was a rare feature and had underwent complete excision of the tumor with good results and no recurrence.

5% patients had germ cell tumors, of which 2.5% were of Seminoma and were treated with radiation with complete cure. 1.67% patients were non-Seminomatous Germ cell tumors and were treated with chemo and radiation therapy as per the AFP and HCG levels. 0.83% i.e 1 patient had inconclusive diagnosis which after surgery the histopathology turned out to be germ cell tumor with high grade mixed malignancy. This patient was referred for chemo and radiation therapy post operatively and had very high levels of AFP and HCG.

5% patients had congenital mediastinal cyst and 1.76% of which were pericardial cysts and all underwent surgery that corresponds to the standard papers.

5.83% patients of bronchogenic cysts were operated, of which 1.67% was giant, occupying the whole of the lung field. All were operated successfully with complete resection and with 1patient turned out to be Congenital Cystic Adenomatoid Malformation (CCAM).

In the pediatric age group 4(3.33%) were thymoma's, 2(1.67%) were pericardial cysts, 2(1.67%) were mediastinal cyst, 2(1.67%) were non-Hodgkin's lymphoma's who were referred to oncology for chemotherapy.

Conclusion:

Thus to conclude with, the impact of surgery on anterior mediastinal tumors is variable and depends on the type of the tumor. Non invasive Thymoma's and the early invasive has complete resectabilty without any recurrence and same with the mediastinal cysts and teratoma's. Even invasive thymomas surgery followed by radiation shows good results and resectibility. The lymphomas are uasually invasive and the surgical results are always incomple with high recurrence and chemotherapy is the preferred modality of treatment, and the five year survival rate is almost 75%. Seminomas are radiosensitive and offer complete cure while non seminomas need combined chemo and radiotherapy.

As almost all the anterior mediastinal tumors are benign and have complete resectibility, pre-operative diagnosis plays important role. And hence anterior mediastinal tumors must be subjected to surgery unless otherwise proven to be malignant.

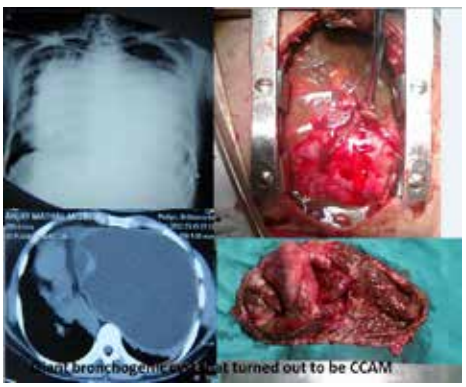



Giant germ cell tumor that turned out to be mixed malignant

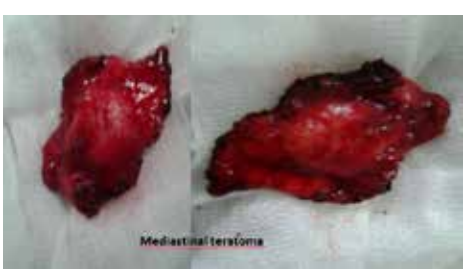

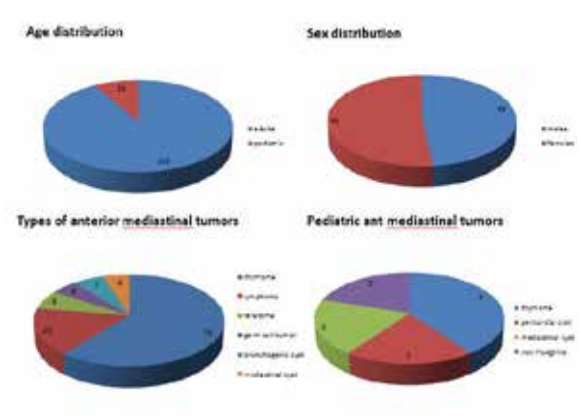

Volume : 5 | Issue : 9 | September 2016 • ISSN No 2277 - 8179 | IF : 3.508 | IC Value : 69.48

References:

1. Clinical spectrum of primary mediastinal tumors: a comparison of adult and pediatric populations at a single Japanese institution. Takeda S1, Miyoshi S, Akashi A, Ohta M, Minami M, Okumura M, Masaoka A, Matsuda H J Surg Oncol. 2003 May;83(1):24-30.
2. Thymoma. A clinicopathologic study of 98 cases with special reference to three unusual cases. Hofmann W, Möller P, Manke HG, Otto HF. Pathol Res Pract. 1985 Jan;179(3):337-53.
3. Presentation of primary mediastinal masses in Ibadan. Adegboye VO1, Ogunseyinde AO, Obajimi MO, Ogunbiyi O, Brimmo AI, Adebo OA. East Afr Med J. 2003 Sep;80(9):484-7.
4. Malignant thymoma associated with myasthenia gravis, and evidence of extrathoracic metastases. An analysis of published cases and report of a case. Guillan RA, Zelman S, Smalley RL, Iglesias PA Cancer. 1971 Apr;27(4):823-30.
5. "Neurogenic Tumors of the Mediastinum". Retrieved 28 July 2012.
6. Macchiarini P, Ostertag H (February 2004). "Uncommon primary mediastinal tumours". Lancet Oncol. 5 (2): 107–18. doi:10.1016/S1470-2045(04)01385-3.PMID 14761815.
7. Davis RD, Oldham HN, Sabiston DC (September 1987). "Primary cysts and neoplasms of the mediastinum: recent changes in clinical presentation, methods of diagnosis, management, and results". Ann. Thorac. Surg. 44 (3): 229–37.doi:10.1016/S0003-4975(10)62059-0. PMID 2820323.
8. Cabot, Richard C (1919). Physical diagnosis (7th ed.). New York: William Wood and Company. p. 527.
9. Kuo TT (2001). "Classification of thymic epithelial neoplasms: a controversial issue coming to an end?". J. Cell. Mol. Med. 5 (4): 442–8. doi:10.1111/j.1582-4934.2001.tb00182.x. PMID 12067481.
10. Rosenwald A, Wright G, Leroy K, et al. (September 2003). "Molecular diagnosis of primary mediastinal B cell lymphoma identifies a clinically favorable subgroup of diffuse large B cell lymphoma related to Hodgkin lymphoma". J. Exp. Med. 198(6): 851–62. doi:10.1084/jem.20031074. PMC 2194208. PMID 12975453.
11. Rodríguez J, Gutiérrez A, Piris M (June 2008). "Primary mediastinal B-cell lymphoma: treatment and therapeutic targets". Leuk. Lymphoma. 49 (6): 1050–61.doi:10.1080/10428190801958994. PMID 18452109.
12. Savage KJ (May 2006). "Primary mediastinal large B-cell lymphoma".Oncologist. 11 (5): 488–95. doi:10.1634/theoncologist.11-5-488. PMID 16720849. Retrieved 2009-01-14.
13. Turgeon, Mary Louise (2005). Clinical hematology: theory and procedures. Hagerstown, MD: Lippincott Williams & Wilkins. p. 283. ISBN 0-7817-5007-5.Frequency of lymphoid neoplasms. (Source: Modified from WHO Blue Book on Tumour of Hematopoietic and Lymphoid Tissues. 2001, p. 2001.)