Research Paper

Volume : 4 | Issue : 3 | March 2015 • ISSN No 2277 - 8179

Incidence and distribution of normal intracranial calcifications in adults on computed tomography.

medical science

KEYWORDS :Normal, calcification, brain, CT

Dr. Manash Kumar Bora,MD	Associate Professor, Department of Radiology, AVMCH, Pondicherry-607402, India
Dr. Kaveri Sharma, MD	Assistant Professor, Department of Obstetrics & Gynecology, AVMCH, Pondicherry-607402, India
Dr.S.Vithiavathi, MD	Professor and HOD, Department of General Medicine, AVMCH, Pondicherry-607402, India
Dr.Siddhartha Ram S	Second year post graduate student, Department of Radiology, AVMCH, Pondicherry-607402, India
Dr.Fazil Moidu	Second year PG student, Department of Radiology, AVMCH, Pondicherry-607402, India
DR .M.Vignesh	Second year PG student, Department of Radiology, AVMCH, Pondicherry-607402, India
Dr. B.P Venkatesh	Professor, Department of Radiology, AVMCH, Pondicherry-607402, India

ABSTRACT

Aim of the study: The aim of the study was to evaluate the incidence and frequency of normal physiological calcifications in brain in adult subjects with Computerized Tomography(CT).Physiological calcifications are seen in the choroid plexus, falx , tentorium cerebella ,pineal gland, habenula, basal ganglia, vessel walls including venous sinus and in meninges like dural calcifications. These calcifications are not accompanied by any focal or diffuse pathology of brain.

Materials and methods: A total of 1537 subjects were evaluated over a period of two years in this study. The patients were from 20 to 80 years of age from both sex . These patients were referred for CT scan of brain having complaints like headache, diplopia, seizure, focal neurological deficit etc to name a few requiring neuroimaging for a diagnosis. All these patients has a normal study and had one or more areas of normal physiological calcifications.

Results and observations: The study had 1537 subjects from 20 to 80 years of age, of which 52.5% were males 47.5% were females. The highest number of calcification was found in pineal gland(72.4%). It was followed by choroid plexus(68.2%), habenula(20.1%), vascular(8.2%), falx(1.4%) and basal ganglia(1%) calcifications. The least number of calcifications was seen in tentorium cerebella(0.8%) .The size of calcifications was from 4 mm to 10 mm with most calcifications having a average size of 4 mm to 5 mm(71%). The largest calcified area was choroid plexus calcification having average dimension of 8 mm to 10 mm.

With respect to combined calcifications ,70.3% subjects had calcifications in both pineal and choroid plexus, followed by calcifications in pineal and habenula accounting for 46.25% Choroid and habenular calcifications was seen in 44.15% of subjects.

Conclusion: We conclude that the normal physiological calcifications in brain have a documented location where they usually occur, unlike pathological calcifications. A thorough knowledge of the same is essential for the both the radiologist and practising physician for accurate evaluation of brain in neuroimaging modalities like CT

Introduction:

Intracranial calcifications occurs both in normal and abnormal cranial tissues.

Normal physiological intracranial calcifications occurs due to deposition of calcium and less often iron in the blood vessels of different structures of the cranium.

In normal conditions calcium deposits are usually seen in the tunica media of cranial blood vessels **[1].**

Normal physiological calcifications are usually seen in the choroid plexus, falx , tentorium cerebella ,pineal gland, habenula, basal ganglia, vessel walls including venous sinus and in meninges like dural calcifications [2, 3, 4].There is no demonstrable focal or diffuse pathological cause in the brain or any systemic disorder in the body.

There are different modalities to look for intracranial calcification like ultrasonography (in infants),radiography, CT and Magnetic Resonance Imaging of which CT is the gold standard for evaluation [5].This is because of poor beam penetration by ultrasound in ossified bones of older child and adults and decreased signal in MRI due to low proton density in calcification. Radiography is not sensitive to subtle calcifications due to overlapping cranial bones.

The distribution and appearance of pathological from normal intracranial calcifications is usually different but many a times overlapping and confusing. Familiarity with CT findings such as physiological or pathological calcifications is important for proper diagnosis and management of cases. Hence in this study we evaluated the normal appearances of intra cranial calcification with CT in 1537 patients over a period of two years with respect to various parameters like pattern,incidence, frequency , location etc.with the hope that it will give a reasonably good overview to the practicing radiologist and clinician on this subject matter.

Materials and Methods:

This study was done in Aarupadai Veedu Medical College and Hospital, Pondicherry over a period of two years from December 2012 to December 2014.

Inclusion criteria used were:

All the patients referred to Department of Radiology for CT scan of brain having indications for such scan like headache ,diplopia , focal neurological deficit ,seizure, suspected pituitary adenoma , post partum suspected pituitary apoplexy etc. to name a few.

Patients from twenty years of age and above from both sex.

Exclusion criteria used were :

Diagnosed cases of systemic disorder of metabolism and endocrinopathies referred for CT scan of brain

Patients having a positive documentation of a pathology in the current CT scan,

Patients with head injury referred for CT scan of brain

Patients undergoing contrast enhanced scans.

CT Scans having streak artifacts due to metallic objects like dental implants or motion artefacts on any region of the brain were excluded from the study.

Calcification of lens was excluded from the study as it was considered outside the cranial cavity containing the brain.

Based on above parameters 1537 patients were enrolled in to the study.

The equipments used were Toshiba Asteion VF spiral CT and GE Brivo CT385 series 16 slice spiral CT scanners.

After positioning the patient for CT scan of brain, volumetric acquisition of data was done by scanning from cantho-meatal line to vertex. Slice thickness used was 5 mm, slice interval gap of 10 mm and reconstruction was done to 1.25 mm.

Automated multiplanar reconstruction was done and images were displayed in coronal ,saggital and volume rendered formats apart from axial views.

The densitometry is used with Hounsfield Units (HU) while differentiating various soft tissues in the cranium. The average density of calcifications were 100 Hounsfield Units (HU). The commonest pathology which is seen as hyperdense lesion is acute hemorrhage with HU values of 60 to 80 HU which was easily differentiated from calcification having HU values of 100 and above.

The areas looked for normal calcifications were basal ganglia, pineal gland, habenula, choroid plexus, dura and dural folds (falx and tentorium), venous sinuses and arterial calcification.

The calcified areas were further evaluated for their size in millimeters, numbers, pattern of calcification (nodular or amorphous) and average density (HU values).

The data collected was analyzed with respect to frequency of occurrence in different locations in the brain in different age group intervals and sex.

Results and Observations:

For ease of calculation the subjects were divided in to six age groups.

They were 20 to 30 years(17%), 31 to 40 years(22%), 41 to 50 years (30%), 51 to 60 years(14%), 61 to 70 years(12%) and 71 to 80 years(5%).

The study group had 1537 subjects, of which 52.5% were males and 47.5% were females. The mean age was 47.5 for males and 45.0 for females, age ranging from 20 to 80 years in both groups.

Table 1 represents the age group ,number of subjects, frequencies and percentages of male and females in the study sample.

Table 1. Frequencies and percentages of age and sex distribution of the study sample. n = 1537

Age Group	Males		Females		Total	
	Frequency	Percentage	Frequency	Percentage	Frequency	Percentage
20-30	139	53.9	119	46.1	258	17
31-40	189	55.4	152	44.6	341	22
41-50	216	46.7	246	53.2	462	30
51-60	102	47	115	53	217	14
61-70	115	62.5	69	37.5	184	12
71-80	46	61.3	29	38.7	75	5
Total	807	52.5	730	47.5	1537	100

Table 2 shows the number of subjects in each age group with respect to male and female , frequency and percentage of calcifications in different locations in brain.

Table 2. Calcifications in various intracranial structures for different age and sex groups.

Age Group	No. of Patient	Pineal		Choroid		Habenula		Vascular		Falx		Basal		Tentorium	
		FQ	%	FQ	%	FQ	%	FQ	%	FQ	%	FQ	%	FQ	%
20 - 30															
Male	139	84	60.4	61	43.9	14	10	1	0.7	0	0	1	0.7	0	0
Female	119	69	58	47	39.5	11	9.2	1	0.8	0	0	0	0	0	0
Total	255	152	59.6	108	42.4	25	9.8	2	0.8	0	0	1	0.4	0	0
31-40															
Male	189	141	74.6	123	65	33	17.5	8	4.2	0	0	1	0.5	1	0.5
Female	152	106	69.7	98	64.5	25	16.4	5	3.3	0	0	1	0.6	1	0.5
Total	330	247	74.8	221	67	58	17.6	13	3.9	0	0	2	0.6	2	0.6
41-50															
Male	216	173	80	162	75	52	24	28	13	0	0	1	0.4	2	0.9
Female	246	181	73.6	175	71.1	61	24.8	32	13	0	0	1	0.4	1	0.4
Total	450	354	78.7	337	74.9	113	25.1	60	13.3	0	0	2	0.4	3	0.7
51-60															
Male	102	89	87.2	86	84.3	28	27.5	12	11.8	2	2	0	0	2	2
Female	115	77	67	81	70.4	23	20	11	9.6	3	2.6	0	0	2	1.7
Total	217	166	76.5	167	77	51	23.5	23	10.6	5	2.3	0	0	4	1.8
61-70															
Male	115	97	84.3	102	88.7	28	24.3	14	12.2	7	6	3	2.6	1	0.9
Female	69	41	59.4	54	78.3	14	20.2	7	10.1	4	5.7	2	2.9	1	1.4
Total	184	138	75	156	84.8	42	22.8	21	11.4	11	6	5	2.7	2	1
71 - 80															
Male	46	37	80.4	39	84.8	13	28.3	5	10.9	3	6.5	4	8.7	1	2.1
Female	29	19	65.5	21	72.4	8	27.6	3	10.3	2	6.9	2	6.9	0	0
Total	75	56	74.7	60	80	21	28	8	10.7	5	6.7	6	8	1	1.3
Total															
Male	807	621	77	573	71	168	20.8	68	8.4	12	1.5	10	1.2	7	0.9

Female	730	493	67.5	476	65.2	142	19.5	59	8	9	1.2	6	0.8	5	0.7
Total	1537	1114	72.4	1049	68.2	310	20.1	127	8.2	21	1.4	16	1	12	0.8

Almost all subjects in the study sample had one or more areas of normal physiological calcifications in the brain.

The highest number of calcification was found in pineal gland**(Fig.1).** Sex and age group wise it was highest in males from 41 to 50 years.

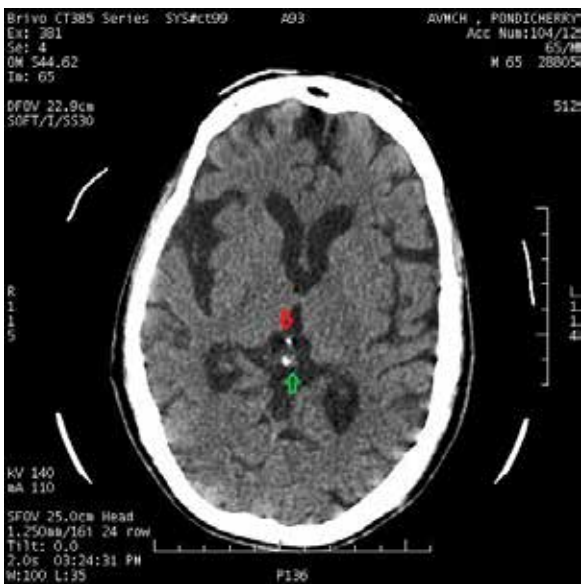

Fig.1: Axial section through the level of pineal gland showing calcified habenula(red arrow) and pineal gland(green arrow)

It was followed by choroid plexus**(Fig.2),** habenula**(Fig.1),** vascular**(Fig.3 ,Fig.4 and Fig.5),** falx**(Fig.6)** and basal ganglia calcifications **(Fig.7)**.

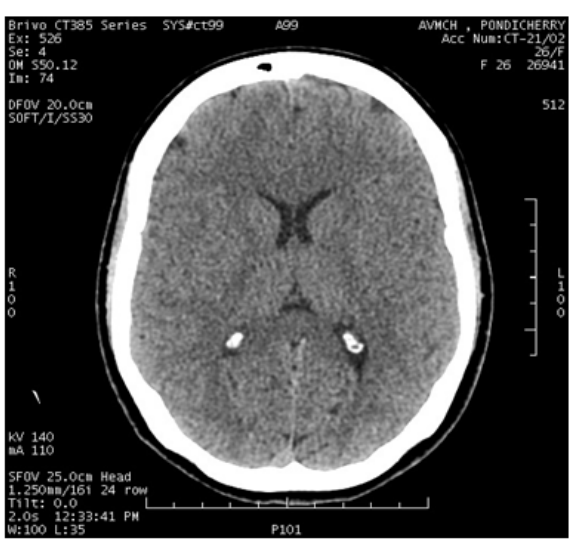

Fig.2: Axial section through the level of choroid plexus showing its calcification



Fig.3: Axial section at the level of foramen magnum showing left vertebral artery calcification



Fig.4: Axial section at the level of circle of Willis showing calcified right internal carotid artery



Fig.5: Axial section through posterior fossa showing right occipital sinus calcification.



Fig.6: Axial section at the level of high parietal lobes showing falx cerebri calcifications



Fig.7: Axial section at the level of basal ganglia showing symmetrical basal ganglia calcifications



The least number of calcifications was seen in tentorium cerebella **(Fig.8)**.

Fig.8: Axial section through posterior fossa showing calcifications in both half of tentorium cerebelli

Table 3. shows the frequency and percentage of commonly occurring combined calcifications in different age groups.

Age Group	Pineal & Choroid		Pineal & Habenula		Choroid & Habenula	
	%	%	%	%	%	%
20-30	59.6	42.4	59.6	9.8	42.4	9.8
31-40	74.8	67	74.8	17.6	67	17.6
41-50	78.7	74.9	78.7	25.1	74.9	25.1
51-60	76.5	77	76.5	23.5	77	23.5
61-70	75	84.8	75	22.8	84.8	22.8
71-80	74.7	80	74.7	28	80	28
Total	72.4	68.2	72.4	20.1	68.2	20.1
Avg	70.3%		46.25%		44.15%	

70.3% subjects had calcifications in both pineal and choroid plexus (72.4% in pineal and 68.2% in choroid plexus), it was the highest among any two areas of combined calcifications.

It was followed by calcifications in pineal and habenula accounting for 46.25% (72.4% in pineal and 20.1% in habenula).

Both Choroid and habenular calcifications was seen in 44.15% of subjects(choroid 68.2% and habenular 20.1%).

Table 4. shows the size, patterns of and average density of calcifications.

Location	Size in mm	Pattern of Calcification	Average density
Basal Ganglia	4-6 mm	A	90-100
Pineal gland	5-6 mm	N	120-150
Habenula	4-5 mm	N	120-130
Choroid Plexus	8-10 mm	A+N	120-150
Falx	4-5mm	A+N	100-110
Tentorium	4-5mm	A+N	100-110
Vascular	4-5mm	A	100-110

The size range of calcifications was from 4 mm to 10 mm with most calcifiactions having a average size of 4 mm to 5 mm. The largest calcified area was choroid plexus calcification having average dimension of 8 mm to 10 mm.

Regarding patterns of calcification, nodular calcification was exclusively found in pineal gland and amorphous calcification in vessels. Other areas had both nodular and amorphous calcifications. Overall nodular calcification was found in most of the locations.

The density range of calcification in our study was from 90 HU to 150HU, with the highest density was noted in pineal and choroid plexus calcifications ranging from 120HU to 150 HU.

It was noted that with increase in age , frequency of pineal, choroid, falx and vascular calcifications increased, but no such association was noted with basal ganglia and tentorial calcifications.

Table 5. shows the most notable characteristic of the calcifications

	Location	Age Group	Sex
Most calcified Area	Pineal	41-50	Males
Max. Nodular	Pineal	41-50	Males
Max. Amorphous	Choroid Plexus	41-50	Females
Highest Density	Pineal	41-50	Males
Max. Size	Choroid Plexus	41-50	Females

The most calcified area was in pineal gland between the age group of 41-50yrs in males. Maximum nodular calcification and highest density of the calcification were also in pineal gland in the same group and sex. Maximum amorphous calcification was

in choroid plexus between the age group 41-50 in females. Maximum size of the calcification was also in choroid plexus in the same age group and sex.

Discussion

Calcification in the brain can occur both in physiological and pathological conditions. Normal physiological calcifications are detected incidentally in patients who undergo CT imaging of brain for evaluation of any acute or chronic neurological disorders .[6] This is the most common finding in CT scan of brain and knowledge of the same with respect to commonest site, location , size , number and patterns is vital in neuroimaging studies.

The documented sites of physiological calcifications are the pineal gland, choroid plexi, falx ,habenula, tentorium cerebella, petro-clinoid and interclinoid ligaments, pacchonian bodies, basal ganglia, cerebellum , pituitary gland and vascular calcifications[3]

The cause of physiological calcifications is not exactly known. It is proposed to be a multifactorial process including constitutional background like age,gender,race,nutrion and the process of ageing [7]

In our study the highest number of calcification was found in pineal gland. Sex and age group wise it was highest in males from 41 to 50 years.

It was followed by choroid plexus ,habenula, vascular, falx and basal ganglia.

The least number of calcifications was seen in tentorium cerebelli .

We found calcification in 72.4% in pineal gland and 68.2% in choroid plexus.

Similar findings were noted by Daghighi et al in their study who observed 71% of their studied population had pineal gland calcifications while 66.2% had choroid plexus calcifications [8]

In the study of Kwak et al. [5] in Japan the incidence of pineal gland calcification was the most common intracranial physiological calcification.

The size of physiological pineal calcification is usually 3-5 mm. If it is greater than 1 cm then pathology like pinealoma, teratoma AVM , craniopharyngioma to name a few of calcified tumors that occurs in pineal gland should be looked for[9]. In our study the average size of pineal gland calcifications were 5 mm to 6 mm.

Choroid plexus calcifications occurs most commonly in the glomus within the atrium of lateral ventricles, near foramen of Monro, tela choroidea of third ventricles, roof of fourth ventricle and along the foramen of Luschaka[10] .

In this study we found choroid plexus calcification ranged from 20 years to 80 years of age in the glomus of both lateral ventricles and was notably symmetrical in most patients. Frequency of calcification also increased with age .

In this study we found 70.3% subjects had calcifications in both pineal and choroid plexus (72.4% in pineal and 68.2% in choroid plexus), it was the highest among any two areas of combined calcifications.

Choroid plexus calcification is known to be associated with pineal gland calcification[11]

The frequency of pineal gland and choroid plexus calcifications show a steady increase in both sex groups[9] a finding similar in this study.

The incidence of normal pineal gland and choroid plexus calclfications were higher in males than females by 13.1% and 6.0%respectively [12] which was also noted in our study.

After pineal and choroid next common area to be calcified in this study was habenular calcification. In our study we observed that habenula calcification steadily increased in frequency after thirty years of age. Physiologic calcifications of the dura are very common in older age groups and are usually located in the falx or the tentorium [5] Presence of dural calcifications in children or young adults should raise the suspicion of underlying pathology.

A less common area of calcification noted in this study was bilateral basal ganglia. Various terms have been used to describe calcifications of basal ganglia including, basal ganglia calcification(s), Fahr syndrome, intracranial calcification, pallidal calcification, and striopallidodentatecalcinosis [13]

The review of literature shows, now, that there is no definite pathogenesis of basal ganglia calcifications [14].

Abnormal basal ganglia calcifications are associated with many conditions with calcium-phosphorus metabolism being the most common. [6, 13]. Basal ganglia calcifications incidence of 1.04% in our studied population is within the known range of 0.4-2.0% [1,10]. Presence of basal-ganglia calcifications in patients of less than 30 years of age should prompt careful clinical evaluation to rule out possibilities like hyper or hypoparathyroidism, Fahr's diasease , infections like cytomegalovirus or toxoplasmosis ,genetic disorders, birth asphyxia, radiation, lead and carbon monoxide poisoning and among others .

In our study basal ganglia calcifications were noted in 71 to 80 years of age group with male predominance.

Vascular calcification and falx cerebri also increased with age and was most commonly found in 71 to 80 year-old subjects. It was seen that pineal, habenular, and choroid plexus calcifications also increased at older ages. Similar findings were reported by Kendall and Cavangh [15] in their study.

Conclusion:

We conclude that normal physiological calcifications in CT have a documented location where they usually occur. Certain parameters like age and sex distribution ,location in the brain, patterns, size , density follows an order unlike pathological brain calcifications. A thorough knowledge of the same is essential for the both the radiologist and practising physician for accurate evaluation of brain in neuroimaging modalities like CT.

REFERENCE

1. Weins J, Stenbeg A (2003) Skull. In: Freyschmidt J, Brossman J, Weins J ed. Borderlands of normal and early pathological findings in skeletal radiography. Thieme, New York, pp. 380–386. | 2. Bennet JC, Mafely RH, Steinbach HL (1959) The significance of bilateral basal ganglia calcification. Radiology, 72: 368–378. | 3. Sutton D (2003) Head and neck; CNS; recent technical advances. In: Sutton D ed. Textbook of radiology and imaging. Churchill Livingstone, New York, pp. 1466. | 4. Weins J, Stenbeg A (2003) Skull. In: Freyschmidt J, Brossman J, Weins J ed. Borderlands of normal and early pathological findings in skeletal radiography. Thieme, New York, pp. 380–386 | 5. Kwak R, Takeuchi F, Ito S, Kadoya S (1988) Intracranial physiological calcification on computed tomography (Part 1): Calcification of the pineal region. No To Shinkei, 40: 569–574. | 6. Verulashvili, I. V., Glonti, L. S. H., Miminoshvili, D. K., et al. (2006). Basal ganglia calcification: clinicalmanifestations and diagnostic evaluation. Georgian Med News. 140, 39-43. | 7. Guja, C., Dumitrascu, A., Boscaiu, V., et al. (2005). Choroid plexus –Pineal gland Correlations, MedicalAnthropology Computed Tomography Studies, Intracranial Physiological Calcifications.ActaEndocrinologica(BUC), 1 (1), 1-18. | 8. Daghighi, M. H., Rezaei, V., Zarritan, S., et al. (2007). Intracranial physiological calcifications in adults oncomputed tomography inTabriz, Iran. Folia Morph (Warsz), 66 (2), 115-9. | 9. Vigh, B., Szel, A., Debreceni, K., et al. (1998). Comparative histiology of pineal calcification. HistolHistopathol, 13 (3), 851-70. | 10. Dahnert, W. (2003). Radiology Review M anuel, WoltersKlumer/Lippincort, Phildelphia, 6th ed, 237. | 11. Doyle, A. J. & Anderson, G. D. (2006). Phyiological calcifications of pineal gland in children on computedtomography: prevalence, observer reliability and association with choroid plexus calcification. AcadRadiol, 13(7), 82, 2-6. http://dx.doi.org/10.1016/j.acra.2006.04.004 | 12. Admassie, D. &Mekonne, A. (2009).Incidence of normal pineal and choroid plexus calcifications on brain CT(Computerized tomography) at TikurAnbessa Teaching Hospital, Addis Ababa, Ethiopia.Ethiop.Med J, 47 (1),55-60. | 13. Basak, R. C. (2009). A case report of basal ganglia calcification-A rare findings of Hypoparathtroidism.QMJ.24, 220-224. | 14. Rossi, M., Morena, M., &Zanardi, M. (1993).Calcification of basal ganglia and Fahr disease.a report of twoclinical cases and Review of literature. RecentiProg Med, 84 (3), 192-8. | 15. Kendall B, Cavanagh N (1986) Intracranial calcificationin pediatric computed tomography. Neuroradiology,28: 324–330. |