VOLUME-6 | ISSUE-2 | FEBRUARY-2017 • ISSN No 2277 - 8179 | IF : 3.508 | IC Value : 78.46

# Integrated management of adhesive capsulitis [USG guided supra-scapular nerve block combined with continuous passive motion CPM]: physiatrist approach

Orthopaedic

**KEYWORDS:** ADHESIVE CAPSULITIS, SUPRA SCAPULAR NERVE BLOCK, USG, CPM

| | |
|---|---|
| **DR Nitesh Gonnade** | Senior Resident AIIMS Jodhpur, PMR department. |
| **Dr Vaibhav Lohande** | Senior Resident AIIMS Jodhpur, PMR department. |
| **Dr Neeraj Mehata** | Senior Resident AIIMS Jodhpur, RADIOLOGY department. |
| **Dr Pushpinder Khera** | Associate Professor , RADIOLOGY department |
| **Parul Mathur** | BPT, Physiotherapist In AIIMS Jodhpur |
| **Dr Shailendra Dwivedi** | PhD Post-doctoral Fellow |

## ABSTRACT

**Objective:** To evaluate the clinical effectiveness USG guided supra-scapular nerve block combined with continuous passive motion CPM in management of chronic adhesive capsulitis.

**Design:** A single-blinded, nonrandomized, non-controlled hospital based prospective interventional study. It was conducted in Physical medicine and rehabilitation department of All India Institute of Medical sciences, Jodhpur, India. Eighty patients {54 females and 26 males, mean age 54.04 ± 2.07years} with chronic adhesive capsulitis enrolled in study. Interventions in form of ultrasound guided suprascapular nerve block followed by 25 sessions of continuous passive motions (CPM) guided technique. Main Outcome Measures were numerical rating scale (NRS) and ROM assessed at baseline, immediate post injection, 2wk, 4wk, 12wk and 24wks. Disability and activity limitation was assessed by shoulder pain disability index (SPADI) at baseline, 4wk, 12wks and 24wks.

**Results:** NRS score, Active and passive ROM changes and SPADI score changes from baseline were statistically significant for each group.

**Conclusion:** Suprascapular nerve block is a safe and extremely effective procedure in chronic adhesive capsulitis. Integrated approach of USG guided accurate block, followed by institution based supervised Continuous passive motion showed improved functional status and pain levels in patients with adhesive capsulitis.

**INTRODUCTION:**

Adhesive capsulitis is common musculoskeletal condition routinely encountered in rehabilitation clinic for alleviation of pain, functional improvement and enhancement of quality of life. In 1872 Duplay described the condition as 'periarthrite scapulo–humerale [1]. Codman in 1934 first coined the term 'Frozen shoulder' for gradual restrictions of shoulder movement[2]. Followed by Neviaser in 1945 given term 'adhesive capsulitis' who found that actual dysfunction lies in capsule of shoulder joint[3].

Adhesive capsulitis is characterized by painful and progressive loss of both active and passive shoulder range of motion commonly affecting flexion, abduction, and external rotation which ultimately results in a loss of function and creating difficulties in daily activities of life[4].

Adhesive capsulitis is commonly affecting adults between 40-60 yrs with predominance of women four to five times more with prevalence rate of approximately 2-5% [5-7]. It is characterized by 3 phases. A painful phase varies between 3 -8 months followed by adhesive phase lasts for 4-6 months and phase of resolution return to normal motion (5-24months) [8] Although the exact cause of this pathology is matter of debate, it is classified as idiopathic and secondary .idiopathic occurs without any specific cause. Diabetes (Both Type I and Type II) , local shoulder problems including tendinitis, rotator cuff injury , surgery stroke, Parkinson disease, cardiac and pulmonary diseases are important contributory risk factor for development of secondary adhesive capsulitis [9-11]

Diagnosis is entirely based on clinical examination with history of insidious onset dull aching diffuse pain with gradual progressive loss of both active and passive glenohumeral movements. The movement that is most severely affected is external rotation of the shoulder.[8, 12-13]

Several different therapeutic modalities have been used for the purpose of alleviation of pain and acceleration of recovery. Management of adhesive capsulitis can be either conservative or surgical. Conservative treatment includes non-steroidal anti-inflammatory drugs (NSAIDs),hot-cold application, transcutaneous electrical nerve stimulation (TENS),ultrasound therapy (UST), acupuncture, low power laser ,[14], Intra-articular injections[15]and exercises including active and passive Range of Motion, stretching manipulation , patients education and home exercise program[16] .Surgical procedures such as manipulation, arthroscopy guided capsular distension, arthroscopic or open capsular release [17]. Surgical intervention has limitations particularly in older patients with co morbidities and many will never ready for it.

Suprascapular nerve has both sensory and motor supply. 70% of shoulder joint including both anterior and posterior capsule, acromio clavicular joint supplied by sensory fibers of suprascapular nerve. It gives motor branch to supraspinatus and infraspinatus muscle.[18]

Suprascapular nerve block is proved safe and effective treatment for adhesive capsulitis of shoulder which can be perform under Fluoroscopy, fluoroscopy surplus with nerve stimulation[19], CT[20] and ultrasound guided[21]. Both fluoroscopy and CT have risk of radiation exposure Ultrasound is less expensive, easily available and free of radiation.

Continuous passive motion (CPM) a mechanical stretching devices is well established method of physical exercise for preventing joint stiffness and of reliving it with goal to maintain or restore range of motion of joint. In hospital setting or in home based rehabilitation It provide frequent, consistent and controlled joint mobilization,[22]

The Shoulder Pain and Disability Index (SPADI) is 13 items self administered instrument with two subscales 5-item pain and an 8-item disability subscale to measure current shoulder pain and disability in and outpatient setting[23].

The objective of this study was to assess effectiveness of integrated approach consisted of ultrasound guided suprascapular nerve block

combined with continuous passive motion and to look for the speed of pain relief, and improvement in range of motion of the shoulder. We have used ultrasound guided approach to improve efficacy of suprascapular nerve block and to avoid complication like pneumothroax and neurovascular injury.

Many studies available for treatment of chronic shoulder pain by suprascapular nerve block and effect of exercise therapy separately. Evidence for integrated treatment approach consisted of both suprascapular nerve block and continuous passive motion (CPM) is not available so we conducted this study.

**MATERIAL AND METHOD:**

It was nonrandomized noncontrolled prospective hospital based interventional study conducted in the Department of Physical Medicine and Rehabilitation at All India Institutes of Medical Sciences (AIIMS) Jodhpur, India after the institutional ethics committee approval. We recruited consecutive patients who attending pain and rehabilitation clinic with age 40 years or older, Shoulder pain more than 3 month non responsive to conservative treatment (NSAIDS, heat and cold application ,TENS and conventional exercises), global restriction of range of motion (loss of external rotation, abduction, and flexion) and who want to avoid invasive surgical interventions.Patients with Fractures ,dislocation , tumors of the upper extremity, neurological disorders causing muscle weakness in the shoulder, Insulin dependent, diabetes mellitus, allergic to injecting agents, severe chronic airways disease, Cardiac failure, Pregnancy were excluded.

The patients who were unable to complete 25 session of continuous passive motion in consecutive visits were also excluded from the analysis. A total of 92 patients were initially enrolled, who fulfilled the above inclusion-exclusion criteria were considered for ultrasound - guided suprascapular nerve block followed by 25 session of continuous passive motion exercise protocol. All the patients underwent complete work-up including clinical neuromuscular examination , range of motion (abduction, flexion ,internal and external Rotation ,) was measured with a goniometer, with all routine investigations for ruling out diabetes, any infective pathologies abnormalities. Antero-posterior (AP) and lateral view shoulder roentogram were done in all patients to rule out any bony abnormalities. After written informed consent ultrasound guided suprascapular nerve blocks were performed by same physician as a day care procedure and discharged on same day.

**INTERVENTION:**

Patient was advised to sit with the shoulder in neutral position. The physician was stood behind the patient. The scapular spine, coracoid process and acromium are used as anatomical landmark .After aseptic precaution using ultrasound machine (SIEMENS ACUSON X300) with linear ultrasound probe with 8 to 13 MHz placed parallel to the scapular spine to visualize it. Then moved the transducer cephalad direction supraspinatus, trapezius and supraspinatus fossa was identified now moved laterally slowly in transverse plane to locate the suprascapular notch ,suprascapular nerve was appeared as a round hyperechoic structure (approximate diameter of 25mm) under the transverse scapular ligament in the scapular notch. Color doppler mode was started to visualize suprascapular artery to avoid vascular injury. After subcutaneous injection of 1mL 1% lidocaine one and half inch 23-gauge, spinal needle (B. Braun) was inserted along in plane approach from medial aspect of the ultrasound probe. On ultrasound imaging as needle was reached in proximity of suprascapular nerve in the suprascapular notch mixture of bupivacaine 0.5% (5-6 ml) and methylprednisolone (40mgs) was injected perineurally (see Fig.1).

After procedure injected site was compressed for 1min to avoid blood spotting and observed patients for 1 hr to detect any post procedure complication. After procedure pain was assessed with numerical rating scale (NRS).

Post injection analgesia was achieved with cold compression for 2 days and paracetamol as needed.

Post intervention on third day Continuous passive motion (RIMEC Fisiotek HP2 ) was started , a daily for 1 hour 5 days per week total 25 session during a period of 5 weeks which includes mainly focus on passive abduction (Fig 2a),flexion (Fig 2b), internal (Fig 3a) and external rotation (Fig 3b) initially up to tolerable range then gradually progressed to terminal range of motion under the supervision of a physiotherapist[24].

In addition all patients were also advised home exercise program consisting of active and passive range of motion and pendulum exercises to be performed every day.

**OUTCOME ASSESSMENT:**

The outcome of ultrasound guided supra scapular nerve block combined with continuous passive motion was assessed for pain intensity by numerical rating scale (NRS) assessed at baseline , immediate post injection,2wk,4wk,12wk and 24wks. , Both active and passive range of motion (ROM) by goniometer at baseline 2wk, 4wk, 12wk, and 24wks. Improvement in disability and activity limitation was assessed by shoulder pain disability index (SPADI) at baseline 4wk, 12wks and 24wks. Assessments were done by a physician who was blinded to the patient's participation in study.

**STATISTICAL ANALYSIS:**

Data were summarized in tables and represented with 95%confidence Interval with p-value. The repeated measures of analysis of variance ANOVA were applied to assess statistical significance for NRS score, SPADI and range of motion (active and passive both). The Tukey's multiple comparison tests were applied to assess statistical significance between groups. All the analysis was carried out by using SPSS 21.0 and Graph Pad Prism (version 5.0). The P value < 0.05 was considered as statistically significant.

**RESULTS:**

Initially 91 patients were recruited 11 patients missed follow up so their data omitted from analysis. Only 80 patients (54 females and 26 males, mean age 54.04 ± 2.07years) who had completed post injections 25 sessions of CPM and followed up were included in statistical analysis. In patients 51 had right shoulder and 29 had left shoulder involvement.

TABLE 1 the NRS score was assessed in the patients who were attending the OPDs and their weekly follow up were compared from base line i.e.0 week to 2,4,12 and 24 week. The table 1 represent that change in pain score after intervention, the pain was improved gradually over time period and it was found significant among the groups and between the groups ($p<0.0001$). The score was compared among the patients and it was significant in second, fourth, twelfth and twenty forth week from the 0 week. However, changes were found to be ineffective i.e. statistically not significant (95% 0.3685- 0.1935; $p>0.05$) between 2 to 4 weeks.

Table 2 summarizes active and passive range of motion of shoulder in all plane. After the injection, all the patients were assessed for both active and passive range of motions in all plane .active flexion ,abduction and external rotation were improved statistically gradually over period of time except between 12 week to 24 weeks active abduction was non significant. Passive flexion .abduction and external rotation were improved significantly except passive flexion when compared between 4 week to 12 and 24 week and 12 week to 24 week, passive abduction between 4 week to 24 week and 12 week to 24 weeks. Passive external rotation between 12 week to 24 weeks were statistically non significant.

Table 3 summarizes the data from the SPADI. Pain and disability subscales and the total scores are presented The SPADI score including Pain and Disability subscales and total score were evaluated in various weeks before and after interventions. . It was

VOLUME-6 | ISSUE-2 | FEBRUARY-2017 • ISSN No 2277 - 8179 | IF : 3.508 | IC Value : 78.46

noted that Pain SPADI was found statistically significant in all the weeks when compared between groups and from the base line ie. 0 week (95%: 45.40-50.60; 43.39- 48.58; 39.17- 44.36; 8.831-3.638; 6.819-1.625, p<0.0001); however it was statistically non-significant when comparison was made between four to twelfth week (4.609-0.5844).

While disability subscales and total score were clinically and statically significantly improved over period of time when compared between groups baseline.

**DISCCUSION:**

The results of our study showed a clear benefit from physiatrist approach of integrated treatment of adhesive capsulitis consisted of ultrasound guided suprascapular nerve block in suprascapular notch using mixture of bupivacaine 0.5% (5-6 ml) and methylprednisolone (40mgs) with CPM therapy.

There was a statistically and clinically significant reduction in Pain as betterment of NRS score and patient satisfaction by regaining improvement in active and passive range of movement. This benefit was sustained still present at 24 weeks .There were no significant side effects from the injection and follow up CPM which was well tolerated by most of the patients.

There was also an overall significant improvement in disability as measured by the disability subscale of the SPADI.

The results of our study reinforce this concept and are consistent with the results of other studies comparing specific instruments with a generic instrument.

An improvement of 13 points on the SPADI has been shown to represent significant clinical improvement.

There are a number of possible explanations and reasoning given for pain relief from block. There is decrease in central sensitization of dorsal horn nociceptive neurons had been suggested. Alternative "wind down" phenomenon i.e because of a reduction of peripheral nociceptive input also postulated. This leads to reduction of substance P and nerve growth factor in the synovium and blockade afferent C fibers of the glenohumeral joint contribute to the longer term relief.

One of the possible mechanisms for pain relief is due to the direct blockade of nerve fiber supplying supraspinatus muscle and possible "downstream" of local anesthetic medication blockade in infraspinatus muscle also [25-26].

Post intervention each patient assessed for supraspinatus and infraspinatus muscles power, we didn't find any post international complications.

USG is non invasive technique which gives a real time imaging that gives advantage to person who is doing procedure so he can gave block accurately.USG is also cost effective and avoids burden of uncertainty of blind technique. USG over C-arm and CT guide that it does not have risk of radiation. Elecromyography guided near nerve block technique is better than superficial bony landmarks but EMG has limitations as it needle is expensive, lack of direct visualizations plus may require repeated injections[27].

As Adhesive capsulities in more prevalent in DM . Ekim et al studied both rehabilitation approachs. In adhesive capsulities both therapy (continuous passive motion and conventional physical therapy) are useful and routinely practiced. But they found that patients who were on CPM had significant improvement for pain and functional status[28].

**Our study also expressed same result.**

1st literature of CPM was provided by salter in 1970.After evidence of cartilage healing and regeneration in animal studies CPM had entered in human trial (salter et al 1994).IN 2007 Nugent –Derfus et al. introduced CPM as noval approach for orthopedic rehabilitation over conventional methods[24].

In post operative rehabilitation of rotator cuff repair Michael et al had found integrated rehabilitative approach consisted of CPM and conventional rehabilitative had better pain control over physiotherapy alone.

Michael et al. (2005) showed again advantages of the combined treatment protocol (CPM+ physiotherapy) over pain control in postoperative treatment after rotator cuff repair[29].

In our study we used integrated approach USG guided SCN block and 25 sessions of CPM, followed by home based uniform conventional physiotherapy protocol which found significant improvement in pain scores, scapulothoracic movements and disability subscale shoulder disability index which ultimately help to functional capacity of individual.

Our study has limitations in perspective of lack of controlled group, hospital based CPM which is not available in every rehabilitation setup, our unsupervised conventional home based program. We understand Study would have been followed up to 1 year.

In summary, this study provides evidence that USG guided suprascapular nerve block is a safe, effective, inexpensive and well tolerated treatment for patients with adhesive capsulities.

It can be performed in an OPD basis and provides the Physiatrist with an alternative or additional approach to oral drug treatment and intra articular injection. With involvement of CPM in rehabilitation care dedicated attempt made to improve ROM and maintain it in follow ups.



**Fig.2(a). Passive abduction with continuous passive motion**



**Fig 2 (b). passive flexion with continuous passive motion**



**Fig 3 (a). internal rotation with continuous passive motion.**



**Fig 3(b). Passive external rotation with continuous passive**

**motion**

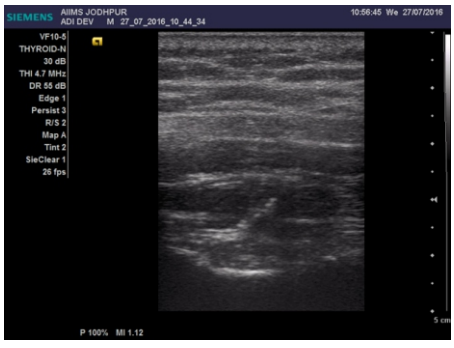


**Fig 1** *ultrasound guided suprascapular block showing suprascapular notch and needle insertion on real-time imaging*

**Table 1: The Pain score (Numerical rating scale) analysis after USG guided suprascapular nerve block with 95% confidence interval**

| Parameter | Time Duration (in Weeks) | 95% CI of | P – Value |
|---|---|---|---|
| NRS | 0 – 2 | (5.682 - 6.243) | 0.0001 |
| | 0 – 4 | (5.594 -6.156) | 0.0001 |
| | 0 – 12 | (5.157 - 5.718) | 0.0001 |
| | 0 – 24 | (4.607 -5.168) | 0.0001 |
| | 2 – 4 | (0.3685 -0.1935) | Ns |
| | 2 – 12 | (0.8060- 0.2440) | 0.0001 |
| | 2 – 24 | (1.356 - 0.7940) | 0.0001 |
| | 4 – 12 | (0.7185 -0.1565) | 0.0001 |
| | 4 – 24 | (1.268 -0.7065) | 0.0001 |
| | 12 – 24 | (0.8310 - 0.2690) | 0.0001 |

p<0.0001, p<0.001, p<0.01, p<0.05 = significant, ns = non-significant

**Table 2: AROM and PROM analysis in all planes after USG guided suprascapular nerve block combined with continuous passive motion CPM**

| Parameter | Time Duration (in Weeks) | | | | | 95% CI, p-Value | | | | | | | | | |
|---|---|---|---|---|---|---|---|---|---|---|---|---|---|---|---|
| | | | | | | 95%CI $P^a$ | 95%CI $P^b$ | 95%CI $P^c$ | 95%CI $P^d$ | 95%CI $P^e$ | 95%CI $P^f$ | 95%CI $P^g$ | 95%CI $P^h$ | 95%CI $P^i$ | 95%CI $P^j$ |
| FL ACTIVE | 0 | 2 | 4 | 12 | 24 | (29.09-23.16) 0.0001 | (52.09-46.16) 0.0001 | (56.46-50.54) 0.0001 | (57.84-51.91) 0.0001 | (25.96-20.04) 0.0001 | (30.34-24.41) 0.0001 | (31.71-25.79) 0.0001 | (7.339-1.411) 0.0001 | (8.714-2.786) 0.0001 | (4.339-1.589) 0.0001 |
| ABD ACTIVE | 0 | 2 | 4 | 12 | 24 | (28.81-21.69) 0.0001 | (50.19-43.06 ) 0.001 | (54.31-47.19) 0.0001 | (55.06-47.94) 0.0001 | (24.94-17.81) 0.0001 | (29.06-21.94) 0.0001 | (29.81-22.69) 0.0001 | (7.686-0.5645 )0.01 | (8.436-1.314) 0.001 | (4.311-2.811) Ns |
| ER ACTIVE | 0 | 2 | 4 | 12 | 24 | (12.73-8.645) 0.0001 | (23.11-19.02) 0.0001 | (28.86-24.77) 0.0001 | (30.98-26.89) 0.0001 | (12.42-8.332) 0.001 | (18.17-14.08 ) 0.0001 | (20.29-16.21) 0.0001 | (7.793-3.707) 0.0001 | (9.918-5.832 )0.0001 | (4.168-0.08237) 0.01 |
| FL PASSIVE | 0 | 2 | 4 | 12 | 24 | (48.08-6.644) 0.001 | (70.96-29.52) 0.0001 | (87.21-45.77) 0.0001 | (75.96-34.52) 0.0001 | (43.59-2.156) 0.01 | (59.84-18.41) 0.0001 | (48.59-7.156) 0.001 | (36.97-4.469) ns | (25.72-15.72 )ns | (9.469-31.97 ) Ns |
| ABD PASSIVE | 0 | 2 | 4 | 12 | 24 | (27.94-18.81) 0.0001 | (49.19-40.06) 0.0001 | (54.44-45.31) 0.0001 | (53.19-44.06) 0.0001 | (25.81, 16.69) 0.0001 | (31.06-21.94 ) 0.0001 | (29.81-20.69) 0.0001 | (9.813-0.6867) 0.01 | (8.563-0.5633) ns | (3.313-5.813) Ns |
| ER PASSIVE | 0 | 2 | 4 | 12 | 24 | (15.07-8.307) 0.0001 | (26.07-19.31) 0.0001 | (32.63-25.87) 0.0001 | (35.07-28.31) 0.0001 | (14.38-7.619) 0.0001 | (20.94-14.18 ) 0.0001 | (23.38-16.62) 0.0001 | (9.943,-3.182 ) 0.0001 | (12.38-5.619 ) 0.0001 | (5.818-0.9435) Ns |

$P^a$ - score comparison of 2 week with base line (0 week)
$P^b$ - score comparison of 4 week with base line (0 week)
$P^c$ - score comparison of 12 week with base line (0 week)
$P^d$ - score comparison of 24 week with base line (0 week)
$P^e$ - score comparison of 4 week with 2 week
$P^f$ - score comparison of 12 week with 2 week
$P^g$ - score comparison of 24 week with 2 week
$P^h$ - score comparison of 12 week with 4 week
$P^i$ - score comparison of 24 week with 4 week
$P^j$ - score comparison of 24 week with 12 week

**Table 3: The SPADI Score (Pain and Disability subscales and Total Scores) analysis after USG guided suprascapular nerve block with 95 % of confidence interval.**

| Parameter | Time Duration (in Weeks) | | | | 95% CI, p-Value | | | | | |
|---|---|---|---|---|---|---|---|---|---|---|
| | | | | | 95%CI $P^a$ | 95%CI $P^b$ | 95%CI $P^c$ | 95%CI $P^d$ | 95%CI $P^e$ | 95%CI $P^f$ |
| Pain SPADI | 0 | 4 | 12 | 24 | (45.40-50.60) 0.0001 | (43.39-48.58) 0.0001 | (39.17-44.36) 0.0001 | (4.609-0.5844) NS | (8.831-3.638) 0.0001 | (6.819-1.625) 0.0001 |
| Disability SPADI | 0 | 4 | 12 | 24 | (41.99-46.13) 0.0001 | (39.52-43.66) 0.0001 | (35.23-39.36) 0.0001 | (4.538-0.4006) 0.0001 | (8.834-4.697) 0.0001 | (6.365-2.228) 0.0001 |
| Total SPADI | 0 | 4 | 12 | 24 | (44.64-47.28) 0.0001 | (42.16-44.80) 0.0001 | (38.07-40.72) 0.0001 | (3.802-1.161) 0.0001 | (7.889-5.247) 0.0001 | (5.407,-2.766 ) 0.0001 |

$P^a$ - score comparison of 4 week with base line (0 week)
$P^b$ - score comparison of 12 week with base line (0 week)
$P^c$ - score comparison of 24 week with base line (0 week)
$P^d$ - score comparison of 12 week with 4 week
$P^e$ - score comparison of 24 week with 4 week
$P^f$ - score comparison of 24week with12we

**REFERENCE:**

1. Duplay ES. De la périarthrite scapulo-huméral et des raideurs qui en sont la conséquence. Arch Gén Méd 1872; 20: 513–542
2. Codman E. Rupture of the supraspinatus tendon and other lesions in or about the subacromial bursa. In: The shoulder. Boston: Thomas Todd;1934:216-24.
3. Neviaser J. Adhesive capsulitis of the shoulder: a study of the pathological findings in periarthritis of the shoulder. J Bone Joint Surg1945;27:211-22.
4. Sheridan MA, Hannafin JA: Upper extremity: Emphasis on frozen shoulder. Orthop Clin North Am2006;37:531Y9
5. Favejee MM, Huisstede BM, Koes BW: Frozen shoulder: The effectiveness of conservative and surgical interventions Systematic review. Br J Sports Med 2011;45:49Y56
6. Walmsley S, Osmotherly PG, Rivett DA: Movement and pain patterns in early stage primary/idiopathic adhesive capsulitis: A factor analysis. Physiotherapy 2014;100:336Y43
7. Maund E, Craig D, Suekarran S, et al: Management of frozen shoulder: A systematic review and cost effectiveness analysis. Health Technol Assess 2012; 16:1Y264
8. Nicholas Shah and Mark Lewis, Shoulder adhesive capsulitis: systematic review of randomised trials using multiple corticosteroid injections British Journal of General Practice, August 2007
9. Wolf, J. M. & Green, A. Influence of comorbidity on self-assessment instrument scores of patients with idiopathic adhesive capsulitis. J Bone Joint Surg Am. 2002;84-A:1167-1173.
10. Arkkila, P. E., Kantola, I. M., Viikari, J. S. & Ronnemaa, T. Shoulder capsulitis in type I and II diabetic patients: association with diabetic complications and related diseases. Ann Rheum Dis. 1996;55:907-914
11. Dias R, Cutts S, Massoud S: Frozen shoulder. BMJ 2005;331:1453Y6
12. Siegel LB,Cohen NJ,Gall EPG.Adhesive capsulitis: a sticky issue. AmFam Physician 1999; 59(7): 1843–1850.
13. Codman EA. The shoulder. Boston: Thomas Told, 1934.
14. Phil page, adhesive capsulitis: use the evidence to integrate your interventions North American Journal of Sports Physical Therapy | Volume 5, Number 4 | December 2010

VOLUME-6 | ISSUE-2 | FEBRUARY-2017 • ISSN No 2277 - 8179 | IF : 3.508 | IC Value : 78.46


15. Bucbinder R, Gren S, Youd JM, Johnston RV, Cumston M. Arthrographic distension for adhesive capsulitis (frozen shoulder). Cochrane Database Syst Rev 2008;23: CD007005.
16. Kelley MJ, McClure PW, Leggin BG. Frozen shoulder: evidence and a proposed model guiding rehabilitation. J Orthop Sports Phys Ther 2009;39:135-48.
17. Akgöl I, Canbulut N, Çelik D, Demirhan M, Seyahi A. Omuz. In: Berker N, Canbulut N, Demirhan M, editors. Omuz-dirsek-diz-ayak bile¤i rehabilitasyon protokolleri. 1th ed. Vol 1. Ankara: Nobel T›p Kitabevleri; 2009. p. 51-7.
18. E M Shanahan, M Ahern, et al Suprascapular nerve block (using bupivacaine and methylprednisolone acetate) in chronic shoulder pain Ann Rheum Dis 2003;62:400–406
19. Shah RV, Racz GB. Pulsed mode radiofrequency lesioning of the suprascapular nerve for the treatment of chronic shoulder pain. Pain Physician 2003; 6:503-506.
20. Schneider-Kolsky ME, Pike J, Connell DA. CT guided suprascapular nerve blocks: A pilot study. Skeletal Radiol 2004; 33: 277-282.
21. Eichenberger U, Greher M, Curatolo M. Ultrasound in interventional pain management. Tec Reg Anesth Pain Med 2006; 8:171-178
22. Hayes, Inc. Medical Technology Directory. Continuous Passive Motion for the Treatment of Joint Contractures of the Extremities. Hayes Inc.: Lansdale, PA: Updated March 2013.
23. Williams JW Jr., Holleman DR Jr., Simel DL: Measuring shoulder function with the Shoulder Pain and Disability Index. J Rheumatol 1995; 22 (4); 727-732
24. Umit Dundar, Hasan Toktas Continuous passive motion provides good pain control in patients with adhesive capsulitis Int J Rehabil Res 32 (3), 193-198. 9 2009.
25. Woolf CJ. Somatic pain-pathogenesis and prevention. Br J Anaesth 1995;75:169–76.
26. Lewis RN. The use of combined suprascapular and circumflex (articular branches) nerve blocks in the management of chronic arthritis of the shoulder joint. Eur Acad Anaesthesiol 1999;16:37–41
27. Young Lae Moon, MD; Jeong-Hoon Kang, The Effectiveness of Ultrasonography-guided Suprascapular Nerve Block for Perishoulder Pain Venkat Gorthi, MD Orthopedics April 2010 - Volume 33 • Issue 4
28. Ekim aa1, inal ee2Continuous passive motion in adhesive capsulitis patients with diabetes mellitus: a randomized controlled trial. j back musculoskeletal rehabil. 2016 mar 18. 29].Z Orthop Ihre Grenzgeb. 2005 Jul-Aug;143(4):438-45. [Efficiency of a postoperative treatment after rotator cuff repair with a continuous passive motion device (CPM)]. Michael JW1.