Volume : 5 | Issue : 12 | December-2016 • ISSN No 2277 - 8179 | IF : 3.508 | IC Value : 78.46

Original Research Paper

Intestinal Schistosomiasis – an incidental finding in a life threatening scenario / A case report

Microbiology

KEYWORDS: Schistosoma, diverticulosis, ova, massive bleeding

Dr Deepthi Nair*	Department of Medical Microbiology, Al-Amiri Hospital, Kuwait
Dr Abhijit M Sapkal	Department of Histopathology, Al-Amiri Hospital, Kuwait
Dr Omar S Jarallah	Department of General Surgery, Al-Amiri Hospital, Kuwait
Dr Fatema Mothaffer	HOD, Department of Histopathology, Al-Amiri Hospital, Kuwait
Dr Khaleefa Al Benwan	HOD, Department of Medical Microbiology, Al-Amiri Hospital, Kuwait

ABSTRACT

Schistosomiasis is a water-borne infection caused by trematode helminths. Intestinal schistosomiasis is a chronic form of the debilitating infection, with symptoms varying from mild to severe, depending on the schistosomal species involved and on the pathological changes induced by the deposition of schistosoma ova. The species of schistosomes causing intestinal schistosomiasis are *Schistosoma (S) mansoni, S. japonicum, S.mekongi* and *S. intercalatum.* This case study discusses a patient who was admitted with massive lower gastrointestinal bleed and was diagnosed with extensive diverticular disease of the colon. Histopathology examination of colon biopsy post-colectomy revealed diverticulosis and the presence of numerous schistosoma ova. The morphology of the ova pointed to infection with S.japonicum.

Case Report

A 43 year old Philippino lady was admitted with complaints of sharp epigastric pain, repeated vomiting and passage of fresh blood per rectum of 1 day duration. There was no fever, headache, haematemesis, chest pain, palpitation or shortness of breath.

The lady was admitted a year back as a case of upper gastrointestinal (GI) bleed. Upper GI scope then showed grade 2 oesophagitis and antral gastritis with pre-pyloric erosion. The patient was transfused with four units of packed red cells and was discharged on medications for gastritis. The lady worked as a housemaid. She denied any history of gastrointestinal malignancy in the family and denied intake of alcohol or non-steroidal anti-inflammatory drugs. She was a diabetic (type 2 diabetes mellitus) and was on diet control alone. There was no history of piles or any bleeding disorder. She gave no history of weight loss or loss of appetite. Her periods were regular. There was no history of travel for the past 2 years.

On physical examination in the emergency room, the patient was alert, conscious and oriented. She was afebrile. Her pulse was 105/min, BP 135/70 mmHg, respiratory rate 18/min and oxygen saturation 100%. Her chest was clear and the nervous system and the cardiovascular system were normal. Abdomen was soft and lax. Epigastric tenderness was present.

Per-rectal examination revealed fresh bleeding along with black tarry stool, but no mass was evident.

Laboratory investigations showed Haemoglobin 126g/L, WBC 10.3× 10^9 /L, absolute neutrophil count 7.4 ×10^9 /L, absolute eosinophil count 0.18 x 10^9 /L RBC 4.09 × 10^{12} /L , Platelet count 323 × 10^9 /L, ESR 31mm/hr, S. PCT 0.5ng/ml, CRP 4.1mg/L , PCV 0.37L/L, blood urea 5.8 mmol/L , S.creatinine 70 μmol/L, S. glucose 7.8 mmol/L. The liver function tests were normal. Chest X-ray was unremarkable, with no air under the diaphragm. CT abdomen was unremarkable, with no organomegaly or free fluid. Tests for Hepatitis B, Hepatitis C and HIV were negative.

During the patient's stay in the hospital, she underwent 3 episodes of massive lower GI bleed, the first one about 4 hours after admission, when following the bleed, she developed tachycardia (heart rate 130-140/min), hypotension and pre-syncope with a drop in haemoglobin level from 126g/L to 83 g /L. WBC count rose to 11.9 × 10^9 /L.

She was immediately resuscitated and transfused with packed RBCs. An urgent upper GI endoscopy done showed mild duodenitis and small hiatal hernia.

When the patient was stable, a CT angiogram was arranged which showed no active bleeding along the whole course of the small and large bowel.

On day 2, a lower GI colonoscopy done showed remarkable findings: multiple diverticulae in the right and left colon, more on the right. The whole colonic lumen was filled with maroon coloured blood and fresh blood was noticed in the distal 15 cm of the terminal ileum which probably was a retrograde reflux of blood from the descending colon.

On day 4 of admission, the patient suffered her second episode of massive bleeding per rectum following which she deteriorated haemodynamically. Her haemoglobin dropped from 107g/L to 72g/L. She was resuscitated and transfused with 3 units of packed RBCs and Fresh Frozen Plasma . She responded clinically and the haemoglobin rose to 103g/L.

The patient remained stable for the next 3 days during which she underwent a nuclear study RBC scan, which showed no evidence of active bleeding, and a Meckel scan, which showed no evidence of active ectopic gastric mucosa or Meckel's diverticulum. Colonoscopy was repeated which confirmed the findings of diverticulosis observed in the first colonoscopy study – diffuse colonic bleeding, scattered bilateral large colonic diverticulae oozing fresh blood and blood clots mostly in the rectosigmoid region.

On day 8 of admission, the patient suffered her third episode of massive lower GI bleed with a drop in haemoglobin to 57g/L. This time, after resuscitation, she was rushed to the operation theatre where she underwent a total colectomy with end ileostomy. The operative findings were as follows : the entire colon was filled with blood and there were multiple diverticulae in the right and left colon. Small bowel looked normal, and no Meckel's diverticulum was identified.

The patient improved post-operatively, with no further bleeding. Histopathology examination done using H&E stain showed diverticulosis of the colon and presence of numerous schistosome ova (Figure 1). Oval ova with a lateral knob pointed to infection with

Volume : 5 | Issue : 12 | December-2016 • ISSN No 2277 - 8179 | IF : 3.508 | IC Value : 78.46

Schistosoma japonicum (Figure 2a & 2b). Schistosome ova were absent in repeated samples of stool and urine taken for direct microscopy. Serology done using indirect haemagglutination antibody test for schistosomal antibodies was negative. PCR to detect schistosome DNA was not available. Ziehl-Neelsen stain for schistosome ova was positive (Figure 3).

The post-operative course was uneventful, except for mild emesis initially. The patient was treated with 3 doses of Praziquantel 20 mg/kg body weight for 1 day and advised another dosage 2 weeks later. At the time of discharge on the 19th postoperative day, the patient was clinically stable with no further bleeding. Since the patient decided to travel back to her country, she was advised further follow-ups in her country.

Discussion

Schistosomiasis due to S. japonicum is endemic in the Philippines [1]. The inflammatory changes in the intestine produced by S.japonicum are often severe due to the large number of eggs produced by this species, about 3000 eggs/day [2].

Irreversible pathological changes induced by schistosomal eggs leading to granulomas and fibrosis are a common finding in chronic intestinal schistosomiasis [3]. In our case, these changes were conspicuous by their absence in the colon, in spite of the presence of numerous ova. It is not clear whether the immunosuppressed diabetic state of the patient could have led to the absence of the inflammatory changes in the intestine. The modulation of host reaction to eggs is greatly dependant on the cell mediated immunity of the host, especially in infection with Schistosoma japonicum [4]. The remarkable finding in this case was the presence of the multiple diverticulae in the right and left colon, which could probably be due to the long standing pressure effects of schistosoma ova.

Direct microscopy of repeated urine and stool samples were negative. This can be explained by the fact that direct stool examination is not a sensitive test for intestinal schistosomiasis which is a chronic form of the disease. Antibodies may be absent in certain cases of chronic active infection which explains the negative result in indirect haemagglutination test.

Intestinal schistosomiasis in S. japonicum infection may also involve the stomach , with gastric bleeding and pyloric obstruction [5]. A similar involvement was seen in our case, when upper GI endoscopy revealed grade 2 oesophagitis and antral gastritis in the previous admission.

Earlier, cases of diverticulae in the urinary bladder of patients with urinary schistosomiasis have been reported[6]. But in our experience, this is probably the first reported case of intestinal schistosomiasis associated with extensive diverticular disease of the colon accompanied by massive bleeding.

Praziquantel is the drug of choice in schistosomiasis , although its efficacy in chronic schistosomiasis is doubtful [7]. Patients with severe intestinal bleeding as in our case need surgical intervention.

Intestinal schistosomiasis is one of the most widespread parasitic infections in tropical and subtropical countries, with potentially serious complications which are preventable if diagnosed early [8]. Mortality and morbidity caused by schistosomal infections are serious public health concerns in developing countries. In endemic regions with high prevalence of the disease, active screening for schistosomal ova with mass deworming and health education for the community are essential.

Figure 1 Colonic mucosa with diverticulosis & numerous schistosoma ova in mucosa and submucosa

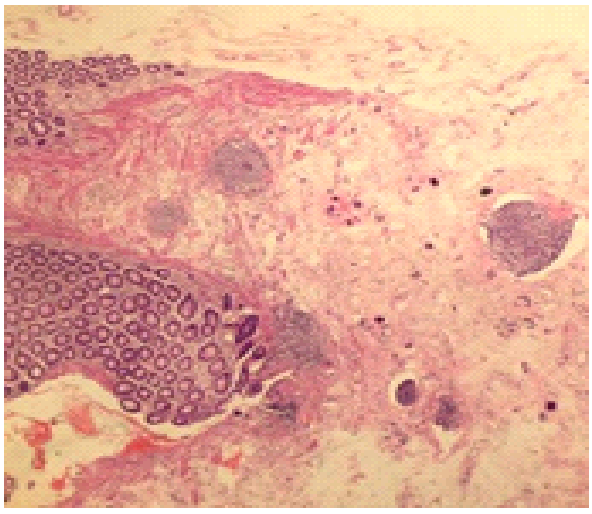

Figure 2 a & 2b Colonic submucosa with schistosoma eggs (a typical ova with lateral knob seen, a few eggs are calcified)

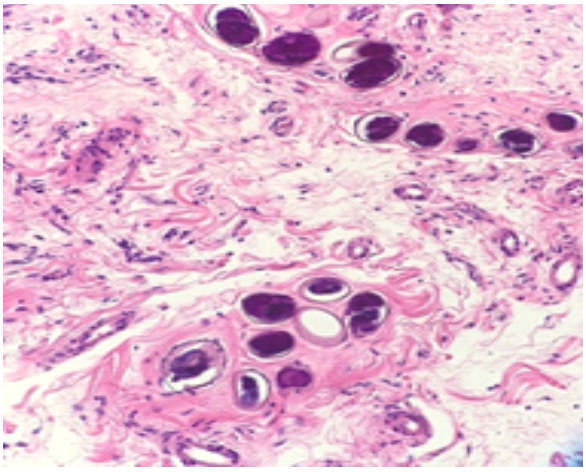

2a

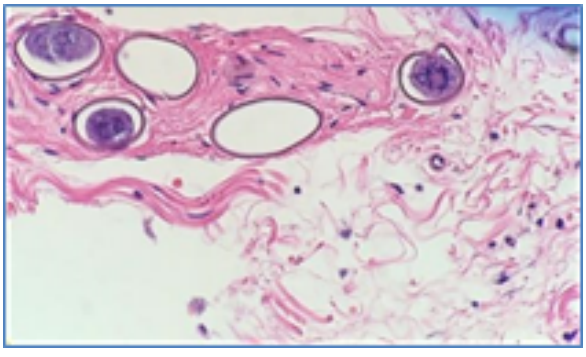

2b

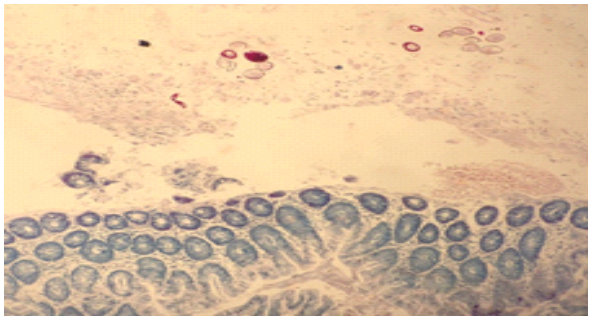

Figure 3 Schistosoma eggs positive for Ziehl-Neelsen stain

References

1. Schistosomiasis, Fact Sheet No.115; February 2016 . World Health Organisation. Available at http://www.who.intmediacentrefactsheets/fs115/en/. Accessed: Nov8 ,2016
2. Winn, Allen, Janda, Koneman,et al : Trematodes .Koneman's Color Atlas and Textbook of Diagnostic Microbiology 6th edition 2006 chapter 22: 1288-90
3. Mandell G L, Bennett J E, Dolin R: Trematodes. Principles and Practice of Infectious Diseases 6th edition 2005 ; 287 : 3276 -3281
4. CheeverAW : Schistosoma japonicum : the pathology of experimental infection. Exp Parasitol. 1985 Feb ; 59 (1):1-11
5. Shadab Hussain Ahmed : Schistosomiasis : Background, Pathophysiology, Etiology – emedicine,Medscape.com/article/228392 – overview 2015
6. Christiano M, Gomes, Marcelo Hisano et al :Urological manifestations of chronic schistosomal myeloradiculopathy. BJU International, 2005 Volume 96, Issue 6, 853-856
7. Doenhoff MJ, Cioli D, Utzinger J . Praziquantel: mechanisms of action, resistance and new derivatives for schistosomiasis. Curr Opin Infect Dis 21(6):659 – 67(2008)
8. Gryseels B, Polman, K., Clerinx, J. & Kestens, L. Human schistosomiasis. Lancet 2006 368, 1106–1118