ORIGINAL RESEARCH PAPER
VOLUME-6 | ISSUE-6 | JUNE-2017 | ISSN No 2277 - 8179 | IF : 4.176 | IC Value : 78.46
INTERNATIONAL JOURNAL OF SCIENTIFIC RESEARCH

Intracerebral Schwannoma: once again… Report of Two Cases and Literature Review

Neurosurgery

Alqroom Y. Rami.	M.D. Neurosurgery department, KHMC Royal medical services, KHMC, Neurosurgery department.AMMAN -JORDAN
Fayyad M. Luma.	M.D, FRCPath. Histopathology department, KHMC Royal medical services, KHMC, Neurosurgery department.AMMAN -JORDAN
Alqurashi R. Muath.	M.D. Pediatric neurology department, KHMC Royal medical services, KHMC, Neurosurgery department.AMMAN -JORDAN
Haddad E. Sizeph.	M.D. Interventional radiology department, KHMC Royal medical services, KHMC, Neurosurgery department.AMMAN -JORDAN
Khasawneh H. Nidal.	M.D. Neurosurgery department, KHMC Royal medical services, KHMC, Neurosurgery department.AMMAN -JORDAN
Al Shurbaji A. Amer.	M.D. Neurosurgery department, KHMC Royal medical services, KHMC, Neurosurgery department.AMMAN -JORDAN

ABSTRACT

Rationale: Schwannoma is a benign tumor that arises from Schwann cells of the peripheral nerve sheath, and is a common tumor of the cranial nerves. Intra-parenchymal schwannomas not related to cranial nerves are very rare. To our knowledge, about 70 cases have been reported so far since the first case reported by Gibson et al in 1966.

Patient concerns: We report two cases that presented with this rare condition (Intracerebral Schwannoma), presenting with long-term history of epilepsy and headache. No associated neurological deficits. Patients had an exceptionally long preoperative observational period. These are the first cases of a supratentorial intracerebral schwannoma reported in Jordan, also literature review.

Methods: A two female patients referred for definitive treatment of long standing history of un-controllable seizures over the last 10-years. Neuro-radiologic screening showed intracerebral lesion with peri-tumoral edema. The patients underwent complete surgical excision. Histopathological and immuno-histochemical examination confirmed the diagnosis.

Results: We successfully treated these patients with intracerebral Schwannoma related epilepsy. They had full recovery and seizure free after 2 years.

Conclusion: Intracerebral schwannoma is a very rare tumor, however it should be considered in the differential diagnosis list when a well-circumscribed small nodule with typical signal and dynamic characteristics is present. The final diagnosis should be done after histopathological and immuno-histochemical examination.

KEYWORDS:

Schwannoma, Intracerebral Schwannoma, epilepsy, differential diagnosis.

Introduction

Schwannomas originate from Schwann cells and are commonly benign, encapsulated, slow-growing and generally solitary tumor. [1-5] Most of these schwannomas arise from the vestibular portion of the VIIIth cranial nerve and less commonly, with descending order of frequency, from the Vth, IXth, Xth, and VIIth cranial nerves [4], intra-parenchymal schwannomas not related to cranial nerves are very rare, it represent less than 1%. To our knowledge, about 70 cases have been reported so far since the first case reported by Gibson et al in 1966. [5.6]

Case-I

A 14-year-old Sudanese female patient was referred to our clinic with recent aggravation of focal seizure activities on the right arm and intractable headache. Her first seizure attack took place 10 years ago which started with in¬voluntary right arm tremors followed by a loss of consciousness and generalized tonic-clonic convulsions. The patient was otherwise healthy. No significant per-sonal or family medical history were reported, no stigmata of neurofibromatosis and the remain-ing clinical examination was normal. During the 10-years of follow-up while on anti-epileptic medication the patient was un-keen on surgery. She complained of only in¬termittent focal sei-zures presented as right arm focal fits and was free of symptoms between seizure at¬tacks. In last 2-years she started to have prolonged seizure duration and disabling intractable headache. Par-ents requested surgical help when a suspicion of arteriovenous malformation was raised. Brain CT scan confirmed the presence of calcification. Angiogram ruled out the presence of arteriove-nous malformation. (Fig. 1).

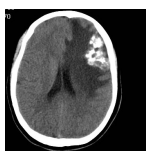

Figure 1: Non-contrasted brain CT scan revealed heavily calcified irregular left frontal lobe mass surrounded by massive edema.

After ruling out arteriovenous malformation from the diagnosis. Brain magnetic resonance images (MRI) re¬vealed a hypo-intense lesion on T1-weighted (Fig. 2) and mixed intensity on T2-weighted lesion in the left frontal lobe, the lesion was surrounded by significant edema (Fig. 3). Post contrast there was a serpentine enhancing structure with signal void representing calcifica-tion, the serpentine enhancing lesion reaching the dura matter with some enhancement of the du-ra at the site of the lesion (Fig. 4). Initial radiologic differential diagnoses were a pleomorphic xanthoastrocytoma, ganglioglioma, and dysembryoplastic neuroepithelial tumor. Patient under-went complete surgical excision. Gross examination revealed soft, fleshy, and highly vascular with calcification and a well-defined border. The excised mass had no attachment to the dura.

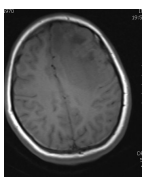

Figure 2: T1-weighted Brain magnetic resonance image revealed a hypo-intense lesion surrounded by extensive edema.

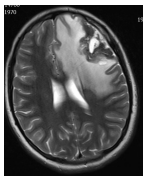

Figure 3: T2-weighted Brain MRI image showed mixed intensity lesion in the left frontal lobe with extensive edema and midline deviation.

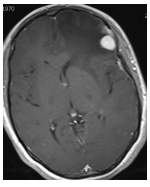

Figure 4: Post contrast Brain magnetic resonance image re¬vealed a serpentine enhancing structure with signal void representing calcification, reaching the dura matter with some enhancement of the dura at the site of the lesion.

The macroscopic examination consisted of several fragments of soft tissues, measuring 2.0×1.0 cm in the largest dimension. Grossly, the cut surface showed a gray yellow myxoid appearance. Under light microscopy, the tumor was composed of alternating Antoni A and B areas, i.e., cellu-lar and less cellular areas with numerous Verocay bodies (Fig. 5). There was focal hemorrhage and mild cystic change. The tumor had fascicular arranged spindle cells with elongated nuclei without nuclear pleomorphism, mitosis or necrosis. The tumor cells were positive for S100 protein confirming the diagnosis of schwannoma (Fig.6).

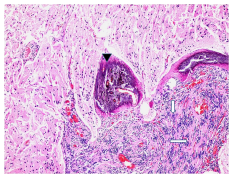

Fig. 5: Histological picture shows areas of infiltrative tongues into the surrounding brain parenchyma. Verocay bodies are seen (white arrows) and calcifications at the infiltrative edges (black arrowhead). Hematoxylin and Eosin stain.

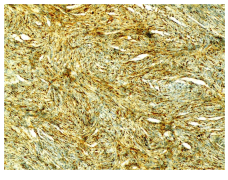

Fig. 6: Histological pictures, immuo-histochemical staining for S-100 protein. Positive nuclear and cytoplasmic staining in the spindle cells.

Case-II

A 35-year-old woman came into our clinical care due to recurrent fits over one-year. The physical -neurological examination and laboratory tests were normal. Diagnostic radiological investigations of the lesion were performed, which demonstrated a well-circumscribed hypo-intense lesion on T1-weighted with extensive edema (Fig. 7) and mixed intensity on T2-weighted lesion in the right frontal lobe, the lesion was surrounded by significant edema (Fig. 8). In post contrast there was a well-defined enhancing structure with signal void (Fig. 9). Correlating the clinical and radiographic features, an intracerebral lesion was thought of and a provisional diagnosis of glioma was made for this patient. The Patient underwent surgical intervention, where total resection achieved (Fig. 10). The final histopathology of the lesion demonstrated intracerebral schwannoma (Fig. 11). The patient got a good recovery, and was discharged a week after the surgery seizure- free.

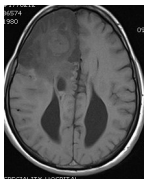

Figure 7: T1-weighted Brain magnetic resonance image showed a well-circumscribed right frontal lobe hypo-intense lesion surrounded by extensive edema.

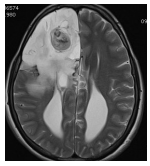

Figure 8: T2-weighted Brain MRI image showed mixed intensity well-defined lesion in the right frontal lobe with extensive edema and mild midline deviation.

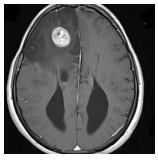

Figure 9: Post contrast Brain magnetic resonance image revealed a serpentine enhancing structure with signal void.

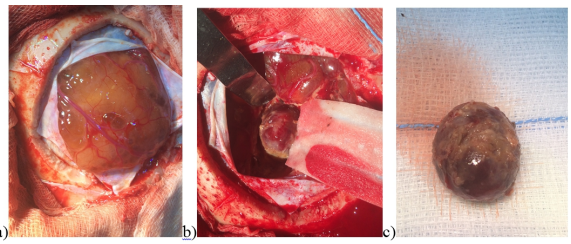

Figure 10: Intra-operative images:a) extensive brain edema after dura opening, b) lesion identified and dissected, c) total resection of the fleshy lesion.

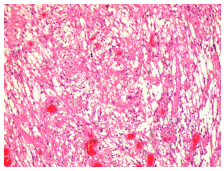

Fig. 11: Histological picture shows Hyper and hypo-cellular areas in the spindle cell tumor. Hematoxylin ad eosin stain.

Surgical technique

The surgical steps were common as for all the conventional craniotomies and were as follows: with the patient in a supine position under general anesthesia, while patient on the operating ta-ble. Once asleep, the head is placed in a 3-pin skull fixation device, after the incision was planned, a minimal shave is carried out with a disposable razor. Followed by sterile application of Betadine paint that is allowed to dry. Draping and toweling with a fluid pouch craniotomy drape. Then conventional craniotomy performed, the tumor totally removed. The patient's post-operative course was uneventful and no neurological deficits were observed. One month after the operation, patient had a postoperative MRI which revealed no residual enhancing mass. At two-year follow-up she has remained seizure free since the op¬eration.

Discussion

Schwannoma is a benign, encapsulated, slow-growing and generally solitary tumor that arises from Schwann cells of the nerve sheath. Intracranial schwannomas typically arise from the ves-tibular portion of the vestibular nerve. Other cranial nerves can harbor schwannomas but less fre-quently like the facial, trigeminal.[1-5]

The pathogenesis of intracerebral schwannomas is ambiguous. Several theories have been pro-posed. These theories can be allocated in two groups, the developmental and non-developmental. Atypical Schwann cells in the brain parenchyma may occur due to the alteration of the mesen-chymal pial cells according to the developmental theory [1.5], or from displaced neural crest cells that form foci of the Schwann cells [1.6]. The non-developmental theories support their assumption on the fact that the Schwann cells are present within the perivascular nerve plexuses and the large arteries in the subarachnoid spaces [1.7.8].

Diagnosis is very challenging due to its rarity in the central ner¬vous system and because of the absence of pathognomonic signs on radiologic images. Often, these challenges lead to delay in proper treatment of the patient. Although some general char¬acteristics of these tumors have been described. [9.10]

Symptoms and clinical manifestations are commonly related to the tumor location and size. Sei-zure is one of the most common symptom presentations. Most lesions are reported to be small, less than 2 cm in diameter. Eventually, such lesions may be more than 5 cm in diameter, and they present symptoms related to increased intracranial pressure. In our 2 cases seizure was the promi-nent presentation. [4.11-13]

The radiological differential diagnosis of an intracerebral schwannoma includes many other neo-plasms. These include pleomorphic xantho-astrocytoma and ganglioglioma. In order to differenti-ate between these tumors, excisional biopsy is usually needed. Further immunohistochemistry and/or electron microscopy are also needed to make the final diagnosis since some tumor like pilocytic astrocytoma and fibroblastic meningiomas resemble intracerebral schwannoma micro-scopically. [13.14]

Histopathologically, the detection of Antoni A and Antoni B structures, Verocay bodies, some-times with infiltration by foamy macrophages, and vascular hyalinization usually suffice for the recognition of schwannomas.

Typically, the tumor is well demarcated, at the superficial cerebral cortex and can be easily dis-sected from brain parenchyma in most cases. Surgery remains the main therapeutic modality and due to the benign nature of the tumor, complete excision is associated with cure. Schwannomas including our cases, can be removed completely without resulting in any neurological deficit. The long-term outcome after excision is generally good. The patients were discharged from our hospi-tal with no neurological deficit and seizure free. [14-17]

Our case appears to share many of the previously described typical features of intracerebral schwannoma. Young age, no known history of neurofibromatosis, seizure as an initial symp¬tom presentation, small size mass located at the supra-tentorial ce¬rebral cortex, peri-tumoral edema, and cyst are features that are commonly reported for intracerebral schwannoma. Preopera¬tively, we presumed the diagnosis of our case as pilocytic astrocy¬toma or pleomorphic xanthoastrocyto-ma because these tumors share the characteristics described above, and they have a higher inci-dence of occurrence. However, pathologic examination re¬vealed that the tumor was a typical schwannoma, indicating our expectation was erroneous. Thus, we suggest that demographic, clin-ical, and radiologic findings are insufficient to derive an accu¬rate diagnosis. We emphasize the importance of obtaining a sur¬gical specimen in order to make proper diagnosis.

Conclusion

Intracerebral schwannoma is a very rare and benign tumor, despite their rarity and the lack of specific radiologic findings, however it should be considered in the differential diagnosis list when a well-circumscribed small nodule with typical pathognomonic characteristics are present. Seizure is one of the most common symptom presentations. The definitive diagnosis made after histopathological and immuno-histochemical examination. Intracerebral schwannomas can be cured with complete surgical excision which is highly recommended.

References

1- Srinivas R, Krupashankar D, Shasi V. Intracerebral schwannoma in a 16-year-old girl: a case report and review of the literature. Case reports in neurological medicine. 2013;2013:171494.
2- Mardi K, Sharma J. Intracranial cystic (ancient) schwannoma of the temporal lobe: a rare occur-rence. The Internet Journal of Pathology. 2007;7(1)
3- Du R, Dhoot J, McDermott MW, Gupta N. Cystic schwannoma of the anterior tentorial hiatus. Case report and review of the literature. Pediatric Neurosurgery. 2003;38(4):167–173.
4- Casadei GP, Komori T, Scheithauer BW, Miller GM, Parisi JE, Kelly PJ. Intracranial parenchy-mal schwannoma. A clinicopathological and neuroimaging study of nine cases. Journal of Neu-rosurgery. 1993;79(2):217–222.
5- Russell DS, Rubinstein LJ. Pathology of Tumors of the Nervous System. London, UK: Edward Arnold; 1989.
6- Redekop G, Elisevich K, Gilbert J. Fourth ventricular schwannoma. Case report. Journal of Neurosurgery. 1990;73(5):777–781.
7- Nelson E, Rennels M. Innervation of intracranial arteries. Brain. 1970;93(3):475–490.
8- Feigin I, Ogata J. Schwann cells and peripheral myelin within human central nervous tissues: the mesenchymal character of schwann cells. Journal of Neuropathology and Experimental Neurology. 1971;30(4):603–612.
9- Jung JM, Shin HJ, Chi JG, Park IS, Kim ES, Han JW : Malignant intra¬ventricular schwannoma. Case report. J Neurosurg 1995;82 : 121-124.
10- Oztanir N, Emmez H, Aytar MH, Dogan M, Kaymaz M, Baykaner MK : Malignant intracerebral giant nerve sheath tumor in a 14-month-old girl with neurofibromatosis type 1 : a case report. Childs Nerv Syst 2009: 25 : 253-256.
11- Lee S, Park SH, Chung CK. Supratentorial intracerebral schwannoma : its fate and proper man-agement. Journal of Korean Neurosurgical Society. 2013;54(4):340-3.
12- Ghatak NR, Norwood CW, Davis CH. Intracerebral schwannoma. Surg Neurol. 1975;3:45–47.
13- Sobel RA, Michaud J. Microcystic meningioma of the falx cerebri with numerous palisading structures: an unusual histological pattern mimicking schwannoma. Acta Neuropathologica. 1985;68(3):256–8.
14- Zagardo MT, Castellani RJ, Rees JH, Rothman MI, Zoarski GH. Radiologic and pathologic find-ings of intracerebral schwannoma. AJNR Am J Neuroradiol. 1998;19:1290–1293.
15- Bristol RE, Coons SW, Rekate HL, Spetzler RF. Invasive intracerebral schwannoma mimicking meningioma in a child. Childs Nerv Syst. 2006;22:1483–1486.
16- Takei H, Schmiege L, Buckleair L, Goodman JC, Powell SZ. Intracerebral schwannoma clinical-ly and radiologically mimicking meningioma. Pathol Int. 2005;55:514–519.
17- Guha D, Kiehl TR, Krings T, Valiante TA. Intracerebral schwannoma presenting as classic tem-poral lobe epilepsy. J Neurosurg. 2012;117:136–140.