Volume : 2 | Issue : 12 | December 2013 • ISSN No 2277 - 8179

Research Paper

Medical Science

KEYWORDS :

Intranasal Prosthesis to Maintain Three-Dimensional Stability of the Nose after Surgical Reconstruction -Case Report

Sqn Ldr K S Naveen — Graded Specialist,, Division of Prosthodontics, Army Dental Centre(R&R),Delhi Cantt, New Delhi- 110 010

Col M Viswambaran — Commanding Officer, Military Dental centre, Jabalpur, MP

Introduction

Nasal prosthesis is a removable prosthesis that artificially restores part or entire nose. The nasal stent is a removable intranasal prosthesis to support the form of the nose [1]. Otolaryngologists and plastic surgeons frequently solicit the support of Prosthodontist to make intranasal prosthesis because of their specialized knowledge of impression procedures and laboratory techniques involved in fabrication of dental prosthesis. The need for nasal prosthesis may arise from variety of conditions including congenital absence or abnormality, traumatic avulsion or disfigurement and surgical excision or contracture for tumour resection [2].

Internal defects may result from tumour removal or complications of a cosmetic or airway enhancement procedure. Such defects often require skin grafting to the denuded surfaces. If the graft is left unsupported or if scar contracture is excessive, the internal airway chambers may collapse or stenose, leaving a functional as well as an esthetic problem [3].

Prosthetic support of the cartilage deficient nasal tissue can be valuable in reducing contracture immediately after surgery, for airway patency after healing, or for support of mobile peripheral tissue [4].

Case report

A 17 yr old male patient, a treated case of cleft lip and palate reported for secondary reconstruction of the nose [Fig.1]. On examination, there was alar collapse on the left side of the nose. The nasal passage was obliterated because of the webbings projecting from the alae on the left side. The right nasal cavity was normal. The case was discussed with the plastic and reconstructive surgeon for the surgical reconstruction followed by the intranasal prosthesis to maintain the patency of the nose.

Procedure

The impression of the right side nostril which had normal anatomy was made with help of low modeling plastic impression compound (DPI) on a solid metal wire in order to assess the approximate length and width of the nasal cavity. The nasal moulding was done externally with the finger pressure. The impression was altered to correspond to the left nostril in conjunction with the plastic surgeon. The pattern was invested by conventional means and processed with heat-cured poly methyl methacrylate resin (DPI), [Fig.2]. The processing was carried out in a water bath at 168°F for 12 hours and boiling for 30 minutes to ensure complete cure and maximum reduction of free monomer. After deflasking the prosthesis was finished and polished. It was made hollow so that the patient could breathe with the prosthesis in situ. The prosthesis was disinfected by immersing in 2 % gluteraldehyde.

The patient was operated under general anesthesia; the nasal webbings were exposed and surgically excised. The prosthesis was inserted after suturing the tissues [Fig.3]. The prosthesis was not removed for first 48 hours to prevent any oedema which may collapse the nasal cavity. The patient was instructed how to insert and remove the prosthesis and asked to wear it for six months post operatively. The six month review shows the good patency of the left nostril [Fig .4].

Discussion:

Intra nasal prosthesis is used in several ways with reconstructive surgery. Stents may be made for the maintenance of airways after graft procedures. To minimize cicatracial contraction, nasal stents should be inserted as soon as possible after surgery and should be worn for several months during the healing period [5].

When projected surgery involves removal of central supporting tissues, an intra nasal prosthesis can be constructed in advance for use in the operating room. A preoperative impression of the nares space is made with modeling compound sticks and an impression wash material [6]. The impression technique used depends on the potential function of the prosthesis. During impression making for maintaining the vestibular patency, it is often desirable to produce distension of the vestibule [7]. This can be accomplished on completion of the surgery by packing the nasal cavity posterior to the vestibule with gauze and then moulding silicone putty impression material in the vestibule [8].

Regardless of the impression technique, the final impression should demonstrate (1) a projecting retentive portion anteriorly that fits into the ventricle of the nasal vestibule,(2) a retentive portion that projects posteriorly into the anterior part of the nasal cavity (3) good surface detail of the lateral and medial walls of the vestibule [9] .An acceptable impression is flasked in dental stone and processed in acrylic resin. The clear acrylic is most frequently used to allow coloration from the underlying tissue. After processing, the prosthesis is hollowed to provide a patent airway and the internal surfaces are polished to reduce adherence of nasal secretions. The external surfaces are finished to remove sharp projections while maintaining the closest possible adaptation to the nasal tissues. Acrylic extensions interfering with insertion and removal of the prosthesis are modified at the insertion. Optimal esthetics is obtained when the external extension is established at the mucocutaneous junction of the external nares. Removal of the prosthesis can usually be achieved by digital pressure to the side of the nose [10]. Intra nasal prosthesis can be used to promote static graft resolution, airway patency, and prevent the cicatracial contracture and collapse of the nose.

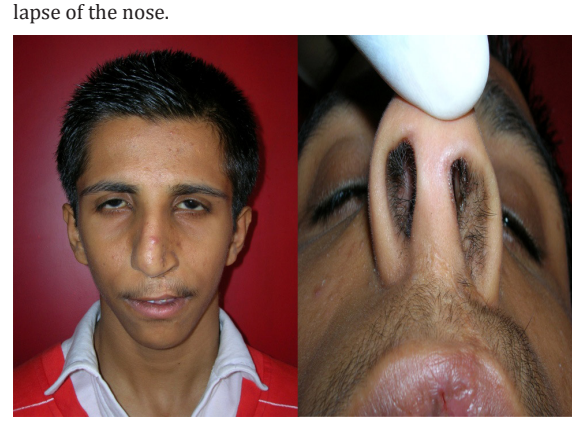

FIG.1 PRE OPERATIVE PRESENTATION

Volume : 2 | Issue : 12 | December 2013 • ISSN No 2277 - 8179



FIG.2 IMPRESSION WITH LOW FUSING IMPRESSION COMPOUND AND THE FINISHED PROSTHESIS

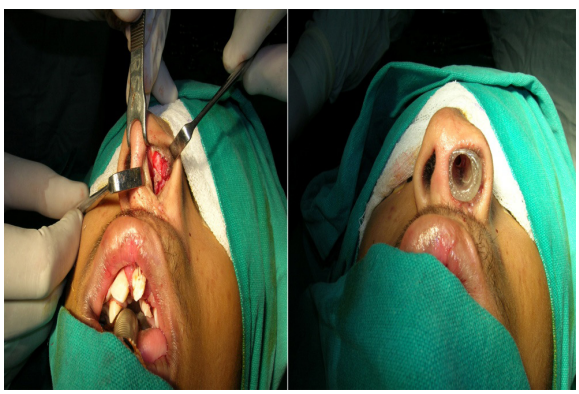

FIG.3 INTRAOPERATIVE AND THE PROSTHESIS IN SITU



FIG.4 SIX MONTHS POST OPERATION

REFERENCE

1. The Glossary of prosthodontic terms. J Prosthet Dent 2005;94: 10-92 | 2. Beumer J III, Curtis TA, Marunick MT. Maxillofacial rehabilitation prosthodontic and surgical considerations. St Louis: Ishiyaku EuroAmerica; 1996. p. 455-77. | 3. Parel S M. Intranasal conformers. J Prosthet Dent.1980; 43: 439-44. | 4. Young. Internal nares prosthesis. J Prosthet Dent.1970; 24: 320-3. | 5. Davenport J C treatment of alar collapse with nasal prosthesis. J Prosthet Dent.1981; 45: 435-7. | 6. Boucher L J .Internal nasal prosthesis J Prosthet Dent.1956; 6: 120-8. | 7. Holt G R. Prosthetics in nasal rehabilitation. Facial Plast Surg 1984; 2: 74-84 | 8. Costa P, An expansible splint for treatment of nostril stenosis. Plast Reconstr Surg. 1977 Sep; 60(3):395-7. | 9. Davenport J C. Laboratory procedure in the construction of intranasal prosthesis. J Prosthet Dent.1984; 51: 577-80. | 10. Seals RR Intranasal prostheses, splints, and stents. J Prosthet Dent. 1988; 60:595-601.