Volume : 3 | Issue : 11 | November 2014 • ISSN No 2277 - 8179

Research Paper

Intraoperative Radiography for Assessment of Clearance during Surgical Resection of Jaws

Medical Science

KEYWORDS : Intra operative imaging, jaw tumors, Ameloblastoma, Sternocleidomastoid flap.

Dr. Manish Kumar Bhagania	Associate Professor, Oral and Maxillofacial Surgery, Manipal College of Dental Sciences, Manipal, Manipal University
Dr. Abhay Taranath Kamath	MDS, Professor and Head, Oral and Maxillofacial Surgery, Manipal College of Dental Sciences, Manipal, Manipal University
Dr. Srikanth G.	MDS, Reader, Oral and Maxillofacial Surgery, Manipal College of Dental Sciences, Manipal Manipal University
Dr. Anukool Choube	BDS, Post Graduate, Oral and Maxillofacial Surgery, Manipal College of Dental Sciences, Manipal, Manipal University
Dr. Neha Sharma	BDS, Post Graduate, Oral and Maxillofacial Surgery, Manipal College of Dental Sciences, Manipal, Manipal University
Dr. Prem Sasikumar	BDS, Post Graduate, Oral and Maxillofacial Surgery, Manipal College of Dental Sciences, Manipal, Manipal University

ABSTRACT

Aims: Jaws are seldom affected by pathologies which require resection for comprehensive management to ensure clearance and minimise recurrence. This paper highlights the importance of intra operative radiography in determining adequate margins during surgery.

Methods: Ten patients were operated for surgical resection of jaws wherein the resected specimens were subjected to radiography for evaluating the adequacy of clear margins which was later sent for histopathology. Patients were followed up for least three years.

Results: Intra operative radiograph revealed adequate clearance which was confirmed by histopathology. The follow up period was free of any disease thereof.

Conclusion: Intra operative radiography is a helpful tool during surgical resection of pathologies afflicting the jaws. It proves to be a very economical, low hazard and a quick means to assist the operating surgeons in assessing the clearance of the margins.

Introduction

Maxillofacial region in general and mandible in particular is affected by a multitude of pathologies ranging from infections, cysts, benign tumors to malignant neoplasms. Ameloblastoma of the mandible is one such pathology whose comprehensive management would sometimes warrant resection to be carried out with or without reconstruction. The nature of the pathology determines the extent of surgical resection to be carried out in order to achieve adequate clearance and prevent any future recurrences. A marginal resection, by definition, maintains continuity of the mandible, whereas a segmental resection sacrifices continuity. A disarticulation resection is a type of segmental resection in which the condylar articulation is sacrificed. The type of resection is governed by the amount of involvement of the mandible which is determined by various diagnostic means available to us. These usually start with the basic clinical examination and diagnostic imaging techniques to bone scintigraphy, single photon emission computed tomography (SPECT) and magnetic resonance imaging (MRI).

There has been a recent trend in the management of such pathologies wherein emphasis is placed on the assessment of clearance margins through various techniques like employing frozen section analysis and use of intra-operative MRI (iMRI) during trans-sphenoidal microsurgery in selected patients for a safe and more complete resection as shown by Ramm-Pettersen, Berg-Johnsen, Hol, Roy, Bollerslev, Schreiner & at al in 2011. Another instance where assessment was carried out using elastic scattering spectroscopy in resected specimens of mandible for clearance of tumor margin as demonstrated by Jerjes, Swinson, Johnson, Thomas & Hopper in 2005. Frozen section analysis of the resected specimen has also been used for evaluation of bony margins but with mixed results previously mentioned by Wysluch, Stricker, Hölzle, Wolff & Maurer in 2010, Forrest, Schuller, Lucas & Sullivan in 1995 and Forrest, Schuller, Karanfilov & Lucas in 1997. This study was carried out with the intention of using a simple and yet quite effective technique of intra operative radiography (IOR) to assist the operating surgeons during the resection of mandible affected by ameloblastoma.

Materials and Methods

Ten patients (six males and four females) were included in this retrospective analysis who reported with jaw swellings to the Oral and Maxillofacial Surgery division of Manipal College of Dental Sciences, Manipal. Ethical Committee clearance was obtained by the Manipal University Institutional Review Board. Only patients who underwent some type of surgical resection of the mandible were included in the study. After a pre-operative work up comprising of thorough clinical examination and diagnostic imaging including radiography and computed tomography (Figure 1, 2 and 3) and if required bone scans, the patients were taken up for resection of the mandible under general anesthesia. The profile of the cases included in this study is depicted in the Table 1.

Depending upon the nature and extent of the pathology the patients were treated with either marginal, segmental or disarticulation of the mandible. The resected mandible specimens were subjected to IOR using extra oral radiography (Genius 60 Mobile, Wipro GE, Pune, India) to assess the clearance achieved during the surgery (Figure 4, 5) The resected mandible was then sent for histopathological examination (HPE) to confirm the clearance achieved during the surgery. A comparison was carried out to evaluate the significance of the use of IOR against the final histopathological report for all the specimens that were selected in this study. The patients were assessed over a period of three years at least to look for any recurrences (Figure 6, 7).

Volume : 3 | Issue : 11 | November 2014 • ISSN No 2277 - 8179

Results

Six males and four females were included in this study with an age range of 21 to 75 years (mean=39). All ten cases were diagnosed with ameloblastoma of the mandible. All the pathologies were treated with surgical resection under general anesthesia with adequate reconstruction wherever applicable. The IOR of the resected specimens showed that there was enough clearance with adequate healthy margins achieved during surgery and the findings after the histopathological examination confirmed the same (Table 1). The two assessments namely IOR and HPE were compared, which revealed minimal significance and suggested that the IOR has sufficient predictive value when compared to HPE. All the patients included in the study have been free of their diseases in the long term follow up. In total there were ten cases of ameloblastoma included in this study out of which there were 7 cases of Unicystic variants and 3 were Multicystic. Histological subdivision of the biopsied cases suggested 2 cases of intraluminal follicular pattern, 5 cases of intraluminal plexiform pattern and 3 were found to have a granular cell pattern.

Discussion

Oral and Maxillofacial surgeons encounter numerous pathologies of jaws in their clinical practice ranging from infections, cyst and tumors to malignancies like carcinomas and sarcomas. Often these pathologies require major resective surgeries to limit their progression and to gain clearance for the pathological entity in order to avoid future recurrences. The problem of resection is even more obvious as there are no certain guidelines laid down for the assessment of the tumor margins during the surgery and the surgeon is often left to make a decision based on the pre-operative work up based on the clinical examination and imaging techniques. The amount of mandibular resection is left to the discretion of the surgeon without predetermined studies to establish the amount of involvement, or the ability to use intraoperative pathological guidance to ensure complete eradication. A comfort level regarding adequate resection would definitely benefit the surgeon during resection and the future reconstructive surgeries. The standard method of evaluation is by decalcification of the resected cortical-cancellous specimen, but this process can take up to 2 weeks or sometimes even more to complete, based on the density of the cortical bone discussed by Forrest, Schuller, Karanfilov & Lucas in 1997. The frozen section analysis of the cancellous bone provides a rapid method to analyse the bone margin at the time of the resection. Unfortunately the frozen section analysis cannot be used for all types of cases for example the proximal ascending ramus and condylar regions cannot be evaluated by frozen section analysis because there is an absence, or limited sample, of the bone marrow in these regions. Although the iMRI has been used for assessment of tumors in the sphenoid region by neurosurgeons its use in oral and maxillofacial surgery is fraught with many inherent problems as the tumors reside in the bone hence they may not appear on the scan in their fullest extent and even the setting up of the apparatus for the surgical resection of the mandible along with iMRI would become too cumbersome to handle. The use of elastic scattering spectroscopy in resected specimens of mandible has been tried on the cadaveric studies however its use during live surgeries is still in experimental stages. Studies have suggested a careful clinical and radiological evaluation can guide the operating surgeons as they have a certain level of prediction of invasion by such tumors as shown by Rao, Das, Mathews, Naik, Chacko & Pandey in 2004. False positive and false negative reports are commonly seen with routine radiography techniques as the detection of the pathology is possible only after 30% bone loss has occurred. The use of intra operative radiography to assess the margins of the resected specimen as used in this study can turn out to be a boon for many surgeons as it is safe to handle, it is economical, it is definitely time saving, it is easily available, and most importantly it gives a good picture of the adequacy of the margins while resecting the tumors. Although the use of IOR has not been reported for use in oral and maxillofacial surgery, this study can further the cause for its use in resection of tumours and other such pathologies which require major resections.

Table 1: Profile of the subjects included in the study

Serial No.	Age/ Gender	Pathology	Involvement	Surgery	Intraoperative Radiography Finding	Histopathological Examination
1.	32/Male	Ameloblastoma	Left body of mandible	Segmental resection with stainless steel plate reconstruction	Largeunilocular radiolucency with a clear sclerotic rim of cortical bone	Unicystic ameloblastoma; intraluminal plexiform type with clear margins
2.	23/Male	Ameloblastoma	Left body of mandible	Marginal resection	Unilocular radiolucency with a clear rim of bone	Unicystic ameloblastoma; intraluminal follicular form with clear margins
3.	30/Female	Ameloblastoma	Right Body and angle region of mandible	Segmental resection with stainless steel plate reconstruction	Multilocular radiolucency with complete destruction of medulla, teeth lying unsupported, surrounded by clear rimof sound bone	Multicystic ameloblastoma; granular cell pattern
4.	45/Female	Ameloblastoma	Right body and symphysis of mandible	Segmental resection with stainless steel plate reconstruction	Largeunilocular radiolucency with a clear sclerotic rim of cortical bone	Unicystic ameloblastoma; intraluminal plexiform type with clear margins
5.	75/Male	Ameloblastoma	Right body of mandible	Marginal resection	Unilocular radiolucency with a clear rim of bone	Unicystic ameloblastoma; intraluminal follicular form with clear margins

Conclusion

Resection of the jaws is one of the common surgical procedures being performed by the oral and maxillofacial surgeons today when they are affected by pathologies like cysts, tumours, malignancies, etc. The surgeon however is faced with a big question of how much resection is justified to prevent any recurrences. With a shortage of sufficient means during surgery to assess the amount of resection, use of radiography can be considered to be a safe and predictable modality to assist in providing adequately clear margins to prevent any future recurrences.

Acknowledgements

The authors would like to acknowledge the efforts of the Department of Oral Medicine, Diagnosis and Radiology and the Department of Oral Pathology and Microbiology at Manipal College of Dental Sciences, Manipal along with the assistance from the Department of Anesthesiology and Surgical Oncology at Kasturba Hospital, Manipal.

Disclosure:

The authors wish to state that there are no conflicts of interest and financial disclosures to be made during the making of the manuscript.

6.	32/Male	Ameloblastoma	Left Body and angle of mandible	Segmental resection with sternocleidomastoid muscle flap reconstruction	Multilocular radiolucency with complete destruction of medulla, teeth lying unsupported, surrounded by clear rim of sound bone	Unicystic ameloblastoma; intraluminal plexiform type with clear margins
7.	30/Female	Ameloblastoma	Left ramus, angle and body of mandible	Disarticulation with sternocleidomastoid muscle flap reconstruction	Multilocular radiolucency involving the body and ramus with small uninvolved left condylar head and anteriorly sound bone	Unicystic ameloblastoma; intraluminal plexiform type
8.	42/Male	Ameloblastoma	Right condyle, ramus, angle and body of mandible	Disarticulation with sternocleidomastoid muscle flap reconstruction	Multilocular radiolucency involving the body and ramus with small uninvolved condylar head and anteriorly sound bone	Multicystic Ameloblastoma; granular cell pattern
9.	58/Male	Ameloblastoma	Left body of the mandible	Segmental resection with stainless steel plate reconstruction	Multilocular radiolucency involving the body with sound bone surrounding the lesion	Multicystic ameloblastoma; granular cell pattern
10.	23/Female	Ameloblastoma	Left body of mandible	Marginal resection	Unilocular radiolucency with a clear rim of bone	Unicystic ameloblastoma; intraluminal plexiform type with clear margins

Legends:

1. Preoperative photograph of the patient.

2. Preoperative radiograph of a patient with a large unilocular radiolucency of the mandible involving the left body, angle and the ramus.

3. Computed tomography scans of the same patient as in Figure 1.

A. Axial image of the involved left ramus and angle region

B. Coronal image of the involved segment of the mandible

C. Three dimensional image generated from the computed tomography

4. Photographs depicting use of radiography to assess the clearance obtained during surgical resection

5. Radiographs obtained for the resected specimen

6. Post-operative photograph of the patient

7. Post op radiograph of the patient two and a half years after discharge

Figure 1.



Figure 2.

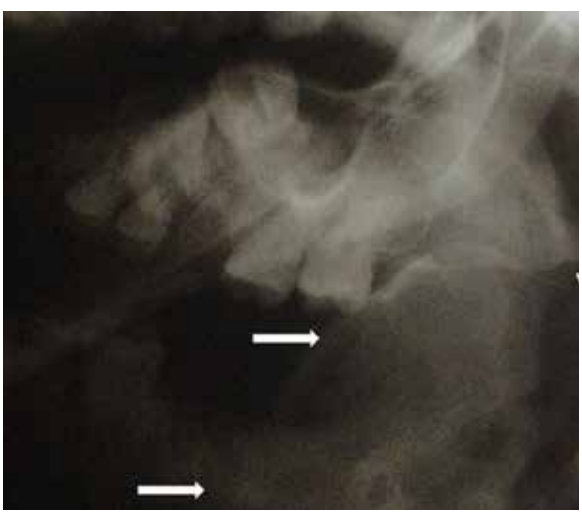

Figure 3.



Figure 4.

Volume : 3 | Issue : 11 | November 2014 • ISSN No 2277 - 8179



Figure 5.



Figure 6



Figure 7.



REFERENCE

Forrest LA, Schuller DE, Karanfilov B & Lucas JG (1997): Update on intraoperative analysis of mandibular margins. Am J Otolaryngol, 18 (6), 396-399 | | Forrest LA, Schuller DE, Lucas JG & Sullivan MJ (1995): Rapid analysis of mandibular margins. Laryngoscope. 105 (5), 475-477 | | Jerjes W, Swinson B, Johnson KS, Thomas GJ & Hopper C (2005): Assessment of bony resection margins in oral cancer using elastic scattering spectroscopy: a study on archival material. Arch Oral Biol 50 (3), 361-366 | | Ramm-Pettersen J, Berg-Johnsen J, Hol PK, Roy S, Bollerslev J, Schreiner T et al (2011): Intra-operative MRI facilitates tumor resection during trans-sphenoidal surgery for pituitary adenomas. Acta Neurochir 153 (7), 1367-1373 | | Rao LP, Das SR, Mathews A, Naik BR, Chacko E & Pandey M (2004):Mandibular invasion in oral squamous cell carcinoma: investigation by clinical examination and orthopantomogram. Int. J. Oral Maxillofac. Surg. 33 (5), 454-457 | | Wysluch A, Stricker I, Hölzle F, Wolff KD & Maurer P (2010): Intraoperative evaluation of bony margins with frozen-section analysis and trephine drill extraction technique: A preliminary study. Head Neck 32(11):1473-1478 |