ORIGINAL RESEARCH PAPER
Volume-8 | Issue-1 | January-2019 | PRINT ISSN No 2277 - 8179
INTERNATIONAL JOURNAL OF SCIENTIFIC RESEARCH

IS EVERY MUSCULAR DYSTROPHY DUCHENNE ? – A DILEMMA IN DIAGNOSIS

Orthopaedics

Dr.Ashwani Ummat	Associate Professor, Department Of Orthopaedics.
Dr.Manjeet Singh*	Professor And Head, Department Of Orthopaedics. *Corresponding Author
Dr.Sonia Kochhar	Professor And Head, Department Of Physiology.
Dr.Jasneet S Chawla	Postgraduate Resident, Department Of Orthopaedics.
Dr.Harish.V.K. Ratna	Postgraduate Resident, Department Of Orthopaedics.
Dr.Trisha Arora	Postgraduate Resident, Department Of Obstetrics And Gynaecology.

ABSTRACT

The muscular dystrophies are a group of inherited disorders characterised by progressive muscle wasting and weakness of variable distribution and severity. They can be subdivided into several groups including congenital forms in accordance with the distribution of predominant muscle weakness viz Duchenne, Becker, SMA,Emery dreifuss, Fascioscapulohumeral, Occulopharyngeal, Limb girdle,Neurogenic types.

CONCLUSION: The main motto of the study was to show that in the Era of Tertiary care hospitals and a tunnel view of diagnosis, Physicians & Orthopaedicians should have a better clinical knowledge &Awareness about when to do Non-Invasive investigations to narrow down the diagnosis &when to go for Invasive investigations like muscle biopsy inorder to confirm the diagnosis.

KEYWORDS

Muscular Dystrophy, duchenne, beckers

INTRODUCTION

This is a retrospective study done from 2015-2018, in our hospital, to simplify the dilemma in diagnosis of various muscular dystrophies & their prognosis. Many patients were previously diagnosed with muscular dystrophies with low life expectancy which has been re-diagnosed by us to have a muscular dystrophy with better life expectancy & survival rate which brought about changes in the life of the patients & their families. Our paper will help physicians & surgeons to diagnose various types of muscular dystrophies in a rational way.

Case 1

A 8 year old male child presented to us with the complaints of difficulty in running and climbing stairs . Patient's mother also noticed difficulty in walking immediately after getting up from the bed and frequent falls on walking were also noted. On taking an extensive history she also mentioned about delayed development of basic motor milestones like neck holding around 10-12months, walking with support around 2 and 1/2 years, walking without support at 3 and 1/2 years was noticed and other signs of delayed milestones were noticed by the mother and however on examination the calf muscles appeared bulky and child had difficulty in holding objects and the patient was diagnosed with duchenne muscular dystrophy from another medical centre on the basis of history and clinical findings and were told about the poor prognosis and low life expectancy.

The patient came to us and all the routine blood investigations were done, CBC were within normal limits, DLC showed increased lymphocytes, ESR was raised (82 mm at end of 1st hour). Creatine kinase levels were checked and turned out to be around 40 times the normal limits(normal <160 IU/L)

EMG was done in our physiology department which showed myopathic features



Fig-1.EMG SHOWING MYOPATHIC FEATURES.

Muscle biopsy- Immunohistochemical reactivity was done which showed decreased levels of dystrophin

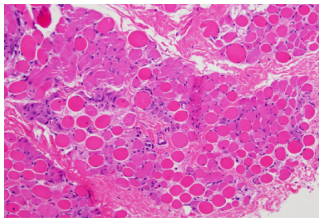

Fig-2.MUSCLE BIOPSY.

On regular follow up of the patient to our hospital, over a period of 2-3 years there was no deterioration in the walking capacity of the patient and however the ambulation was maintained without any evidence of development of contractures and however the cognition of the patient was normal.

With proper counseling we were able to convince the family to get the gene mapping done.

Results came out to be in favour of beckers dystrophy. Patient and his family were then explained about the better prognosis and higher life expectancy.

Case 2

15 year old patient presented to us with complaints of abnormal walking and wasting of muscles of the left lower limbs.

On examination patient had contractures of the hand, high foot arches, foot drop & Areflexia. Patient also had imbalance on walking &constant walking on toes. Wasting of the muscles for long duration had also given rise to a very typical inverted “champagne bottle appearance” or “stork leg appearance”. He was initially given a provisional diagnosis of muscular dystrophy from another medical centre.

On constant follow up to our hospital there were some other features like involuntary grinding of teeth and squinting were also prevalent. There was also minor difficulty in speaking and chewing . sensory changes were also marked in the patient and mainly at the area of common peroneal distribution. The reflexes, mainly the lower limb

were checked and they were absent in the limbs.

NCV was done in our physiology department which showed decreased speed of the nerves when checked in the affected limb- Deinnervation/Reinnervation. This lead us to think more towards charcot-marie tooth disease.

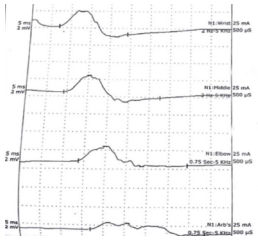

Fig-3.SLOWING OF CONDUCTION VELOCITIES

Family was explained about the better life expectancy and almost an assymptomatic life with minor support from Orthosis for the whole life.

A detailed history and an extensive physical examination can lead to a big change in the diagnostic ability of the surgeons.

Confirmation on Muscle Biopsy-Atrophic Muscle fibres that were elongated in groups & hypertrophic fibres with central Nuclei & fibre splitting .There were also increased amounts of connective tissue 'whorled fibres' .

Case 3

11 year old male child who was diagnosed with beckers muscular dystrophy from another medical centre presented to us with the complaints of difficulty in walking with support and minor respiratory complaints for the past 2 weeks, weakness of pelvic and shoulder girdle was present, weakness of neck flexors and on examination there were were contractures formed at ankle and knee and mild cognitive difficulties were noted. The patient didn't have any blood investigations reports.

Blood investigations were done at our hospital which showed increased levels of Creatine Kinase levels- 30,000 IU/L (normal <160 IU/L).

On follow up in our hospital after 2 months, The patient had moderate respiratory distress and was wheel chair bound and this lead us to think to shift the diagnosis to a more dreadful disorder, duchenne muscular dystrophy supported with blood investigations, elevated CPK levels, moderation deterioration in cognition and EMG was done showing myopathic features.

Muscle biopsy was done which showed both atrophic and hypertophic muscle fibres and some fibres were degenerated. Connective tissue between the fibres was increased.

After which patients relatives were counseled about the worsening of clinical features, poor prognosis and low life expectancy.

The family members were adviced about the screening of their progeny to rule out any features of muscular dystrophy in the siblings of the patient because early scrutinization would help to diagnose a disease in its early stages. The parents Genetic makeup were also told be examined.

Case 4

A 10 year old male patient presented tho the OPD with complaints of wasting of muscles of the right lower limb. Patient gives history of trauma - fall from bike 6 months back. On examination, patient had atrophy of gastrocnemius and tibialis anterior. Also wasting of pectoralis major, triceps and trapezius where noted. Patient had difficulty lifting the hands overhead and had a crooked smile, also features of UMN type of facial palsy features like drooling of saliva, deviation of angle of mouth to right side.

CBC and blood tests were done and CPK MB levels were high (312 U/L).

Muscle biopsy reveal isolated angular fibres, some necrotic fibres and moderate endomysial connective tissue proliferation.

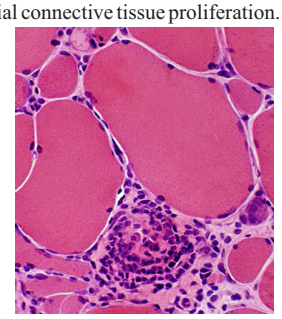

Fig-4.MUSCLE BIOPSY SHOWING ENDOMYSIAL ATROPHY

EMG done in our physiology department shows finding pertaining to myopathic disorder. Hence, facial palsy and traumatic cause for muscular changes was ruled out and lead away our diagnosis towards muscular disorders and dystrophies.

However, being the most common of all muscular dystrophies, the provisional diagnosis of duchenne dystrophy was made and family was explained about the poor prognosis and changes in the daily functioning of the child. It was a dreadful situation for the family and they were given an option of genetic testing at the time of discharge and(being from a well off status) patient's father promised to get gene testing done and review with the reports in the next visit.

Gene testing was done and it showed a FSHD allele size measuring 35 kilobytes (KB) that is consistent with a FSHD deletion mutation and hence the final diagnosis of FSHD was made

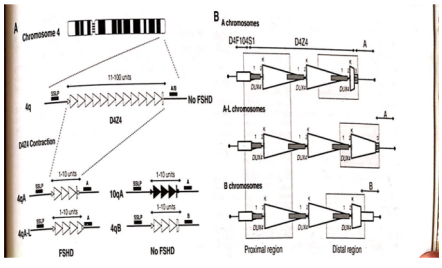

Fig-5.GENE MAPPING OF FSHD.

CASE 5

A 15year old patient presented to our Spine OPD with complaints of inability to walk without support, abnormal gait, difficulty in standing up from squatting posture, which has been progressively increasing over a period of 3years. He also gives a history of delayed dentition, occasional numbness of feet, fatique, daytime sleepiness &constipation. MRI Showed Multilevel Vertebral Segmentation anomalies in the form of Hemi-Vertebra, Butterfly Vertebra & Partial Block Vertebra. Patient was referred to our hospital primarily for treatment of Hemi-Vertebra.

On Examination, he had irregular and jagged tooth, pes cavus and Heel varus was also present. Power of EHL was 3/5, Ankle Dorsiflexion was 3/5 and there was Hyporeflexia of both Lower Limbs. Our Clinical diagnosis pointed towards Charcot-Marie Tooth Disease.

CBC reports were Normal, CPK-MB-36.0 U/L, LDH- 334U/L.

Nerve Conduction Study done in our physiology department showed Distal Motor latency of Left Peroneal Nerve was increased, Bilateral Sural Nerve Sensory latencies couldn't be recorded.

Electromyography of Right L/L showed Fibrillations in Rectus Femoris, >50% Polyphasic MUP's were seen in Rectus Femoris.
Left L/L- Fibrillations in the Gastrocnemius Medial Head.

Muscle Biopsy revealed atrophic fibres in small groups with focal areas showing extreme atrophy suggestive of Neurogenic Atrophy.


M.M. Superspeciality Hospital, Mullana - Ambala
HARYANA GOVT. ESTT. & FCRS EMPANELLED
MAHARISHI MARKANDESHWAR (DEEMED TO BE UNIVERSITY)
(Accredited by NAAC with Grade 'A')
DEPARTMENT OF PATHOLOGY
HISTOPATHOLOGY REPORT
Patient Name : Master. AJAY
Age / Gender : 15 Y(s) / Male
Admn / UHR No : IP1809130159 / 2018091302
Referred By : Dr.ORTHOPAEDICS UNIT
Bill Date : 21-Sep-18 03:19 pm
Report Date : 08-Oct-18 03:43 pm
Department : ORTHOPAEDICS
Ward : ORTHOPAEDICS UNIT-1
BIOPSY/ SURGICAL SPECIMEN
HPE.NO 5217/18
NATURE OF SPECIMEN
Muscle biopsy - gastrocnemius
GROSS
Received single tan-brown tissue piece 1.5x1x0.8 cm
MICROSCOPIC APPEARANCE
Sections show atrophic fibres in small groups with focal areas showing extreme atrophy, with only "nuclear clumps" visible. Some of the fibres show hypertrophy with central necrosis and occasional fibre splitting. Focal areas also show myonecrosis. Mild increase in the endomysial connective tissue and increase in the interstitial adipose tissue is noted.
IMPRESSION
Muscle, gastrocnemius, biopsy: Histomorphological features are suggestive of neurogenic atrophy
COMMENT
Please correlate with CK levels, EMG studies and clinical findings
*** End Of Report ***
Dr. P MAHAJAN, MD ASSISTANT PROFESSOR
Dr. R NANGIA, MD PROFESSOR
Dr. SB NIJHAWAN, PROFESSOR
This report is not valid for medico legal purposes.
If clinical summary is not given the report is likely to be

Fig-6.BIOPSY REPORT

Patient's family was counseled about the better life expectancy and basic life support in the form of Orthosis. Biopsy when done at Early Stages of Disesases would help us to Narrow down &confirm our diagnosis.

DISCUSSION

The muscular dystrophies are a group of inherited disorders characterised by progressive muscle wasting and weakness of variable distribution and severity.[1]

They can be subdivided into several groups including congenital forms in accordance with the distribution of predominant muscle weakness viz Duchenne, Becker, SMA,Emery dreifuss, Fascioscapulohumeral, Occulopharyngeal, Limb girdle,Neurogenic types.

The genes and their protein products(for eg : Dystrophin) that cause most of these disorders have now been identified.[2]

Duchenne muscular dystrophy (DMD) is a progressive form of muscular dystrophy that occurs primarily in males, though in rare cases may affect females. DMD causes progressive weakness and loss (atrophy) of skeletal and heart muscles.[2] Early signs of DMD may include delayed ability to sit, stand, or walk and difficulties learning to speak. Muscle weakness is usually noticeable by 3 or 4 years of age and begins in the hips, pelvic area, upper legs, and shoulders. The calves may be enlarged. Children with DMD may have an unusual walk and difficulty running, climbing stairs, and getting up from the floor. Muscle weakness worsens with age and progresses to the arms, legs and trunk. Most children with DMD use a wheelchair full time by age 13. Heart and respiratory muscle problems begin in the teen years and lead to serious, life threatening complications.[3]

Becker muscular dystrophy (BMD) is characterized by later-onset skeletal muscle weakness. With improved diagnostic techniques, it has been recognized that the mild end of the spectrum includes men with onset of symptoms after age 30 years who remain ambulatory even into their 60s. Despite the milder skeletal muscle involvement, heart failure from DCM is a common cause of morbidity and the most common cause of death in BMD. Mean age of death is in the mid-40s.[4]

The term **spinal muscular atrophy (SMA)** is applied to a diverse group of genetic disorders that all affect the spinal motor neuron. The different forms of SMA are associated with numerous gene mutations and significant phenotypic variability. SMA is usually categorized by pattern of weakness (i.e. whether predominantly proximal or distal) and mode of inheritance. It is the most common genetic cause of death in infants.[5]Common clinical features are,Progressive muscle wasting,Progressive weakness of girdle muscles,Fasciculations and Contractures.

Emery-Dreifuss muscular dystrophy is characterised by the clinical triad of, 1.Joint contractures that begin in early childhood,2.Slowly progressive muscle weakness &wasting initially in a humero-peroneal distribution that later extends to the scapular &pelvic girdle muscles,3.Cardiac involvement-palpitations, pre-syncope and syncope, poor exercise tolerance and congestive cardiac failure.

In general, joint contractures appear during the first two decades, followed by muscle weakness and wasting. Cardiac involvement usually occurs after the second decade.[6]

Facioscapulohumeral muscular dystrophy (FSHMD)—originally named Landouzy-Dejerine—is a usually autosomal dominant inherited form of muscular dystrophy that initially affects the skeletal muscles of the face (facio), scapula (scapulo) and upper arms (humeral). FSHD is the third most common genetic disease of skeletal muscle. Symptoms may develop in early childhood and are usually noticeable in the teenage years, with 95% of affected individuals manifesting disease by age 20 years. A progressive skeletal muscle weakness usually develops in other areas of the body as well; often the weakness is asymmetrical. Life expectancy can be threatened by respiratory insufficiency, and up to 20% of affected individuals become severely disabled, requiring use of a wheel chair or mobility scooter.[1]

Oculopharyngeal muscular dystrophy is a genetic condition characterized by muscle weakness that begins in adulthood, typically after age 40. The term "oculopharyngeal" refers to the eyes (oculo-) and a part of the throat called the pharynx (-pharyngeal). Affected individuals usually first experience weakness of the muscles in both eyelids that causes droopy eyelids (ptosis). Ptosis can worsen over time, causing the eyelid to impair vision, and in some cases, limit eye movement. Along with ptosis, affected individuals develop weakness of the throat muscles that causes difficulty swallowing (dysphagia). Dysphagia begins with dry food, but over time, liquids can also become difficult to swallow. Dysphagia can cause saliva to accumulate and a wet-sounding voice. Many people with oculopharyngeal muscular dystrophy also have weakness and wasting (atrophy) of the tongue. These problems with food intake may cause malnutrition, choking, or a bacterial lung infection called aspiration pneumonia.[7]

Limb-girdle muscular dystrophy (LGMD) or Erb's muscular dystrophy is a genetically and clinically heterogeneous group of rare muscular dystrophies.It is characterised by progressive muscle wasting which affects predominantly hip and shoulder muscles. LGMD has an autosomal pattern of inheritance and currently has no known cure or treatment. The symptoms of an individual with Limb-girdle Muscular Dystrophy (LGMD) generally has great difficulty walking, going both up and down stairs and raising from a chair. The inability to bend over or squat down is also present. Because of these difficulties, falling can occur on a regular basis. Lifting certain objects, as well as difficulty extending your arms out or above your head, varies from difficult to impossible depending on the severity. Eventually the ability to walk/run deteriorates.[8]

Charcot- marie-tooth Disease(aka Hereditary Motor-sensory Neuropathy Type-1) ia an Autosomal Dominant condition. Age of onset of symptoms is usually in the second decade.Clinical Features are, Foot & gait abnormalities-pes cavus or hammer-toe deformities,Intrinsic muscles of the foot are affected first, Areflexia(deep tendon reflexes are first lost in gastrocnemius &soleus muscles), Impaired sensations of lower limbs, Involuntary grinding of teeth &squint, Pes cavus &pes planus, Inverted champagne-bottle appearance or stork-leg appearance & Claw-hand deformities (in later stages).[9]

Table 1.Differentiating clinical features.

SNo	Type	Inheritance	Age of onset	Clinical features	Prognosis	Cause of death	Diagnosis	EMG Findings
1.	DMD	XR	2-3yrs	*unable to walk after 12yrs. *Gower sign *calf pseudo hypertrophy *progressive kyphoscoliosis	*Wheel chair dependant by adolescence *Respiratory failure in 3rd-4th decade.	1.Respiratory failure 2.cardiomyopathy.	increase in CPK levels	Myopathic features
2.	BMD	XR	5-15yrs	*variable weakness *Able to walk after 15 yrs	Respiratory failure by 4th decade	Respiratory failure	increase in CPK levels	Myopathic features

3.	CMTD	AD	10-15yrs	*Foot &Gait Abnormalities. *Impaired sensations of Lower Limbs.	Better life Expectancy	_____	_____	Fibrillations
4.	FSHD	AD	10-20yrs	*Finger &Wrist stiffness *Facial Palsy	Better Life Expectancy	_____	_____	Endomysial Atrophy

CONCLUSION

The main motto of the study was to show that in the Era of Tertiary care hospitals and a tunnel view of diagnosis, Physicians & Orthopaedicians should have a better clinical knowledge &Awareness about when to do Non-Invasive investigations to narrow down the diagnosis &when to go for Invasive investigations like muscle biopsy inorder to confirm the diagnosis. Early Diagnosis & necessary treatment or interventions would help in disability prevention and better life expectancy of the patients. Patient's and their relatives should also be educated about the concept of Non-Consanguinous marriages in order to prevent such dystropies in their progeny especially to families where there is already a patient of this type. ***Also all muscular dystrophies are not duchenne muscular dystrophy and patients can have a Better life expectancy.*** From our experience in the past 3years,we could conclude that a thorough knowledge, proper history and appropriate investigations would help doctors to point out their diagnosis to a particular muscular dystrophy without any dilemma.

REFERENCES

1. Ashwani U, Sonia K. Case Report ;Fascioscapulohumeral Muscular Dystrophy. Pb Journal of Orthopaedics. 2014 ;15(1):55-58.
2. Bushby K, Finkel R, Birnkrant DJ, Case LE, Clemens PR, Cripe L, et al. Diagnosis and management of Duchenne muscular dystrophy, part 1: diagnosis, and pharmacological and psychosocial management. Lancet Neurol. 2010;9(1):77-93.
3. Hoffman EP, Brown RH, Kunkel LM. Dystrophin: the protein product of the Duchenne muscular dystrophy locus. Cell. 1987;51(6):919-28.
4. Hoffman EP, Fischbeck KH, Brown RH, et al. Characterization of dystrophin in muscle-biopsy specimens from patients with Duchenne's or Becker's muscular dystrophy. The New England Journal of Medicine. 1988;318(21):1363–1368.
5. Hoffmann J: U" ber chronische spinale Muskelatrophie im Kindesalter, auf familiärer Basis [On chronic spinal muscular atrophy in childhood, with a familial basis; in German]. Dtsch Z Nervenheilkd. 1893, 3: 427-470. 10.1007/BF01668496.
6. Bialer MG, McDaniel NL, Kelly TE. Progression of cardiac disease in Emery-Dreifuss muscular dystrophy. Clin Cardiol. 1991;14:411–416.
7. Aarli JA. Oculopharyngeal muscular dystrophy. Acta Neurol Scand. 1969;45(4):484–492.
8. van der Kooi AJ, Barth PG, Busch HFM, de Haan R, Ginjaar HB, van Essen AJ, et al. The clinical spectrum of limb girdle muscular dystrophy A survey in the Netherlands. Brain. 1996;119(5):1471–1480.
9. Jani-Acsadi A, Krajewski K, Shy ME. Charcot–Marie–Tooth neuropathies: diagnosis and management. Semin Neurol. 2008;28:185–194.