VOLUME-6 | ISSUE-4 | APRIL - 2017 • ISSN No 2277 - 8179 | IF : 4.176 | IC Value : 78.46

Isolated muscular cysticercosis – A rare diagnostic dilemma

Orthopaedic

KEYWORDS: Muscular cysticercosis, Muscle strain, Brachialis muscle.

Dr. Divyanshu Goyal (MBBS, MS Orthopaedics)

ABSTRACT

Introduction: Isolated muscular cysticercosis is a diagnostic challenge to treating doctor. Very often the presenting symptom is only muscle strain and you have to keep in mind about muscular cystecercosis. Case **report:** this is a case of isolated involvement of the brachialis muscle in a young male, came in OPD with chief complaints of pain of the lower arm. Initially conservative treatment was advised by which pain was not relieved. MRI of the arm was ordered which revealed the diagnosis of cysticercosis of brachialis muscle. **Conclusion:** In endemic area, chronic intractable muscular pain which is not responding to conservative treatment, diagnosis of muscular cysticercosis should always be considered.

Introduction:

Cysticercosis has now emerged as a 'global problem', because of the influx of immigrants from endemic areas [1]. Cysticercosis in humans is infection with the larval form(cysticercus cellulosae) of the pork tapeworm T. solium. Most common manifestation is neurocysticecosis [2] Other common site of occurrence in order of occurence are vitreous humour of eye,striated muscle and subcutaneous tissue.[3] Muscular cysticercosis is usually associated with nervous system involvement.[4]. Solitary cysticercosis of muscle without involvement of central nervous system is a rare entity and till date only a few case has been reported in the literature. It causes diagnostic dilemma as there is a lack of specific features.

Case report:

A 25 year old male presented to OPD with complaints of lower arm pain after his routine exercises in the gym. He was a non vegetarian. There was no recent history of constitutional symptoms like fever, weight loss and arthralgia. The pain was dull aching in nature and exacerbated with elbow flexion and extension. His medical and family history was not significant.

On physical examination, there was no apparent swelling around the elbow. Skin over the region was normal. There was no signs of acute inflammation. There was pain on deep palpation of lower arm. A diagnosis of biceps strain was made, albeit no tenderness of biceps tendon was noted. Initially, the patient was treated conservatively with nonsteroidal anti-inflammatory drugs, Ice application and Interferential Therapy (IFT). Patient got some relief in pain with the treatment. After one week of treatment isometric exercises were started. After 2 weeks, the patient returned to OPD with increased intensity of pain. On examination active elbow flexion and passive elbow extension was painful. The patient was advised to continue conservative treatment with an initial period of inactivity, but he did not get relief. The patient was thoroughly investigated with X-ray of the arm including elbow AP and lateral views and routine blood investigations. All these investigations did not contribute to the diagnosis. MRI of the involved arm was advised which showed a lobular shaped irregular marginated lesion with a low signal intramural nodule in the brachialis muscle, exhibiting low signal peripheral rim on T2 weighted images with central hyper intensity (Fig 1a and 1b).

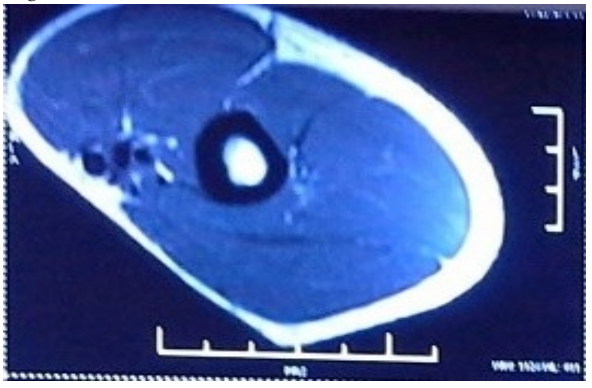

Figure 1a



Figure 1b

Diffuse STIR hyper intense signals in the brachialis muscle fibers surrounding lesion were noted. No significant contrast enhancement of the lesion was noted. A diagnosis of degenerative intramuscular cysticercosis was made. The patient was put on oral Albendazole 400 mg twice a day for 15 days. After 2 weeks of treatment, the patient completely relieved of his symptoms.

Discussion:

Taeniasis is the intestinal infection by Taenia Soleum, which is usually caused by ingestion of contaminated Pork. Humans are definitive host and infected with the larval stage, the cysticercus (Cysticercus cellulose), from eating infected pork. A cysticercus attaches to the intestinal wall by its scolex and it grows by forming new proglottids and becomes an adult worm. Adult tapeworm produces eggs (proglottids) which become mature and gravid proglottids are shed off in feces.

Pigs are the intermediate host and they get infected by ingesting the eggs from human feces or vegetation contaminated with human excreta. In the intestine, embryonated eggs hatch into motile oncospheres. The ova hatch in the intestine and develop into larvae that invade the intestines, enter the vasculature and develop in the tissues [5, 6]. Oncospheres migrate to striated muscles, brain, eyes, liver, and other tissues, where they settle as cysts called cysticerci. Humans may be accidental secondary hosts when they ingest embryonated eggs, either by autoinfection or ingestion of contaminated food. Like in pigs these eggs hatch into oncospheres which settle into various tissues, including brain, muscles, eyes, subcutaneous tissues as a cyst (cysticercosis).

Adult tapeworm (Taeniasis) usually doesn't cause any symptoms and it is cyst which causes clinical Manifestations. Muscular cysticercosis often goes unnoticed because it remains asymptomatic in most individuals. Three types of clinical manifestations of muscular cysticercosis have been described: the myalgic, myopathic type; the nodular or mass like type and the pseudohypertrophy type in

which multilocular cyst forms in a group of muscles [5]. Our patient had the mass like type presentation, which simulates benign neoplastic conditions of muscles or an intramuscular abscess.

Diagnosis of isolated muscular cysticercosis poses a challenge to clinicians because of the rarity of the disease. Most of the time patients correlate the pain with trauma or intense exercise which further delays the diagnosis. Apart from immunochemical studies (including detection of anticysticercal antibodies), CT, MRI and USG are important diagnostic modalities. CT scan is very helpful in detecting neurocysticercosis but may not be helpful in muscular cysticercosis. X ray rarely helps in diagnosis when calcification of the cyst occurs. The USG and MRI can reliably diagnose the muscular cysticercosis [7, 8].. In any doubt FNAC should be done to make final diagnosis.

Treatment of cysticercosis depends upon the site of involvement. Isolated muscular cysticercosis may require excision when it is painful and pressure symptoms appear. Many case reports of successful nonsurgical treatment of muscular cysticercosis with oral anthelmintic drugs Albendazole or praziquantel have been published [9, 10]. In our case also patient got relieved of symptoms with oral Albendazole.

Clinical message:
In patients presenting with muscle strain not relieved from conservative treatment, especially in endemic areas, isolated muscular cysticercosis should be ruled out. MRI and USG should be called for in patients with intractable muscle strain to reach the diagnosis.