ORIGINAL RESEARCH PAPER

Volume-7 | Issue-11 | November-2018 | PRINT ISSN No 2277 - 8179

INTERNATIONAL JOURNAL OF SCIENTIFIC RESEARCH

KARTAGENER SYNDROME- A CLINICAL DILEMMA

Pediatrics

Dr. Karan Bagga MD (Pediatrics) Mahatma Gandhi Mission's Medical College & Hospital, Aurangabad.

Dr. Monarch Shah* MBBS Mahatma Gandhi Mission's Medical College & Hospital, Aurangabad.
* Corresponding Author

Dr. Anjali Kale MD(Pediatrics) Professor & Head, Department of Pediatrics, Mahatma Gandhi Mission's Medical College & Hospital, Aurangabad.

ABSTRACT

Kartagener syndrome is a subset of primary ciliary dyskinesia, an autosomal recessive condition characterized by abnormal ciliary structure and/or function leading to impaired mucociliary clearance. The prevalence of primary ciliary dyskinesia is approximately 1/12,000-1 /60,000[1]. Approximately 50% of the patients with primary ciliary dyskinesia have Kartagener syndrome/situs abnormality. No gender predilection is recognized. Kartagener syndrome is characterized by the clinical triad of situs inversus, chronic sinusitis and/or nasal polyposis and bronchiectasis. We describe a case wherein the patient had an initial presentation suggestive of bronchial asthma which turned out to be something out of the box. The symptoms described in our report will be commonly encountered by most paediatricians in their day to day practice.

KEYWORDS

Asthma, Kartagener, Dextrocardia

Case Report:

A 13-year-old female came with complaints of recurrent episodes of fever with a cough, cold, a headache and breathlessness since birth, which increased in severity over the last 2 years. Breathlessness, coughing and noisy breathing were more prominent during the night. The severity of which was so much so that she would have to wake up in the middle of the night. On further questioning, the patient described the seasonal increase of severity with exacerbation of complaints in cooler temperatures and in windy atmospheres. Present complaints also included dyspnea on minimal exertion, with occasional cyanosis on exertion, multiple joint pains involving bilateral ankle, knee and wrist joints. The patient had a history of purulent ear discharge since birth and progressive reduction in hearing. Her hearing was impaired when she presented as well. The patient's parents further described a past history of frequent episodes of cyanosis that were precipitated by crying in early years of life. The patient was being treated as an asthmatic since the age of 5 years up to the age of 10 years.

On examination: The patient was afebrile. Heart rate-86/min, peripheral pulses palpable well felt, respiratory rate-26/min, oxygen saturation-95% on room air and blood pressure-114/76mm.Hg. Conjunctiva was pale, anicteric. No cyanosis, clubbing, palpable lymph nodes, oedema. Respiratory system examination: Air entry was equal on both sides. Crepitations were heard bilaterally over the entire lung fields, with bilateral wheezing. Cardiovascular examination revealed the apex beat in right 5th intercostal space medial to midclavicular line. S 1 and S2 heart sounds were normal. No murmurs were heard. Abdominal and neurological physical examinations were benign. Anthropometry: Weight-28 kg, Height-146 cm, Upper Segment:

Lower Segment = 0.8:1. Bilateral ear examination revealed central perforations in both the tympanic membranes suggesting tubotympanic chronic suppurative otitis media (considered as safe chronic suppurative otitis media)

Investigations:

Complete blood count: Hemoglobin - 11.3 g/dl, total leucocyte Count-13,000/mm3 differential leucocyte count- neutrophils 65% lymphocytes 27%, hematocrit- 33.3%, platelet count - 3,46,000/mm3. Chest X-ray showed dextrocardia with left-sided pneumonitis (figure1). CT scan of the chest was suggestive of situs inversus, consolidation in the left middle lobe and left parahilar region along with bronchiectatic changes with adjacent fibrosis in the posterior segment of the left upper lobe and a posterior basilar segment of the left lower lobe. 2 bronchi on the right side and 3 on the left noted (figures 2&3). Gram staining revealed many polymorphonuclear leucocytes, few epithelial cells, gram-positive cocci in pairs, gram-positive bacilli and occasional gram-negative bacilli. Staining for acid-fast bacilli was negative. Sputum for acid-fast bacilli also turned out to be negative for 2 samples sent 24 hours apart. Sputum culture isolated Streptococcus pyogenes which were sensitive to Linezolid, Clindamycin, Doxycycline, Teicoplanin, Azithromycin and resistant to Levofloxacin, Co-trimoxazole. Spirometry showed normal flow rate and normal lung volume with poor post-bronchodilator reversibility. Echocardiography showed situs inversus with dextrocardia and no evidence of any congenital heart disease. The natural progression of primary ciliary dyskinesia is relatively slow compared to cystic fibrosis for example, but nonetheless, up to 25% of patients eventually develop respiratory failure [2]. Treatment largely consisted of nebulization, physiotherapy, early treatment of chest infection with antibiotics and immunization against influenza virus 4 along with having a healthy diet to boost one's immunity [3]

We planned to go for a CFTR gene mutation testing. If negative, considering this presentation as Kartagener syndrome only, a future lobectomy would be planned.

Thus, even though complaints and history point to Asthma, we need to dig deeper and search for more than what we have. Complacency in diagnosis may allow error wherein we might miss out on something bigger.



FIGURE 1. Chest X-ray PA view showing dextrocardia with left-sided infiltrates suggestive of pneumonitis



FIGURE 2. CT chest Axial View showed situs inversus, consolidation in the left middle lobe and left parahilar region along with

bronchiectatic changes with adjacent fibrosis in the posterior segment of the left upper lobe and a posterior basilar segment of the left lower lobe. 2 bronchi on the right side and 3 on the left noted.

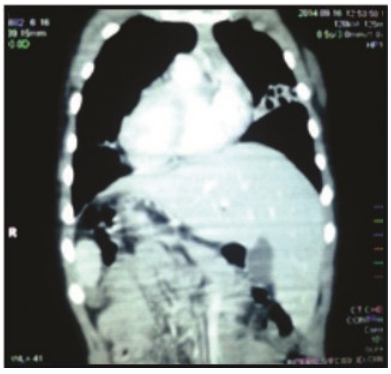

FIGURE 3.CT chest coronal section situs inversus, consolidation in the left middle lobe and left parahilar region along with bronchiectatic changes with adjacent fibrosis in the posterior segment of the left upper lobe and a posterior basilar segment of the left lower lobe. 2 bronchi on the right side and 3 on the left noted.

REFERENCES

1. Noone PG, Leigh MW, Sannuti A, Minnix SL, Carson JL, Hazucha M, et al. Primary Ciliary Dyskinesia. American Journal of Respiratory and Critical Care Medicine. 2004;169(4):459–67.
2. Kennedy M, Noone P, Leigh M, Zariwala M, Minnix S, Knowles M et al. High-Resolution CT of Patients with Primary Ciliary Dyskinesia. American Journal of Roentgenology. 2007;188(5):1232-1238.
3. Nadel H, Stringer D, Levison H, Turner J, Sturgess J. The immotile cilia syndrome: radiological manifestations. Radiology. 1985;154(3):651-6