Research Paper

Volume : 4 | Issue : 6 | June 2015 • ISSN No 2277 - 8179

Leprous Synovitis – A Case Report

Medical Science

KEYWORDS : Leprosy, mycobacteriumleprae, arthropathy, neuropathy, synovitis.

DR.DINESH KULKARNI M.D. ASSOCIATE PROFESSOR, DEPT. PATHOLOGY, BIDAR INSTITUTE OF MEDICAL SCIENCES, BIDAR KARNATAKA INDIA

DR.RITESH SULEGAON. M.D ASSISTANT PROFESSOR, DEPT. OF PATHOLOGY, BIDAR INSTITUTE OF MEDICAL SCIENCES, BIDAR KARNATAKA INDIA

DR. BHASKAR K. M.S ASSOCIATE PROFESSOR AND HOD, DEPT. OF ORTHOPEDICS, BIDAR INSTITUTE OF MEDICAL SCIENCES, BIDAR KARNATAKA INDIA

ABSTRACT

Leprosy is a chronic granulomatous infectious disease caused by acid and alcohol resistant Mycobacterium-Leprae with predominant involvement of skin and nerves. Other organs affected are eyes, respiratory tract, lymph nodes, testicles and joints.The clinical presentation of leprosy is highly variable and in all its stages it can mimic great variety of other lesions. Leprosy with skin lesions is classically diagnosed by full thickness skin biopsy. Musculoskeletal involvement, though third most common, isunderdiagnosed and underreported. It may manifest in the form of Charcot's arthropathy, Acute Symmetrical Polyarthritis during lepra reactions, Insidiousonset chronicsymmetrical polyarthritis or as Isolated Tenosynovitis. At times, articular involvement may be the sole presenting manifestation even withoutcutaneous lesions. Here, one should rule out other causes of arthritis by radiological and laboratory investigations before diagnosing the patient with leprous synovitis. Delay in diagnosis and management may be detrimental and result in deformities, disability and loss of function.

We report a case of leprous synovitis in a known patient of lepromatous leprosy from an endemic zone in northern Karnataka who took inadequate treatment.

INTRODUCTION

The wordleprosy is derived from the ancient Greek word le´pra ,means 'a disease which makes the skin scaly'[1]. Leprosy is a disease of great antiquity and is believed to have its origin in India[2]for which references available in Vedic Hindu Literature "SushrutaSumhita" written around 600 B.C. as 'Kushtrog'[1,3].The appearance of disease in Greece coincided with the return of armies of Alexander the Great from Indian campaign in 327 – 326 B.C. It disappeared from Europe with improved hygiene and care, but endemics are still found in central and south America, Africa and India, related to overcrowding and poverty[2]. The disease has many myths and carries a grave social stigma and ostracism which compels the patients to hide it resulting in manifestation of deformities causing multidimensional problems not only to patient and family but also to community and nation[3]. Its exact mode of transmission is still uncertainand despite advances in diagnosis and treatment, it isa major cause of morbidity in many developing countrieseven today[1].

The classical presentation of leprosy is in the form ofhypesthetic/anaesthetic, anhidrotic macules, patches, plaques orpapulonodular lesions[4]. By and large, we think of leprosy as apainless disease,however, some patientswith lepromatous leprosycomplain of neuritis[5]. Neural involvement can manifest asparesthesias or as sensori-motor mononeuropathy, mononeuritismultiplex or polyneuropathy[4]. In recent times, primary articular involvement in leprosy, dueto infiltration by M. leprae or as part of lepra reaction, has beenrecognized. The reported prevalence varies from 1% to 70%[6].The two most common and well-recognized forms of articularinvolvement, neuropathic joints and post-traumatic septic arthritisoccur as a consequence of neuropathy[4].However it may present in unusual ways leading to missed or delayed diagnosis and thus further increasing themorbidity caused by the disease[6].

CASE REPORT

A 55 year old male, residing in an asylum, unmarried and separated from family, coming from endemic zone for leprosy, presented with left knee pain for 2 years, which was gradual and progressive with restricted movements. Patient was diagnosed to have leprosy 12 yrs back and he took irregular and inadequatetreatment for 3-4 years. On general examination patient had saddle nose, madarosis and few hypoaesthetic patches.All fingers and toes were intact, no evidence of autoamputation.No thickened nerves were palpable. Local examination of the left knee joint showed no skin lesions over there, restricted joint movements and no swelling or local rise in temperature. Other joints of the body did not reveal any abnormality. Ophthalmic examination revealed 6/6 vision, there was no keratitis or coneal ulcer and no lagopthalmos. Other systems did not show any abnormality.X – ray of left knee joint showed features of Neuropathic joint. Laboratory investigations revealed anaemia, lymphocytosis and raised ESR (75 mm/hr). Rheumatoid arthritis (RA) factor was negative.

Patient underwent left knee arthrodosis. Biopsy from left knee articular cartilage and synovium were sent for histopathologcal examination.

MORPHOLOGY

Received single 0.75 cm whitish fibrofatty firm synovial biopsy along with few bony fragments labeledarticular surface biopsy, separately. Bony pieces were studied after decalcification.

MICROSCOPIC EXAMINATION

Section from left knee joint synovial biopsy showed flattened synovial tissue along with fibrofattystromahaving dense infiltrate of lymphocytes, plasma cells, histiocytes (Fig. 1) and foamy giant cells (Fig. 2).Subepithelium showed extensive hyaline deposits (Fig. 3). Occasional site showed presence of noncaseating granulomas.ZiehlNeelsen stain was negative for acid fast bacilli.

Sections from articular surface showed normal bone and chondroid morphology.

As other causes of arthritis were ruled out, the diagnosis of leprous synovitis was offered.

DISCUSSION

Leprosy is a chronic granulomatous infectious disease caused by*Mycobacterium leprae*, an acid-alcohol resistantbacillus with affinity for skin and peripheral nervecells[6], but other organs

may be affected including eyes, respiratory tract, lymph nodes, testicles and joints. There is a spectrum of clinical presentation between tuberculoid and lepromatous polewhich is dependent upon the host immune response[7]. The differential diagnosis is so wide that one has to exclude wide variety of dermatological diseases before stamping it to be leprosy as stigma is still associated to it. Even neurological conditions and lepra reactions are tobe differentiated from a number of systemic illnesses [6].

Leprosy most commonly affects knee joint followed by ankle, wrist and elbow joints[5]. There are very few case reports of Leprous synovitis.

In our case there were no skin lesions onthe knee joint,radiological and laboratory investigations ruled out other causes of Arthritis, it can be inferred that bacillemia may beresponsible for this primary synovial involvement. Dissemination of the bacilli todistant organs through the bloodstream andthe occurrence of bacillemia in leprosy hasbeen repeatedly confirmed[5]. In our case AFB was negative in the synovium, as was reported by Hollaet al[5] who observed only a small percentage (18 out of 50 cases) of AFB positivity in their study.

Lepromatous leprosy when present in unusual ways, histopathology examination is the key to diagnosis, like in ourcase.

Since leprosy is on the verge of elimination we have to be very vigilant about diagnosing leprosy and identifying it even when it is presenting in unusual ways, because delay in administration of MBMDT may increase the morbidity many folds[7].

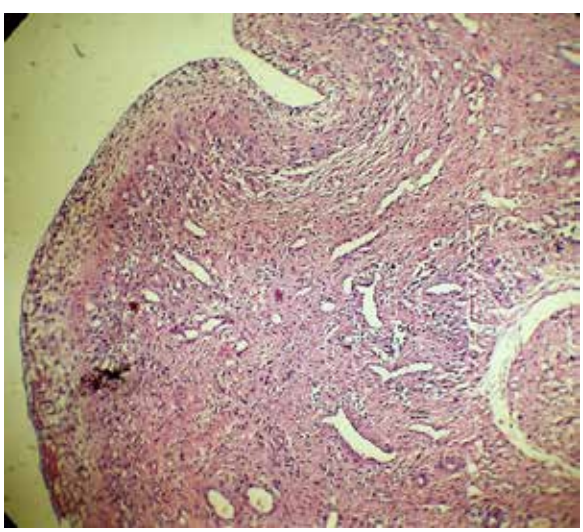

Fig. 1 shows flattened synovial lining and beneath collection of Histiocytes and Lymphocytes in fibrocollagenous stroma (H&E: 10x10)

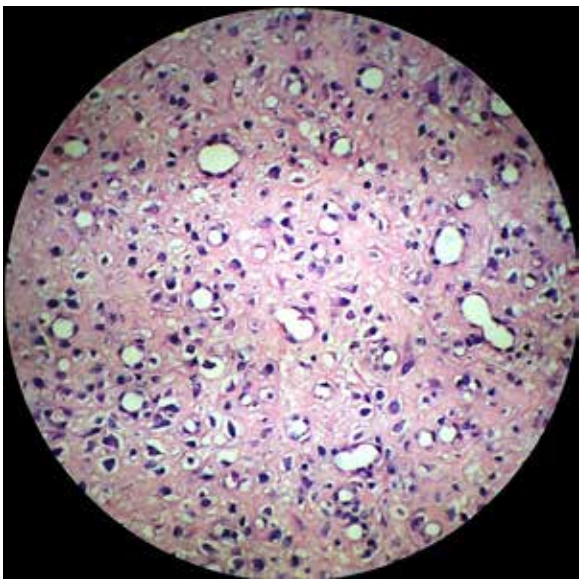

Fig. 2 shows multinucleated foamy Histiocytes with epithelioid cells (H&E: 10x40)

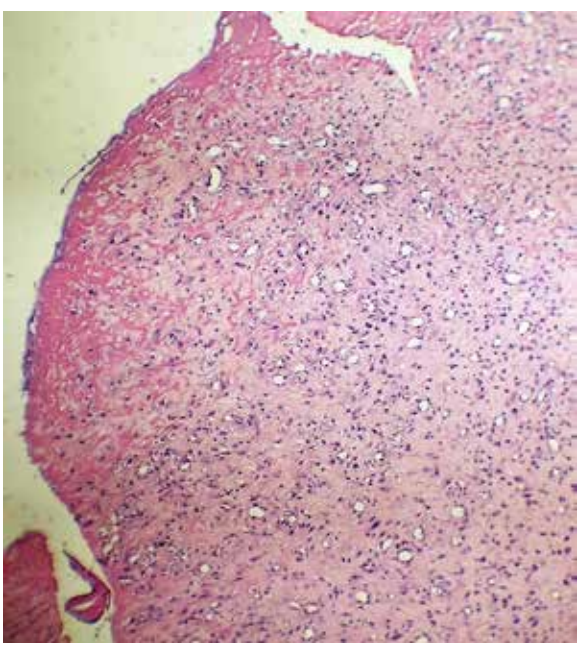

Fig. 3 shows extensive extracellular hyaline deposits beneath the synovial lining (H&E: 10x10)

REFERENCE

1. SandeepChauhan, AnupamWakhluand VikasAgarwal (2010). Arthritis in leprosy. Rheumatology .49:2237–2242. | 2. J.B. Walter, I.C. Talbot (2010). Tuberculosis, Leprosy, Syphilis and Actinomycosis. In: Walter and Israel General pathology,7thedn, Elsevier, p341 – 343. | 3. RV Mohite, VR Mohite, PM Durgawale (2013). Differential Trend of Leprosy in Rural and Urban Area ofWestern Maharashtra. Indian J Lepr. 85: 11-18. | 4. N Haroon, V Agarwal, AAggarwal, N Kumari, N Krishnani and RMisra (2007). Arthritis as presenting manifestation of pure neuriticleprosy—a rheumatologist's dilemma. Rheumatology. 46:653–656. | 5. Vasudeva V. Holla, Maneesha V. Kenetkar, Madhav K. Kolhatkar,andChandrashekhar N. Kulkarin (1983).Leprous Synovitis - A Study of Fifty Cases. IntJ Lepr. Vol 51 (1):29 – 32. | 6. RC Raval (2012).Various faces of Hansen's disease. Indian J Lepr. 84: 155-160. | 7. KD Barman, K Goel, P Agarwal, S Chukh, VK Garg, N Khurana (2013). Lepromatous leprosy with an uncommon presentation - A case report. Indian J Lepr. 85: 27-31.