ORIGINAL RESEARCH PAPER

VOLUME-6 | ISSUE-6 | JUNE-2017 | ISSN No 2277 - 8179 | IF : 4.176 | IC Value : 78.46

INTERNATIONAL JOURNAL OF SCIENTIFIC RESEARCH

# Lingual foramen in Indian mandibles

Medical Science

**Dr. Maria Kala** Professor, Department of Anatomy Malla Reddy Institute of Medical Sciences, Suraram, Hyderabad 500055, Telangana, India

**Dr. Usha Mukkera** Professor, Department of Anatomy Malla Reddy Medical college for women, Suraram, Hyderabad 500055, Telangana,India

**Dr. S.Sri Sarada Devi Sattiraju** Professor Department of Anatomy Malla Reddy Institute of Medical Sciences, Suraram, Hyderabad 500055, Telangana ,India

**Dr. Rajasree T.K** Professor & HOD Department of Anatomy Malla Reddy Institute of Medical Sciences, Suraram, Hyderabad 500055,Telangana , India

**Dr. Prashanthini Jannu** Dmo Sunshine Hospital , Secunderabad, 500003,Telangana ,India

**KEYWORDS:**

**Introduction: -** The mandible has many unnamed foramina on the lingual surface.

Ennis demonstrated a foramen located superior to the genial tubercles in1937, while Novitsky reported a foramen inferior to the genial tubercles in 1938. Suzuki & Sakai in 1957 mentioned that the bony canals of these foramina coursed perpendicular to the inner surface of mandible1. Midline foramina and lateral foramina were described .Terminology of foramina was differently used by various authors during various periods, some referred it to as lingual foramina, some described it as a central pit, whereas some of them described as unnamed foramina.

Ennis in 1937 described the content of lingual foramen as an artery, a branch of incisive artery and its anastomosis with lingual artery1. Sutton in 1974 described the structures associated as neuro vascular bundle2. X liang et al3 in their study revealed that the content of superior canal is the branch of lingual artery and lingual nerve and for the inferior canal, the arterial origin was submental/or sublingual while nerve is a branch of mylohyoid nerve. Motivated by the previous studies our present study was designed to observe the presence or absence of lingual foramina; if present, its location whether superior or inferior to genial tubercles, right para median & left paramedian, and their distance from alveolar border and inferior border of body of mandible.

**Materials & Methods:-** 100 dried mandibles were taken for study, from study material of various medical colleges, (Malla Reddy Institute of Medical Sciences, Malla Reddy Medical College for Women. Osmania Medical College & Kakatiya Medical College from telangana region). The mandibles were of both sexes and different ages.

The mandibles were differentiated as male and female mandibles by following standard text book descriptions. The lingual side of mandibles were examined for the presence or absence of foramen. If foramen was present, its location whether superior or inferior to genial tubercles and also whether foramen was paramedian to right or to left of genial tubercles or its bilateral occurrence were observed. The distance of foramen from alveolar border and also inferior border of mandible was noted.(Fig 1.) & (Fig.2).

**Observations :-** Hundred mandibles were studied. Among them 80 belong to male sex mandibles & 20 belong to female sex mandibles. They were examined for the presence or absence of foramen. Seventy mandibles showed the presence of lingual foramen. In thirty mandibles foramen was absent. The incidence of presence of foramen was 70%.

In mandibles where foramen was present; the location of foramen whether superior or inferior to genial tubercles, paramedian whether to the right or to the left of genial tubercles or bilateral was observed. The following table shows the incidence of foramen in 70 mandibles

**Table-1 showing percentage incidence of foramen.**

| Superior lingual foramen | Inferior lingual foramen | Right paramedian foramen | Left paramedian foramen | Bilateral foramen |
|---|---|---|---|---|
| 52% | 32% | 6% | 5% | 11% |

Though only hundred mandibles were examined, percentage shows more than hundered because some mandibles show more than one foramen.

The distance from the foramen to the alveolar border and to the inferior border of mandible was noted. The mean, standard deviation and 'P' values for each of them was calculated. Table -2. The 'P' value is not significant for superior lingual foramen – 0.19, extremely significant for inferior lingual foramen – 0.00, significant for right paramedian foramen – 0.0319, significant for left paramedian lingual foramen – 0.0491, and extremely significant for bilateral lingual foramen – 0.001.

**Tabe -2 showing mean, standard deviation 'P' values and significance.**

| | No. of Mandibles | Distance from Alveolar border | | Distance from Inferior border | | P - Value | Significance |
|---|---|---|---|---|---|---|---|
| | | Mean | Standard. deviation | Mean | Standard. Deviation | | |
| Superior Lingual foramen | 52 | 1.6 | 0.46 | 1.5 | 0.27 | 0.19 | Not significant |
| Inferior Lingual foramen | 32 | 2.2 | 0.58 | 0.7 | 0.29 | 0.00 | Extremely significant |
| Right paramedian Lingual foramen | 6 | 1.7833 | 0.53448 | 1.1333 | 0.35024 | 0.0319 | significant |
| Left paramedian Lingual foramen | 5 | 2.0800 | 0.58907 | 1.1800 | 0.63797 | 0.0491 | significant |

| | | | | | | | |
|---|---|---|---|---|---|---|---|
| **Bi lateral Lingual Foramen** | 11 | 2.1955 | 0.57278 | 0.9091 | 0.23686 | 0.001 | extremely significant |

*In one mandible there were all four, superior lingual foramen, inferior lingual foramen, right paramedian lingual foramen & left paramedian lingual foramen.13 mandibles showed three foramina, 18 mandibles showed two foramina & 38 mandibles showed single foramen.

Discussion:- Sutton 2 ; Shiller& Wiswel4 reported an incidence of presence of foramen in mandibles to be 85% and 88.9% respectively.

Donal Mcdonnell, et.al1. in their publication reported an incidence of 99.04% of lingual foramina. They did not mention their location1

X. Liang et.al3. reported an incidence of superior lingual foramen as 62% & inferior lingual foramen as 38% respectively. He observed 31 mandibles, with paramedian lingual foramen, 8 to right & 8 to left of genial tubercles; 15 were bilateral lingual foramen. The percentage of right paramedian and left paramedian lingual foramen is 25.8% each and bilateral lingual foramen is 43.8%.

Nagar M, et. al5. in their study observed the presence of lingual foramen in 72.45% of dried mandibles of both sexes. Superior lingual foramen in 55.5%, inferior lingual foramen in 5.9%, both right & left paramedian lingual foramen together in 1.6% of mandibles.

Prashant E. Natekar, et.al6 reported an incidence of superior and inferior lingual foramen of 58% & 40% respectively and incidence of right & left paramedian lingual foramen as 20% & 18% respectively.

B.V. Murlimanju et al7 noted an incidence of lingual foramen in 83.6%, superior lingual foramen in 77.6%, inferior lingual foramen in 50.7%, right lingual foramen in19.4% and left lingual foramen in 25.4%.

Dae Hyun Kim et al8 observed an incidence of lingual foramen in 58.8%, bilateral lingual foramen in 20.9%, left lingual foramen in 18.2% and right lingual foramen in 19.8%.

Seema Gupta et al9 studied an incidence of lingual foramen in 88%, inferior lingual foramen in70% and paramedian in 28%.

Nimje Dipti A and Yadav Nisha R.B.10 noted in their study superior lingual foramen in 70%, inferior lingual foramen in 4.16% and paramedian lingual foramen in 2.5%.

Yildrim Y.D. et al 11 observed single lingual foramen in 76.8%, median lingual foramen in 51.8% and lateral (paramedian) lingual foramen in 21.1%.

Sara Bernardi et al12 in their 56 CT Dental scans observed an incidence of lingual foramen in 75%, superior lingual foramen in 62% and inferior lingual foramen in 13%.

Ahmet Ercan Sekerci et al13 observed midline lingual foramen in 95.2% and left paramedian lingual foramen 15.7%.

In our study , the incidence of lingual foramen is 70%,,incidence of superior lingual foramen is 52% & inferior lingual foramen is 32% , right paramedian lingual foramen is 6%, left paramedian lingual foramen is 5% and bilaterally occurrence in 11% .

The incidence of presence of lingual foramina and the incidence of superior lingual foramina is in concurrence with the study of Nagar M et al.

The incidence of inferior lingual foramina is close to the study of X. Liang. et al.

Farida Abesi et al14 observed by using cone beam computerized tomography in 200 patients that there is one lingual foramen in 39.5%, two lingual foramina in 53% and three lingual foramina in 75%.

Yildrim Y.D. et al11 noted single lingual foramen in 76.8%.

Sara Bernardi et al12 observed in their study one lingual foramen in75% and two lingual foramina in 23%.

Henrique Ayres de Vasconcellos et al15 noted in their study one lingual foramen in 60.35%, two lingual foramina in 34.4% and three lingual foramina in 5.17%.

In our study, the percentage incidence for single lingual foramen is 54.28% , two lingual foramina in 25.71%, three lingual foramina in 18.57% and all four lingual foramina in 1.42%. These parameters are not coinciding with parameters of other workers. It may be due to the earlier workers not mentioning the incidence of two foramina, three foramina and four foramina in relation to genial tubercles in their study and also due to geographical variation and variation in population characteristics . We would like to make further studies in more detail in different population.

**Table – 3 showing results of studies by different authors**

| S. no. | Author | Year | Incidence of presence of foramina | Superior lingual foramina | Inferior lingual foramina | Right paramedian lingual foramina | Left paramedian lingual foramina | Bilateral foramina |
|---|---|---|---|---|---|---|---|---|
| 1 | Shiller W.R. and Wiswell | 1954 | 88.9% | NS | NS | NS | NS | NS |
| 2 | Sutton R.N | 1974 | 85% | NS | NS | NS | NS | NS |
| 3 | Donal Mc Donnell et al | 1994 | 99.04% | NS | NS | NS | NS | NS |
| 4 | Nagar M et al | 2001 | 72.45% | 55.5% | 5.98% | Both right & left together 1.6% | NS | |
| 5 | X. Liang. et al | 2007 | NS | 62% | 38% | 25.8% | 25.8% | 48.38 % |
| 6 | Prashanth E Natekar et al | 2011 | NS | 58% | 40% | 20% | 18% | NS |
| 7 | B.V.Murlimanju et al | 2012 | 83.6% | 77.6% | 50.7% | 19.4% | 25.4% | NS |
| 8 | Dae Hyun Kim et al | 2013 | 58.8% | NS | NS | 19.8% | 18.2% | 20.9% |
| 9 | Seema Gupta et al | 2013 | 88% | NS | 70% | Lateral spinous 28% | NS | |
| 10 | Yildrim Y.D. et al | 2014 | 76.8% (Single foramina) | Median Lingual foramina51.8 % | Lateral Lingual foramina 21.1% | NS | | |
| 11 | Sara Bernardi et al | 2014 | 75% | 62% | 13% | NS | NS | NS |
| 12 | .Nimje Dipti A and Yadav Nisha R.B. | 2014 | NS | 70% | 4.16% | Lateral lingual foramina2.5% | --- | |
| 13 | Present Study | 2015 | 70% | 52% | 32% | 6% | 5% | 11% |

NS – Not Studied

**Conclusion:-** In our study we made an attempt to categorize the presence or absence of foramen on the lingual surface of mandible in relation to the genial tubercles, they were above or below the genial tubercles and if paramedian ,their presence to right or to left of the genial tubercles. Their distance from the borders of the mandible was measured. This study may be of help for dental surgeons. Since the foramen contains an arterial branch from sublingual artery or an anastomotic branch and fine nerve branches from lingual or mylohyoid nerve, its knowledge is essential for local anaesthetic injections, reconstructive surgery of chin and in implant surgeries. To avoid injury to neurovascular contents of foramen, prior radiographs and ultra sound Doppler test are required to study the distribution of neurovascular bundle to chin. This will prevent complications after surgery like bleeding and neurosensory disturbances.

Acknowledgments:- I sincerely thank the Directors, Dean, Professor & HOD, teaching & non-teaching staff of the department.

**Figure:- 1**

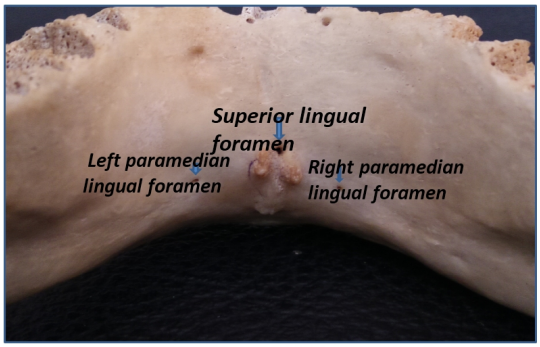


**Figure:- 2**

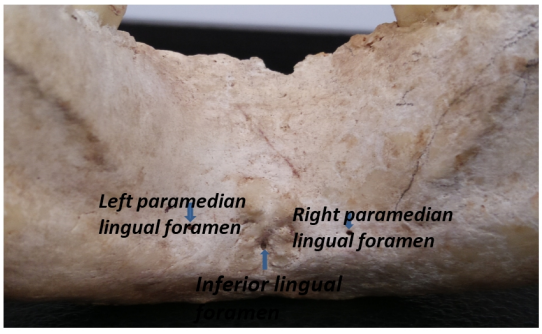


**References:**

1. Donal Mc Donnell, M. Reza Nouri and Marye E. Todd (1994) The mandibular lingual foramen: a consistent arterial foramen in the middle of the mandible. J. Anat.184 pp 363-369.
2. Sutton R.N.(1974) The practical significance of mandibular accessory foramina Australian dental journal 19: 167-173.
3. X. Liang, R. Jacobs, I.Lamrichts, and G. Vandewalle(2007) Lingual Foramina on the Mandibular Midline Revisited: A Macroanatomical Study. Clinical Anatomy 20: 246-251.
4. Shiller W.R. and Wiswell. O.B. (1954): Lingual Foramina of the mandible. Anatomical Record 119: 387-390.
5. Nagar M, Bhardwaj R, and Prakash R (2001) Accessory Lingual Foramen in Adult Indian Mandibles. J.Anat. Soc. India 50(1) 13-14.
6. Prashanth E Natekar, Fatima M De Souza, Priyanka Natekar (2011) Variations in position of lingual foramen of the mandible in reconstructive surgery. Indian J. Otol, 17: 12-13.
7. Murlimanju B V, Prakash K G, Samiullah D, Latha V Prabhu, Mangala M Pai, Rjanigandha Vadgaonkar, Rajalakshmi Rai (2012) Accessory neurovascular foramina on the lingual surface of mandible: Incidence, topography, and clinical implications. Indian Journal of Dental Research 23:3, pp 433.
8. Dae Hyun Kim, Moon Yong Kim, Chul-Hwan Kim (2013) Distribution of the lingual foramina in mandibular cortical bone in Koreans. J Korean Assoc Oral Maxillofac Surg 39: 263-268.
9. Seema Gupta, Anshu Soni, Poonam Singh (2013) Morphological study of accessory foramina in mandible and its clinical implication. Indian Journal of Oral Sciences 4:1, pp12-16.
10. Nimje DA , Yadav NRB, (2014) Lingual foramen around genial tubercle in adult human mandibles. International Journal of Anatomy Physiology and Biochemistry 1(3): pp 6-8.
11. Yildirim YD, Guncu GN, Galindo-Moreno P, Velasco-Torres M, Juodzbalys G, Kubilius M, Gervickas A, Al-Hezaimi K, Al-Sadhan R, Yilmaz HG, Asar NV, Karabulut E, Wang HL, Tozum TF (2014) Evaluation of mandibular lingual foramina related to dental implant treatment with computerized tomography : a multicenter clinical study. Implant Dentistry 23:1, pp57-61.
12. Sara Bernardi, Claudio Rastelli, Cinzia Leuter, Roberto Gatto , Maria Adelaide Continenza(2014) Anterior Mandibular Lingual Foramina: An In Vivo Investigation. Anatomy Research International 2014(2014):906348.
13. Sekerci A.E., Sisman Y, Payveren M.A, (2014) Evaluation of location and dimensions of mandibular lingual foramina using cone beam computed tomography. Surgical and Radiological Anatomy36: 857.
14. Farida Abesi, Maryam Ehsani, Sina Haghanifar, Sina Sohanian (2015) Assessing the Anatomical Variations of Lingual Foramen and its Bony Canals with CBCT. International Journal of Sciences: Basic and Applied Research 20:1,pp220-227.
15. Henrique Ayres de Vasconcellos, Antonio Eduardo de Siqueira Campos, Gerson Hayashi de Almeida, Mey Lie Tan Maia, Pedro Henrique Barros de Vasconcellos (2000) The Anatomy of the Lingual Foramen Canal and its Related to the Mandibular Symphysis. Revista chilena de anatomia 18:1, Temuco 2000.