ORIGINAL RESEARCH PAPER

Volume-7 | Issue-5 | May-2018 | PRINT ISSN No 2277 - 8179

INTERNATIONAL JOURNAL OF SCIENTIFIC RESEARCH

LUMBAR SPINAL CANAL MEASUREMENTS BY MAGNETIC RESONANCE IMAGING (MRI) IN INDIAN POPULATION

Radiodiagnosis

Dr. Bukke Ravindra Naik PG Resident Radiodiagnosis, Sri Devaraj Urs Medical College, SDUAHER, Kolar, Karnataka, India.

Dr. Athira P M* PG Resident Radiodiagnosis, Sri Devaraj Urs Medical College, SDUAHER, Kolar, Karnataka, India. *Corresponding Author

Dr. Anil Kumar Sakalecha Professor Radiodiagnosis, Sri Devaraj Urs Medical College, SDUAHER, Kolar, Karnataka, India.

Dr. Shivaprasad G Savagave Assistant Professor Department of Radiodiagnosis, Sri Devaraj Urs Medical College, SDUAHER, Kolar, Karnataka, India.

ABSTRACT

Introduction:
Lumbar spinal canal stenosis is the progressive narrowing of spinal canal that causes compression of nerve roots. Magnetic resonance imaging (MRI) is commonly used to assess patients with lumbar spinal canal stenosis. The aim of the study is to determine the normal sagittal and transverse diameter of the lumbar spinal canal and depth of the lateral recess in asymptomatic population by using MR imaging of the lumbosacral spine and to arrive at a reference lower limit of normal values at each level.

Materials and Methods:
This study was conducted on one hundred and five patients. MRI scan was performed on 1.5 T scanner. Measurements were performed on T1-weighted and T2-weighted fast spin echo sequences in axial and sagittal planes.

Results:
In our study narrowest mid sagittal diameter was at L4-L5 (10.9 mm) in males and L5-S1 (10.8 mm) females. There is no significant difference noted in the mid sagittal diameter and transverse diameter between males and females. Lateral recess depths showed a significant difference between the two groups at L2-L3 on right side and L4-L5 on left side.

Conclusion:
The mean values for the normal spinal canal diameters (SCD) and lateral rescess depth in our population are similar to data from other literature.

KEYWORDS

Lumbar spinal canal, MRI, canal stenosis.

Introduction

Lumbar spinal canal stenosis is the commonest location of spinal canal stenosis and can cause compression of spinal cord or the spinal nerves. Patients with spinal canal stenosis may present with bilateral lower extremity pain, numbness and weakness, whichis usually associated with low back pain[1].

Magnetic resonance imaging (MRI) is currently considered the best imaging method to investigate back pain. Various conditions may be responsible for back pain such as disk degeneration, central canal stenosis, metastases, spinal compression fractures[2].

The normal transverse and anteroposterior diameters differ at various lumbar spinal canal levels in individuals of the same race and are differentat identical levels in individuals of different races[3].

Evaluation of average standard measurements of the spinal canal of normal subjects helps to establish baseline measurement of spinal canal dimensions[3]. This will help to identify patients who have lumbar spinal canal stenosis[5]. Anatomically, lumbar spinal canal stenosis could be involved in the central canal, lateral recess, foramina or any combination of these locations. Some radiological studies have reported that the changes in the anterior-posterior (AP) diameter, transverse diameter and cross-section area (CSA) of the spinal canal and dural sac are risk factors for developing spinal stenosis[3].

There is paucity of data on the normal values of spinal canal diameters in lumbosacral spine among Indian population[3,6].

The purpose of the study is to measure transverse and sagittal diameter of the lumbar vertebral canal and depth of the lateral recess among South Indians. It is intended that the results obtained from this study will help establish standard reference range for lumbar canal diameters in this population and thus helps to identify patients with lumbar canal stenosis.

Objectives:

1) To determine the sagittal diameter of the lumbar spinal canal and depth of the lateral recess in asymptomatic subjects by MR imaging.
2) To arrive at reference lower limit of normal values at each level.

Materials & Methods

Design of study –
This was a retrospective observational study. As the study was retrospective in nature, informed consent may be waived off. No patient identifiable information will be disclosed.

Sample size:
The study was approved by the ethical committee. A minimum of 105 asymptomatic individuals (males – 43; females - 62) aged between 20 to 70 years were included in the study with a population of completed spinal development.

Mode of selection of subjects –
This study was conducted at the Department of Radio-Diagnosis at "R. L. Jalappa Hospital & Research Center", attached to Sri Devaraj Urs Medical College, in the period between July 2017 to March 2018. Asymptomatic patients referred for MRI pelvis/spine for complaints unrelated to low back symptoms was taken for this study till the sample size is achieved. Antero-posterior and transverse diameters of lumbar spinal canal and depth of lateral recess will be obtained from the MR Images. The normal lumbar spinal canal ranges between 15-27 mm diameters. Antero posterior diameter of less than 10 mm is definitive stenosis[1,6]. Narrowing of the lateral recess is caused by facet arthrosis, usually in combination with hypertrophy of the flavum ligament and bulging of the disc. Lateral recess stenosis is present when the distance between the superior facets antero-medially and the posterior vertebral body margin is less than 4 mm[7].

Asymptomatic individuals referred for MRI pelvis, hip cervical spine with whole spine screening for complaints unrelated to low back symptoms were included in the study. Exclusion criteria were imaging

abnormality related to spine (e.g., spondylolisthesis, tumours and Pott's disease), lumbar vertebrae fracture and previous spinal surgery.

Equipment / technique

All subjects underwent MRI examination of the lumbar spine. The MRI was performed with 1.5 Tesla MR Scanner (Siemens® Magnetom Avanto®). Standard protocols were followed for the study. Measurements were performed on T1-weighted and T2-weighted fast spin echo sequences in axial and sagittal planes. First lumbar vertebra to first sacral vertebra was studied. At each level, the antero posterior and transverse diameters of the lumbar vertebral canal were measured in axial and sagittal planes as shown in Figures 1 & 2. The measurements were recorded in millimetres.



Figure 1: Sagittal T2 weighted magnetic resonance image showing spinal canal diameter at various levels.

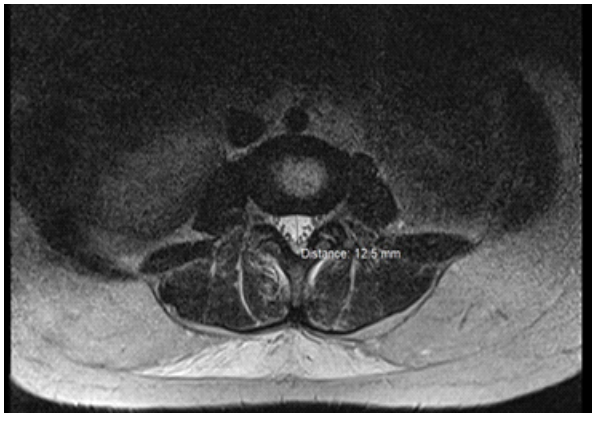

Figure 2: Axial T2 weighted magnetic resonance image showing transverse canal diameter.

Data analysis

All the collected data were numerically coded and entered in Microsoft excel worksheet. All the descriptive data expressed in terms of mean and standard deviation. The analyzed data will be presented in the form of tables. This means that patients exhibiting SCD values lower than cutoff value have to be considered for stenosis.

Results

The mean mid sagittal (antero-posterior) diameter of lumbar spinal canal from L1-L2 to L5-S1 shows that there was no significant difference in the both males and females at each level (P>0.05). The narrowest mid sagittal diameter was at L5-L5 (10.9 mm) in males and L5-S1 (10.8 mm) females. The mean cutoff values from L1-L2 to L5-S1 (95% CI) were listed in the table 1.

Table 1. Sagittal spinal canal diameter (mean + standard deviation).

AP Diameter		Male		Female		
	Level	Mean (mm)	SD	Mean (mm)	SD	
	L1-2	12.8	1.206	13.2	1.2000	*P = 0.096; NS
	L2-3	12.2	1.454	12.5	1.3530	*P = 0.28; NS
	L3-4	11.6	1.974	10.9	1.9598	*P = 0.07; NS
	L4-5	10.9	1.858	11.0	1.7562	*P = 0.779; NS
	L5-S1	11.1	1.680	10.8	1.9757	*P = 0.41; NS

SD = standard deviation; NS = not significant; *2-tailed independent t test performed; no significant difference among males and females

The mean transverse diameter in millimetres from L1-L2 to L5-S1 also shows no significant difference in the both males and females at each level (P> 0.05). There was a gradual decrease in size noted in the from L1-L2 to L5-S1. The mean values were shown in the table 2.

Table 2. Transverse diameter of the lumbar spinal canal (mean + standard deviation).

Transverse Diameter		Male		Female		
	Level	Mean (mm)	SD	Mean (mm)	SD	
	L1-2	14.4	1.493	14.0	1.6961	*P = .3845; NS
	L2-3	13.7	1.533	13.3	1.3313	*P = .3103; NS
	L3-4	13.7	2.304	13.7	1.7937	*P=.073; NS
	L4-5	12.6	1.676	13.2	1.2431	*P=0.385;NS
	L5-S1	12.6	1.591	12.9	1.8475	*P=0.636,NS

SD = standard deviation; NS = not significant; *2-tailed independent t test performed

There was a significant difference noted in the mean measurements of lateral recess depth on right side at L2-L3 (P = 0.039) and on left side at L4-L5 (P = 0.0011) between the males and females shown in the tables 3 & 4.

Table 3. Table shows lateral rescess depth (in mm) on right side.

Lateral recess right side		Male		Female		
	Level	Mean	SD	Mean	SD	
	L1-2	4.2674	1.7081	3.6516	1.3772	*P=0.054;NS
	L2-3	3.4814	1.3632	3.3548	1.0281	*P=0.039;S
	L3-4	2.8767	0.9810	2.7710	0.9297	*P=0.693;NS
	L4-5	3.0000	0.7416	2.8790	0.7018	*P=0.682;NS
	L5-S1	2.9302	0.8620	2.9548	0.8275	*P=0.724;NS

SD = standard deviation; S = significant; NS = not significant; *2-tailed independent t test performed

Table 4. Shows lateral rescess depth (in mm) on left side.

Lateral recess left side		Male		Female		
	Level	Mean	SD	Mean	SD	
	L1-2	4.0070	1.6130	3.5500	1.3626	*P=0.13;NS
	L2-3	3.3721	1.3436	3.2581	0.9933	*P=0.642;NS
	L3-4	2.8256	0.8696	2.5355	0.8932	*P=0.100;NS
	L4-5	2.9907	1.0134	2.7919	0.6436	*P=0.0011,S
	L5-S1	2.7047	0.6821	2.8597	0.8283	*p=0.0506;NS

SD = standard deviation; S = significant; NS = not significant; *2-tailed independent t test performed

Discussion

In our study we evaluated the values of the normal sagittal and transverse diameter of the spinal canal, depth of the lateral rescess in asymptomatic adult population. We determined the mean values for normality in a population of normal subjects measuring these parameters. This study was aimed to provide quantitative data to

radiologists and clinicians community, to obtain more accurate diagnoses rather than qualitative criteria. It is important to quantify the stenosis rather than visual inspection. In the day to day clinical practice, the accurate knowledge of the normal lumbar spinal canal measurements is of extreme importance since a reduction of its size predisposes to back pain and spinal canal stenosis. In patients with lumbar canal stenosis MRI is used as a confirmation tool[8].

Many studies were carried out for this purpose, indicating a large variability of threshold values for the maximum and minimum diameter of the spinal canal in different populations[8]. Currently MRI has become investigation of choice to assess the lumbar canal stenosis as it is non-invasive, with no radiation risks and gives overview of spine along with its soft-tissue components.

In congenital vertebral stenosis, the transverse diameter can be normal whereas the sagittal diameter is reduced because of thickening of the laminae and articular processes and sometimes because of short pedicles[9]. The use of the antero-posterior diameter of vertebral canal in clinical practice was recommended by Delphi Survey study[10].

In order to identify normal and abnormal sagittal diameter of the spinal canal many studies were carried out on X-rays, computed tomography & MRI and concluded that the minimum sagittal diameter of the spinal canal was found ranging between 11 and 15 mm[10,11,12,13].

In our study narrowest mid sagittal diameter was at L4-L5 (mean 10.9 mm) in males and L5-S1 (mean 10.8 mm) females and widest mid sagittal diameter was 12.8 mm in males and 13.2 mm females at L1-L2. There is no significant difference between males and females in the mid sagittal diameter. This means that patients exhibiting SCD values lower than cutoff values at each level have to be considered for stenosis.

Our results were consistent with the study done by Deep S. Chatha and Mark E. Schweitzer also the narrowest level was at L5-S1 and widest at L1-L2[17].

In our study, there was significant difference in the mean measurement of lateral recess depths between males and females at L2-L3 on right side and L4-L5 on left side.

The findings of this study were compatible with other studies of Bolender et al[14], Beers et al[15], Schonstrom et al[16], where lateral recess was studied though not in central spinal canal stenosis entity.

Conclusion

With this study we determined the mean values for the normal SCD and lateral rescess depth are similar to the given literature. The accurate and quantitative definition of the normal range for these measurements may allow the radiologists to obtain more accurate diagnoses and speeding up the timing of the diagnosis.

Financial support and sponsorship

Nil.

Conflicts of interest

There are no conflicts of interest.

References

1. Anasuya G, Jayashree A, Moorthy N.L.N, Madan S. Anatomical study of lumbar spinal canal diameter on MRI to assess spinal canal stenosis. Int J Anat Res 2015, 3(3):1441-44. ISSN 2321-4287.
2. Roudsari B, Jarvik JG. Lumbar spine MRI for low back pain: Indications and yield. AJR Am J Roentgenol. 2010;195:550–9.
3. PawarI, Kohli S, Dalal V, KumarV, Narang S, SinghalA.Magnetic resonance imaging in the diagnosis oflumbar canal stenosis in Indian patients. J Orthop Allied Sci 2014;2:3-7.
4. J.P.-Y. Cheung et al. /Verification of measurements of lumbar spinal dimensions in T1- and T2-weighted magnetic resonance imaging sequences. Spine J. 2014;14(8):1476-83.
5. Modic MT, Ross JS. Magnetic resonance imaging in the evaluation of low back pain. OrthopClin North Am 1991;22:283–301.
6. Ahmad T, Goel P, Babu CSR. A study of lumbar canal by MRI in clinical symptomatic and asymptomatic subjects. J AnatSoc India 2011;60:184-7.
7. Pawar et al. MRI in the diagnosis of lumbar canal stenosis in Indian patients. Journal of Orthopedics and Allied Sciences 2014;2(1): 3–7.
8. Andreisek G, Hodler J, Steurer J. Uncertainties in the diagnosis of lumbar spinal stenosis. Radiology. 2011;261:681–4.
9. Verbiest H. Results of surgical treatment of idiopathic developmental stenosis of the lumbar vertebral canal. A review of twenty-seven years' experience. J Bone Joint Surg Br. 1977;59:181–8.
10. Mamisch N, Brumann M, Hodler J, Held U, Brunner F, Steurer J, et al. Radiologic criteria for the diagnosis of spinal stenosis: Results of a Delphi Survey. Radiology. 2012;264:174–9.
11. Haig AJ, Geisser ME, Tong HC, Yamakawa KS, Quint DJ, Hoff JT, et al. Electromyographic and magnetic resonance imaging to predict lumbar stenosis, low-back pain, and no back symptoms. J Bone Joint Surg Am. 2007;89:358–66.
12. Kalichman L, Cole R, Kim DH, Li L, Suri P, Guermazi A, et al. Spinal stenosis prevalence and association with symptoms: The Framingham Study. Spine J. 2009;9:545–50.
13. Chatha DS, Schweitzer ME. MRI criteria of developmental lumbar spinal stenosis revisited. Bull NYU HospJt Dis. 2011;69:303–7.
14. Bolender NF, Schonstrom NS, Spengler DM. Role of computed tomography and myelography in the diagnosis of central spinal stenosis. J Bone Joint Surg Am 1985;67:240-6.
15. Beers GJ, Carter AP, Leitern BE, Tilak SP, Shah RR. Interobserver discrepancies in distance measurements from lumber spine CT scans. AJR Am J Roentgenol 1985;144:395-8.
16. Schonstrom NS, Bolender N, Spengler DM. The pathomorphology of spinal stenosis as seen on CT scans of the lumbar spine. Spine (Phila Pa 1976) 1985;10:806-11.
17. Chatha DS, Schweitzer ME. MRI criteria of developmental lumbar spinal stenosis revisited. Bull NYU Hosp Jt Dis 2011;69:303-7.