ORIGINAL RESEARCH PAPER

Volume-7 | Issue-8 | August-2018 | PRINT ISSN No 2277 - 8179

INTERNATIONAL JOURNAL OF SCIENTIFIC RESEARCH

LUPUS VULGARIS: A RARE CASE OF CUTANEOUS TUBERCULOSIS

Pathology

Dr. Mustaque Ahmad Ansari Associate professor, Department of pathology, Rajendra Institute of Medical Sciences, Ranchi, Jharkhand

Dr. Md. Alimuddin Ansari* Junior Resident, Department of Pathology, Rajendra Institute of Medical Sciences, Ranchi, Jharkhand * Corresponding Author

Dr. Bankim Chandra Adhikari Professor, Department of pathology, Rajendra Institute of Medical Sciences, Ranchi,

Dr. Safi Nayaj Ansari Junior Resident, Department of Dermatology, Rajendra Institute of Medical Sciences, Ranchi, Jharkhand

ABSTRACT

Lupus vulgaris, the commonest form of tuberculosis of the skin, presents with a plaque that enlarges slowly with advancing edges while showing atrophy at other areas. Cutaneous Tuberculosis makes a small proportion of extra Pulmonary tuberculosis and has considerable morphological variability. The earliest description of lupus vulgaris was given by Erasmus Wilson in 1865. It often confused with various cutaneous disorders and some other granulomatous processes of skin. We present a case of a 20 year female who was diagnosed as lupus vulgaris clinically and histopathologically she had demarcated, irregularly bordered, pink, infiltrated plaques on right side of her back below scapular region showing "apple jelly nodule" on diascopy. The histopathological examination shows tuberculoid granuloma with langhan's type giant cells .The lesion shows marked improvement on anti-tubercular drugs.

KEYWORDS

Cutaneous Tuberculosis, Lupus Vulgaris, Tuberculoid Granuloma, Anti Tubercular Drugs.

INTRODUCTION

Cutaneous tuberculosis is the manifestation of extrapulmonary tuberculosis that is quite common among the people living in low socioeconomic status. Lupus vulgaris is most common form of cutaneous tuberculosis which is chronic and progressive form acquired either exogenously by direct inoculation of bacilli into the skin or endogenously by hematogenous or lymphatic spread from a underlying infected host with a moderate to high degrees of mycobacterium tuberculosis [1]. In Europian countries head, neck and face is most commonly involved but in Indian continent trunk, buttock and thigh are most common sites. A characteristic feature of lupus vulgaris is its extremely chronic courses with slow but steady growth of lesion over a period of many years.

CASE REPORT

We present a case of 20 year old female residing in village with irregularly bordered, pink, infiltrated plaques on right side of her back since 5 years below scapular region [Fig1]. The plaque was asymptomatic and started as a small 1–2cm red flat lesion and gradually enlarged. There was no history of preceding trauma. The patient had occasionally consulted medical care for the lesion and taken oral and topical medications, but noticed no improvement. Diascopy reveals an "apple jelly nodule". Skin biopsy was taken from the involved site. Histopathology shows flattened epidermis with tuberculoid type granuloma in dermis included langhans type giant cells and small foci of fibrinoid necrosis [Fig2]. Investigations revealed normal blood counts and an elevated erythrocyte sedimentation rate (72 mm/1st hr). Chest radiography was normal. Fungal elements were also negative on potassium hydroxide mount. BCG vaccination scar is present on her. On Ziel Nielson staining no acid fast bacillus was found, favours lupus vulgaris. Based on the clinical findings and lab evaluation, a diagnosis of lupus vulgaris was made and antitubercular therapy was started. The patient was follow-up for three month. After three months of antitubercular treatment there was almost total healing of the lesions [Fig3].



Fig1: Clinical photograph showing large plaque on right side of her back before treatment

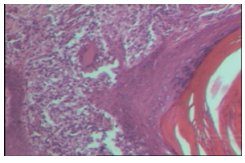

Fig2: Skin biopsy showing hyperplastic epidermis, dermis showing noncaesating epithelioid granulomas with langhans type of giant cells



Fig3: Clinical photograph after 3 months of treatment

DISCUSSION

Lupus vulgaris is an extremely chronic progressive form of cutaneous tuberculosis. The earliest description of lupus vulgaris was given by Erasmus Wilson in 1865 [2]. It generally occurs through contiguous extension of disease from underlying affected tissue or hematogenous or lymphatic spread. It can also arise after exogenous inoculation or as complication of BCG vaccination [3]. The initial lesion is a small, reddish brown papule or nodule which later forms larger plaques by peripheral enlargement and coalescence that show evidence of healing and scarring in one area and activity in another [4]. Atrophic scarring with or without ulceration is prominent feature of lupus vulgaris. Histopathological examination showed tuberculoid granulomas composed of lymphocytes, plasma cells, epithelioid cells and giant cells, scant or absent central necrosis in the dermis. Morphological patterns include ulcerative, mutilating, vegetative, tumour-like, papular and nodular forms [5]. The epidermis is usually hyperplastic but may be atrophic or ulcerated. Tubercle bacilli are difficult to demonstrate [6]. Being paucibacillary, smear or culture are usually negative and the diagnosis relies on microscopic pathology.

CONCLUSION

Cutaneous Tuberculosis makes a small proportion of extra Pulmonary tuberculosis. Studies from south east Asia reported an incidence of 0.1% of all cases of extra pulmonary tuberculosis [7]. In this reported case the patient had extensive involvement of large sized, multiple plaques occurring at unusual site which was confirmed by histopathological study and marked improvement after Anti tubercular therapy.

References

1. Valia RG, Valia AR, editors. IADVL Textbook of Dermatology. 3rd ed, vol 1. Mumbai, India: Bhalani Publishing House; 2008. p. 245-6.
2. Findlay GH. Bacterial infections. In: Findlay GH,editors. The Dermatology of Bacterial infections. 1 st ed. London: Blackwell Scientific; 1987. p. 71-83.
3. Kanwar AJ. Lupus vulgaris following BCG vaccination. Int J Dermatol 1988; 27:525-6.
4. Marcoval J, Servitje O, Moreno A, et al. Lupus vulgaris: Clinical, histopathologic, and bacteriologicstudy of 10 cases. J Am Acad Dermatol 1992; 26:404-407
5. Sacchidanand S, Sharavana S, Mallikarjun M, et al. Giantlupus vulgaris: A rare presentation. Indian Dermatol Online J 2012; 3: 34–36.
6. Jain VK, Aggaral K, Jain S, Singh S. Hypertrophic lupus vulgaris: An unusual presentation. Indian J Dermatol 2009; 54:287-9.
7. Sehgal VN, Wagh SA. Cutaneous tuberculosis. Int J Dermatol 1990; 29:237-52.