Original Research Paper

VOLUME-6 | ISSUE-4 | APRIL - 2017 • ISSN No 2277 - 8179 | IF : 4.176 | IC Value : 78.46

Magnetic Resonance Imaging in a patient with Möbius Syndrome

Ophthalmology

KEYWORDS: Möbius Syndrome, Magnetic resonance imaging

Shinji Makino

Department of Ophthalmology, Jichi Medical University, Shimotsuke, Tochigi, Japan

ABSTRACT

We present magnetic resonance imaging (MRI) in a 5-year-old girl with Möbius syndrome. MRI revealed abnormal brainstem morphology with flattening of the floor of the fourth ventricle. In addition, axial T2-weighted MRI were performed to assess the cranial nerves. The oculomotor, the trigeminal, the facial, and the auditory nerves were normal bilaterally. In contrast, the left abducens nerve was detected, but the right abducens nerve was absent.

INTRODUCTION

Möbius syndrome is a rare disease characterized by a unilateral or bilateral non-progressive congenital facial palsy with impairments of ocular abduction; it also is associated with other cranial nerve palsies, orofacial dysmorphism, and limb or axial malformations.[1] The minimum criteria include congenital facial palsy with impairment of ocular abduction.

Previous radiological studies in patients with sporadic Möbius syndrome have identified brainstem hypoplasia and the universal finding of complete absence of facial nerves.[1-4] Verzijl et al.[4] concluded that these abnormalities support the idea that Möbius syndrome is part of a global anomaly of the posterior fossa.

Herein, we present magnetic resonance imaging (MRI) in a 5-year-old girl with Möbius syndrome.

CASE PRESENTATION

A 5-year-old girl with convergent strabismus was referred to our clinic. She was diagnosed as Möbius syndrome on the basis of the characteristic neurological findings observed in the pediatric clinic. In this paper, we will only describe MRI findings.

MRI revealed abnormal brainstem morphology with flattening of the floor of the fourth ventricle (Fig 1 arrows). In addition, axial T2-weighted MRI were performed to assess the cranial nerves (CNs). The oculomotor (CN III, Fig 2A yellow arrows), the trigeminal (CN V, Fig 2B yellow arrows), the facial (CN VII, Fig 2D yellow arrows), and the auditory (CN VIII, Fig 2D blue arrows) nerves were normal bilaterally. In contrast, the left abducens nerve (CN VI, Fig 2C yellow arrows) was detected, but the right abducens nerve was absent. In addition, convergent eye deviation was confirmed on images (Fig 2C, D).



Fig. 1 Sagittal T2-weighted MRI
Note straightening of the floor of the fourth ventricle (arrows).

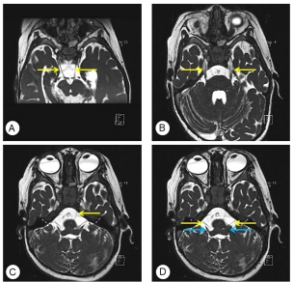

Fig. 2 Axial T2-weighted MRI
Arrows indicate the oculomotor (A), the trigeminal (B), the abducens (C), the facial (D), and the auditory (D blue) nerves.
Note the right abducens nerve was absent.

DISCUSSION

The radiologic features of Möbius syndrome are variable, ranging from normal findings to variable degrees of hypoplasia of the brainstem, prevailing in the region of the pons.[1-4] MRI findings include brainstem hypoplasia and characteristic flattening of the floor of the fourth ventricle, which may be attributed to the absence of facial and abducens colliculi.

In this present case, right abducens nerve was absent. Park et al.[5] reported the first case of the coexistence of Duane's retraction syndrome accompanied by unilateral Möbius syndrome. In their report, MRI revealed the absence of bilateral abducens nerves and the left facial nerve.

CONCLUSIONS

Although our findings were based on a single case of Möbius syndrome, they may contribute to a better understanding of this condition.

REFERENCES:

[1] Carta, A., Mora, P., Neri, A., Favilla, S., and Sadun, A.A. (2011)" Ophthalmologic and systemic features in Möbius syndrome. An italian case series." Ophthalmology, 118, 1518-1523.
[2] Hsu, C.C., Singh, D., and Kwan, G.N. (2015) "Möbius syndrome: comprehensive assessment of facial palsy and oculomotor deficits with magnetic resonance imaging." Pediatric Neurology, 53, 466-467.
[3] Dumars, S., Andrews, C., Chan, W.M., Engle, E.C., and Demer, J.L. (2008)" Magnetic resonance imaging of the endophenotype of a novel familial Möbius-like syndrome." Journal of American Association for Pediatric Ophthalmology and Strabismus, 12, 381-389.
[4] Verzijl, H.T., Valk, J., de Vries, R., and Padberg, G.W. (2005)" Radiologic evidence for absence of the facial nerve in Möbius syndrome." Neurology, 64, 849-855.
[5] Park, C., Kim, J.H., and Hwang, J.M. (2012) "Coexistence of Möbius syndrome and Duane's retraction syndrome." Graefes Archives of Clinical Experimental Ophthalmology, 250, 1707-1709.