Research Paper

Volume : 4 | Issue : 6 | June 2015 • ISSN No 2277 - 8179

Malignant Middle Cerebral Artery Infarction; indications and outcome of Decompressive Craniectomy

Medical Science

KEYWORDS : decompressive craniectomy, brain herniation, middle cerebral artery infarction, outcome

Dr. Ramanjulu M	Associate Professor of Neurosurgery, Kurnool Medical College, Government General Hospital, Kurnool
Dr. Venkateswara Rao C	M.S. Assistant professor, Department of Neurosurgery Kurnool Medical College Kurnool, Andhra Pradesh, India
Dr. Ananth M. L	M.Ch. Assistant professor, Department of Neurosurgery Kurnool Medical College Kurnool, Andhra Pradesh, India
Dr.Ram Balaji Naik G	M.Ch. Assistant professor, Department of Neurosurgery Kurnool Medical College Kurnool, Andhra Pradesh, India

ABSTRACT

Background: Malignant cerebral infarction is a well recognized disease, comprising 10-15% of all cases with cerebral infarction and causing herniation and death in 80% of cases. Several studies reported an improved outcome in patients presenting with malignant cerebral infarction treated by decompressive craniectomy. In this study we are reviewing the indications and neurological outcome in patient with malignant cerebral infarction after decompressive craniectomy and the literature reviewed.

Methods: This retrospective study included 30 patients who underwent decompressive craniectomy after malignant cerebral infarction between January 2010 and April 2015 at Department of Neurosurgery Government General Hospital Kurnool, Andhra Pradesh, India. Clinical neurological presentation was evaluated using the Glasgow Coma Scale (GCS) and the modified Rankin Scale (mRS). The infarct territory was evaluated by CT scan and in some cases by MRI. Demographic characteristics included preoperative clinical condition, timing of surgery, cause, location, extent of cerebral infarction, time delay from the onset of symptoms to surgery and preoperative signs of herniation and their relation to the final outcome were analyzed. All patients underwent decompressive craniectomy in addition to routine aggressive medical care. Patient outcome was assessed using Glasgow outcome scale and mRS score on discharge and follow-up examination.

Results: There were 24 males and 6 females, with mean age 54 years. The preoperative clinical condition according to median GCS score was of 5.5.Median mRS score on admission was 5. The time in hours to surgery after onset of symptoms was 6 to 48 hours with mean of 24 hours. .Twelve patients (36%) underwent early surgery (within 24 hours) and 21(66%) suffered non dominant stroke .Glasgow outcome scale score averaged more than 3. Median mRS score was 1.5 at follow-up examination. The overall mortality was 36% (12 patients).12 patients had favourable outcome (mRS<3)

Conclusions: Decompressive craniectomy is safe and effective method that can be life saving in patients with malignant cerebral infarction and decrease mortality rate, improve neurological and functional outcome and decrease the long-term disability in these patients

Introduction

Territorial middle cerebral artery infarcts are the most devastating forms of ischemic cerebral disease. It is associated with life threatening cytotoxic oedema, with mortality as high as 80%. The Malignant infarction is defined as an infarction of at least two thirds of MCA territory upward[1]. The incidence of malignant cerebral infarction is 10 to 20 per100000 per year[2]. The aetiology of the majority of these infarcts is cardio embolic or thrombotic occlusion of the internal carotid artery or the proximal segment of the middle cerebral artery (MCA) [3]. Patients with a malignant MCA territory infarction have hemi paresis, hemiplegia, hemi sensory loss, homonymous hemianopia contra lateral to the site of infarction, forced gaze deviation towards the non affected hemisphere and depressed level of awareness. Non dominant hemispheric infarctions are associated with visual, motor and sensory neglect .Language disturbance such as fluent, non fluent, and mostly global aphasia are typical for infarctions localized to the dominant hemisphere. The first sign of neurological decline is nausea and vomiting followed by drowsiness, and papillary asymmetry. This combination of neurological findings yields a National Institute of Health Stroke Scale (NIHSS) score of >15 for a right hemisphere infarction and >20 for left hemisphere infarction. Death occurs within 5 days as a result of brain death in the majority of patients, cardiac arrhythmias and arrest, sepsis, recurrent stroke, and pneumonia. The conventional therapies for MCA infarction are mechanical ventilation, osmotherapy, and hypothermia and barbiturate administration. Decompressive craniectomy (DC) appears to reduce mortality in patients presenting with Malignant MCA infarction to 20% .Patients aged over 60 years and patients with speech dominance on the infarcted cerebral hemisphere may have poorer outcome

Clinical material and methods

All the 30 patients who underwent decompressive craniectomy after malignant cerebral infarction between January 2010 and March 2015 at Department of Neurosurgery Government General Hospital Kurnool, Andhra Pradesh, India are included in this study. Clinical neurological presentation was evaluated using the Glasgow Coma Scale and the modified Rankin Scale (mRS).The infarct territory was evaluated by CT scan and in some cases by MRI. Demographic characteristics included preoperative clinical condition, cause, location, extent of cerebral infarction, time delay from the onset of symptoms to surgery and preoperative signs of herniation and their relation to the final outcome were analyzed. All patients underwent decompressive craniectomy in addition to routine aggressive medical care. Patient outcome was assessed using Glasgow outcome scale (GOS) [4] and modified Rankin scale[5] within three months of follow up. All patients underwent CT immediately prior to surgery .Criteria for surgery included initial CT findings consistent with a large or malignant MCA infarction (early large parenchymal hypodensity of more than two thirds of the MCA territory) and signs of local brain swelling such as effacement of sulci and compression of the lateral ventricle and deterioration of level of consciousness. Medical treatment included fluid haemostasis with crystalloid perfusion and standard antioedema treatment such as osmotherapy. Potential risks and benefits were discussed with the relatives of the patient .Decompressive craniectomy with a bone flap with a diameter of at least 12 cm was performed including the frontal temporal parietal and part of occipital bone. After dural incision a dural patch was applied to allow adequate brain relaxation. The bone was removed and kept in the subcutaneous fat in the right iliac fossa until reimplanta-

tion 3 to 6 months later. Post operatively patients were kept intubated and mechanically ventilated. Clinical outcome was assessed by the modified Rankin scale, and GOS during follow-up. Patients were followed up regularly on outpatient basis after discharge from hospital.

Results

A total of 30 patients are included in this study, there were 24males and 6 females, with mean age of 54 years. In all patients at least two thirds of the MCA territory was infarcted preoperatively. The median preoperative GCS score was 5.5. Median mRS score on admission was 5. The duration of symptoms was 1 to 3 days with mean of 1 day. Mean midline shift was >5 mm in 18 patients in pre-operative CT scans. The interval between admission and surgery was 6-48 hours with a mean of 24 hours (Table 1).6 patients (18%) underwent early surgery (within 24 hours) and 21 suffered non dominant stroke. The mean follow up period was 9 months. Stroke aetiology was cardio embolic in 14 patients. The mean duration of hospitalization was 28 days. 12 out of 30 patients died despite aggressive medical and surgical decompression (36%), the cause of death in all patients was intractable intracranial pressure due to infarction process progression. Glasgow outcome scale score is more than 3 at follow-up. Outcome in modified Rankin scale was 1.5. The overall mortality in our series was 36%. The overall surgical complications with the procedure were 24%. In 4 patients post operative infection was diagnosed. In two patients post operative haematoma was diagnosed and evacuated (Table 2).one patient developed hydrocephalus for which ventriculoperitoneal shunt was done .one patient had inadequate decompression. Studies in several cohorts of patients (Table 3) with malignant cerebral infarction have shown the DC can reduce the mortality to less than 50%.our observations confirmed this view, as the overall mortality in our series was 36 %.

Table 1: A summary of demographic clinical and radiological parameters

Number of patients	30
Mean age	54
Sex(male-female)	24-6
Median GCS at admission	5.5
Laterality(right-left)	21-9
hypertension	10
Diabetes mellitus	8
smoking	10
Aetiology of stroke ; Cardio-embolic unknown	14 16
aphasia	15
Midline shift > 5mm	18
Time to surgery	mean 24 hours

Table 2: Analysis of outcome

Number of patients	30
Outcome in GCS scale	3
Outcome in MRS scale	1.5
Mortality	36%
Complications rate ; Inadequate decompression Infection Post operative subdural haematoma Hydrocephalus	25% 1 4 2 1
Rate of survival	18/30(54%)

Table 3.Descriptive studies (without control group)

study	No. of patients	Average age	No. of survivors	No. With Glasgow Outcome Scale score 4-5
Fujita 1982	10	-	8	7
Tsuruno 1983	15	63	10	4
Sakai1998	24	64	16	-
Mania 2000	20	17	13	-

Table 4.summary of randomized clinical trials

Study, year	No. of patients	A g e , years	Mortality (%)		Good outcome (%)	
			surgical	medical	surgical	medical
DESTINY2007	32	18-60	17.6	53.0	47.0	27
DECIMAL	38	18-55	25.0	77.8	50.0	22.2
HAMLET2009	64	18-60	22.0	59.0	25.0	25.0
Pooled analysis 2007	93	18-60	75.0	29.0	75.0	24.0

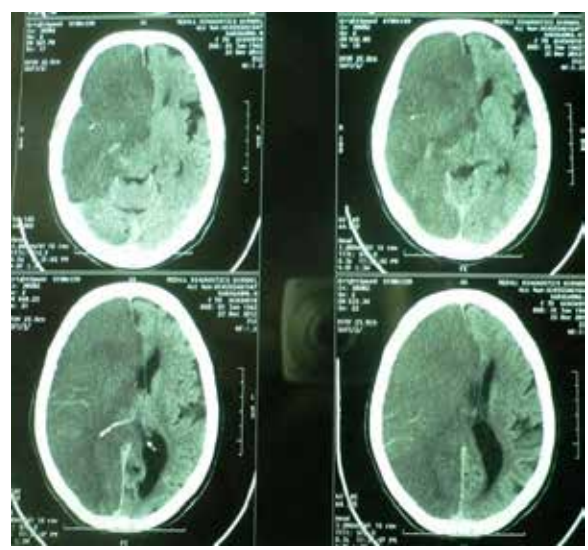

Figure;1. CT scan brain showing large right MCA territory infarction with mass effect and compression of the ventricular system

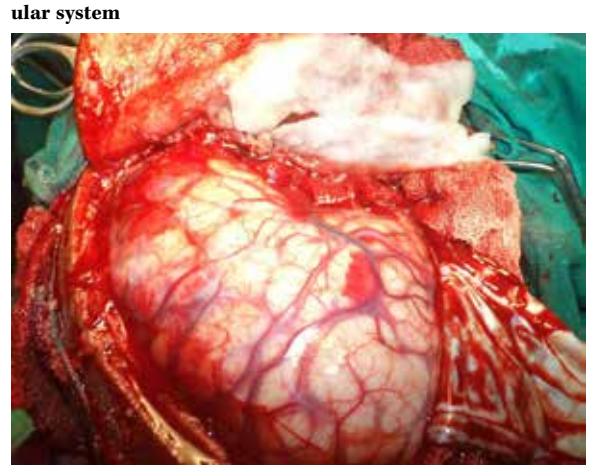

Figure ;2.Introperative photograph showing pale infarcted area of the brain

Volume : 4 | Issue : 6 | June 2015 • ISSN No 2277 - 8179

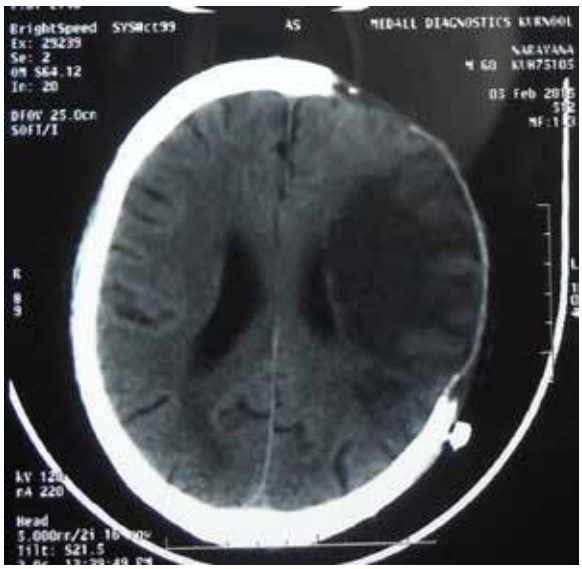

Figure 3.CT scan in a 54 year old male patient who underwent decompressive craniectomy for large MCA infarction. Note the large bone removal and the right hemisphere occupying the new free space

Discussion

Hemicraniectomy has been used to treat brain swelling and the mass effect secondary to middle cerebral artery infarction, hemispheric encephalitis and large parenchymal intracerebral hemorrhage. The procedure was first described in 1905 by Harvey Cushing[6] and was first utilized for massive cerebral infarction in 1956.The rationale of the decompressive craniectomy treatment modality consists of opening the skull and removal of the bone flap to allow the oedematous brain to swell outward, thereby preventing intracranial tissue shifts and life threatening downward herniation, relieving ventricular and vascular compression. It is also believed to improve cerebral perfusion pressure, increase retrograde flow in MCA, preserve cerebral blood flow and prevent further ongoing ischemia.Recently 10% of the ischemic strokes are classified as malignant or massive because of the presence of space-occupying cerebral oedema that is severe enough to produce elevated intracranial pressure and brain herniation. The most reliable predictors of a malignant course of large hemispheric strokes are infarctions of more than 50% of the MCA territory and a perfusion deficit of more than 66% on CT as well as stroke volume in diffusion weighted imaging (DWI) of greater than 145 ml within 14 hrs and 82 ml within 6 h of symptom onset[2, 7]. Intracranial pressure monitoring of greater than 25 mm of Hg has been used despite attempts at medical therapy as an indicator for surgical intervention .On CT parenchymal hypodensity in greater than 50% of the MCA territory is highly indicative of a progressive clinical course, leading to morbidity or death. At 32 hrs after the occurrence of cerebral infarction a shift of the third ventricle greater than 4 mm was indicative of fatal outcome. Diagnosis by CT was accurate in only 33% of patients[8] while the accuracy of DWI to detect malignant MCA infarction was 100% within 6 hrs of onset. Age is an important factor to consider in patient selection for surgery. Individuals aged 50 years and younger have been identified as benefiting more from decompressive craniectomy. These brains are less atrophied, allowing less room for oedematous expansion within the cranial vault. The ventricular system in younger persons is smaller than in older persons and the oedematous response to ischemia is greater in younger individuals[9]. Recently three separate studies investigated the effectiveness of the decompressive craniectomy after malignant cerebral infarction in controlled trials with patients less than 61 years of age[10,11,12,13,14] .Generally patients with malignant infarction deteriorate after 48 hrs from oedema formation and death usually occurs in most patients within 72 hours to 96hours due to transtentorial herniation[15, 16].Surgery can be considered in patients with dominant hemisphere infarction ,especially if some residual language function is present at admission[17,18].Involvement of the MCA territory only likely provides the best prognosis. If the anterior cerebral artery territory is additionally involved, outcomes may markedly different because of an involvement of the medial frontal lobe .Personality change; abulia and dysexecutive syndromes are symptoms which interact substantially with the capacity of family support to function well and can result in very poor long term outcomes. If the posterior cerebral artery (PCA) territory is additionally involved, vision and reading add additional disability.PCA involvement may lead to temporal lobe infarction with subsequent uncal hernation.[19]

DC involves removal of bone from one side of skull measuring roughly 13 cm in the antero-posterior dimension and from the floor of the middle cranial fossa to at least 9 cm superiorly and simultaneously performing a generous dural opening[20]. Craniectomy size in diameter larger than 12 cm is recommended. Doubling the diameter from 6 to 12 cm potentially increases the decompressive volume 9 to 86 ml[21].The initial ICP values of 25 to 60 mm of Hg decreased by 15 % when bone flap was removed and by 70% once the dura was opened resulting in normalization of the ICP after surgery[22]. A decrease of ICP allows an increase in cerebral perfusion pressure, aiding blood flow to the ischemic penumbra[23] and optimizing circulation to the damaged area through collateral vessels. Cranioplasty is usually performed after six weeks to six months of surgery .The outcome of DC is quoted from French DECIMAL, (DEcompressive Craniectomy In MALignant middle cerebral artery infarcts),German DESTINY (DEcompressive Surgery for the Treatment of malignant INfarction of the middle cerebral arterY); and Dutch HAMLET (Hemicraniectomy After Middle cerebral artery infarction with Life threatening EdemaTtrial) trials[24,25] .The survival is improved from 29% with medical treatment to 78% resulting in absolute risk reduction (ARR) of 30%.Among survivors the good functional outcome (modified Rankin Scale (mRS) score< 4) is increased from 24% to 75% with absolute risk reduction of 51%. The American HeADDFIRST study[26] (Hemicraniectomy And Durotomy upon Deterioration From Infarction Related Swelling Trial) AND Philippine HeMMI trial (Hemicraniectomy for Malignant Middle cerebral artery Infarcts) have include quality of life as a outcome measure. A pooled analysis of the 3 randomized controlled trials proved that hemicraniectomy is a life saving procedure in a favourable functional outcome when offered early to younger patients[27, 19](Table 4)

Decompressive craniectomy is not exempt from surgery related complications and morbidities.Wagner[4] at al reported that 41% of patients had surgical complications. Complications include inadequate decompression, infection, haemorrhage, and development of contra lateral fluid collections, postoperative epidural and subdural haemorrhage as well as hygromas has occurred. The paradoxical cerebral oedema after DC is attributed to possible reduction in the interstitial pressure within the brain after decompression resulting in a greater hydrostatic pressure gradient between the intravascular and interstitial spaces.[28] Delayed sinking flap syndrome which is due to sub atmospheric pressure, irritation of neural parenchyma at bone edges and adhesion of brain to subcutaneous tissue. It may result in headaches, seizures and focal neurological deficits and is typically cured by replacement of bone flap. Similarly hydrocephalus may develop in delayed fashion. This retrospective analysis of patients of patients undergoing decompressive craniectomy after malignant MCA infarction shows similar reduction in mortality when compared to other series.

Conclusion

Space occupying oedema after large hemispheric infarctions is difficult to control with conservative intensive medical management. Decompressive craniectomy confers clear benefit to patients presenting neurological deteriorated malignant MCA infarction and secondary oedema. Current evidence indicates that majority of survivors have favourable outcome including speech function, most patients live with moderate to severe disability. The relatives of the patients should be explained clearly the possibility of survival with disability before offering the surgery. Early craniectomy based on radiographic and clinical criteria, but before signs of brain stem herniation, has been proposed as a means of improving outcomes.

10. Acknowledgements

I thank Professor Dr. W. Seetharam. M.ch. professor of neurosurgery , Dr.O.Joji Reddy M.D., Professor and H.O.D of radiology department for their suggestions and Dr.G.Rama Prasad M.D., Principal and Dr. J.Veera swamy M.Ch., superintendant Government General Hospital Kurnool for permitting to verify the hospital records.

REFERENCE

1. Hacke W, Schwab S, Horn M, et al .Malignant middle cerebral artery territory infarction; clinical course and prognostic signs. Arch Neurol 1996; 53:309-315. | 2. Hofmeijer J, Algra A, Kappelle LJ, van der Worp HG .Predictors of life threatening brain oedema in middle cerebral artery infarction. Cerebrovasc Dis.2008; 25:176-184. | 3. Heisius T, Bougousslavsky J, Van Melle G. Large infarcts in the middle cerebral artery territory .Aetiology and outcome patterns .Neurology 1998; 50; 341-350 | 4. Jennett B, Bond M, Assessment of outcome after severe brain damage. Lancet 1975; 1:480-4 | 5. Bonita R, Beagleholr R .Modification of Rankin Scale; recovery of motor function after stroke .Stroke 1988; 19:1497-1500 | 6. Cushing H .The establishment of cerebral hernia as a decompressive measure of inaccessible brain tumours; with the description of intermuscular methods of making the bone defect in temporal and occipital regions. Surg Gynecol 1; 297-314; 1905 | 7. Katja E.Wartenberg . Malignant cerebral artery infarction. Curr Opin Crit Care 2012.18:152-163. | 8.von KUMMER ,Meyding Lamade U, Forsting M.et al .Sensitivity and prognostic value of early CT in occlusion of the middle cerebral artery trunk .AJNR 15;9-18 .1994 | 9. Kondziolka D, Fazl M; Functional recovery after decompressive craniectomy for cerebral infarction .Neurosurgery 23 143-147.198822. | 10.Hofmeijer J, Kappelle LJ, Algra A, Amelink GJ ,van Gijn J, van der Worp HB ,et al. Surgical decompression for space occupying cerebral infarction (the Hemicraniectomy After Middle Cerebral Artery infarction with Life -threatening Edema Trial [HAMLET]) .A multicentric open randomized trial Lancet Neurol.2009 April ;8(4):326-33. | 11. Murthy J M K .Outcome following decompressive hemicraniectomy craniectomy in malignant middle cerebral artery infarct. Does age matter? Neurol India; 2012; 60:365-366. | 12.Juttler E ,Schwab S, Schmiedek P, Unterberg A, Hennerici M, Woitzik J, et al . Decompressive surgery for the treatment of malignant infarction of the Middle Cerebral Artery (DESTINY); A randomized controlled trial.Stroke 2007 Sep; 38(9): 2518-25. | 13 A.K.Reddy,V.Saradhi,M.Panigrahi,T.N.Rao,A.K.Meena. Decompressive craniectomy for stroke indications and results. Neurol India; 50 (suppl. 1) ;S66-S69. | 14.Vahedi K, Vicaut E, Mateo J, Kurtz A, Orabi M, Guichard JP, et al .A sequential design ,multicenter randomized controlled trial of early decompressive craniectomy in malignant middle cerebral artery infarction(DECIMAL Trial) Stroke 2007 Sep ;38(9):2506-17. | 15. Quereshi A I .et al. Timing of neurological deterioration in massive middle cerebral artery infarction; a multicentric review. Crit Care Med 31; 272-277(2003) | 16. Bounds JV, Weibers DO, Whisnant JP.et al; Mechanism and timing of deaths from cerebral infarction Stroke 12;474-477 .1981 | 17 .Amandeep Kumar, Manish Singh Sharma ,Bhawani Shanker Sharma, Rohit Batia , Manmohan Singh, Ajay Garg, et al . Annals of Indian Academy of Neurology 2013 volume 18 issue 4 pages 509-515. | 18. Schwab S, Steiner T, Aschoff A, et al .Early hemicraniectomy in patients with complete middle cerebral artery infarction .Stroke 29; 1888-1893.1998 | 19.Suresh Subramanian, MD MSc and Michael D, Hill MD., MSc. FRSC. Decompressive craniectomy for malignant middle cerebral artery infarction .The Neurologist volume 15 number 4 July 2009 | 20. Rengachary SS, Batnitzky S, Moranz, et al; Hemicraniectomy for acute massive cerebral infarction .Neurosurgery 8:321-328.1981 | 21.Wagner S, Schnippering H, Aschoff A., Koziol JA, SchwabS, Steiner T. Suboptimum hemicraniectomy as a cause of additional cerebral lesions in patients with malignant of the middle cerebral artery l infarctions. J Neurosurg 2001; 94:693-696. | 22.Jourdan C, Convert J, Mottolese C, et al .Evaluation of the clinical benefit of decompressive hemicraniectomy in intracranial hypertension not controlled by medical treatment . Neurochirurgie 1993, 39:304-319 | 23. Reike K, Schwab S, Krieger D. Et al. Decompressive surgery in space occupying hemispheric infarction; results of an open prospective trial. Crit Care Med 23; 1576-1578.1995 | 24. Dhaval Shukla ,Amit Agarwal. Decompressive craniectomy for acute stroke; the good, the bad, and the ugly of it. Romanian Neurosurgery 201 4 XXI 3:345-348. | 25. Huttner HA, Schwab S, Malignant cerebral artery infarction; Clinical characteristics, treatment strategies and future perspectives .Lancet Neurol 2009; 8; 949-958 | 26. Frank J .Hemicraniectomy and durotomy upon deterioration from infarction related swelling trial (HeADDFIRST) .First public presentation of the primary study findings. Neurology 2003, 60 Suppl I; A 426 | 27. Early decompressive surgery in malignant infarction of the middle cerebral artery; a pooled analysis of three randomized controlled trials .Lancet Neurol 2007; 6:215-22 | 28. Honeybul S, Ho KM. Long term complications of decompressive craniectomy after head injury. J. Neurotrauma 2011; 28:929-935 |