ORIGINAL RESEARCH PAPER

Volume-7 | Issue-5 | May-2018 | PRINT ISSN No 2277 - 8179

INTERNATIONAL JOURNAL OF SCIENTIFIC RESEARCH

MANAGEMENT OF MANDIBULAR SECOND MOLAR WITH RADIX ENTOMOLARIS AND REVERSE CANAL ANATOMY.

Dental Science

Dr.Pritesh Kisanlal Agrawal.* Master of Dental Surgery In Conservative Dentistry and Endodontics Senior Lecturer, Department Of Conservative Dentistry and Endodontics, ACPM Dental College & Hospital ,Dhule , Maharashtra ,India.424001. *Corresponding Author

Varun R. Kunte MDS Oral Medicine & Radiology Maxillofacial Radiologist at P.H. Medical Centre, Santacruz West, Mumbai – 400054

Dr. Bhavesh Ahir MDS Conservative Dentistry and Endodontics. Reader , Department Of Conservative Dentistry and Endodontics, ACPM Dental College & Hospital ,Dhule ,Maharashtra, India.424001.

ABSTRACT

Thorough knowledge of root canal anatomy is mandatory for successful endodontic therapy. A case of rare root canal anatomy in mandibular second molar is presented here. Only one mesial canal and two distal canals were found in this case with three distinct canal orifices which were confirmed by dental operating microscope and CBCT.

KEYWORDS

Mandibular second molar, root canal anatomy, dental operating microscope, cone beam computed tomography.

Introduction:-

Success of root canal therapy depends on complete chemical and mechanical debridement of the root canal system followed by achievement of three dimensional seal both coronally and apically. Variation in root canal system is not an uncommon thing. As rightly quoted by MT Barrett; 'Of all the phases of anatomic study in the human system; one of the most complex is the pulp cavity morphology'. Hence complete knowledge of the root canal system is the prerequisite for successful treatment. One of the common causes of failure of root canal treatment is missed canal anatomy. Naked eye cannot visualize complete canal anatomy. Dental operating microscope for magnification and Cone beam computed tomography (CBCT) for three dimensional visualization have proved to be a boon in endodontics & dentistry.

Mandibular second molars usually have two roots and three root canals. However; several anatomic variations like single canal, two canals, three and four canals, five canals and C-shaped canals have been reported in the literature.[1] The mesial root in most cases has two canals (64%). Whereas the distal root almost always has one independent canal (92%).[1,2]

Here in this case report; management of the mandibular second molar with reverse canal anatomy (one mesial canal and two distal canals) and radix entomolaris is discussed. In this case dental operating microscope and CBCT were used to reinforce endodontic treatment. To our knowledge, very few cases have been reported of such anatomic variation but none had confirmed the root canal anatomy with CBCT. [3, 4,5]

Case report

A forty three year old female patient reported to our dental office with the chief complaint of severe pain in lower right posterior tooth region.She also complained of pain being referred to right ear and temporal region. There was tenderness on percussion with 47. After thorough clinical examination, intraoral periapical radiographs were made. They revealed deep proximal caries involving enamel, dentin and approaching pulp with 47(Figure 1.A). Widening of PDL space was also noted with distal root apex of 47. Final diagnosis of acute apical periodontitis was made with 47. The patient was advised root canal treatment with 47.

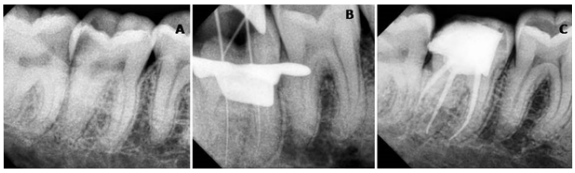

Figure 1. Intraoral radiographs: (A) preoperative; (B) working length determination; (C) postoperative.

Under local anesthesia, rubber dam was applied and endodontic access was prepared with round bur and safe-ended taper diamond point (Mani Inc, Toshigi-Ken, Japan) under dental operating microscope (Figure 2). Only one mesial and two distal canals could be located (Figure 2). Hence more dentin was removed mesiolingually in the search of second mesial canal. However no additional mesial canal could be located; even under highly magnified view of dental operating microscope. Hence CBCT was advised in order to assess root canal morphology and to confirm the presence of additional root canal if any.

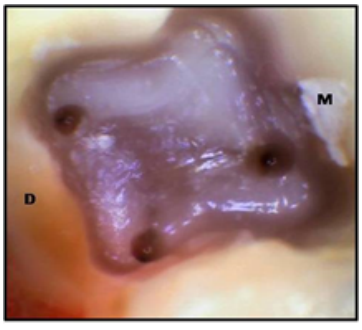

Figure 2. Clinical picture: Access opening showing one mesial (M) and two distal (D) canal orifices.

CBCT confirmed presence of a single mesial canal and 2 distal canals (Figure 3). Mesial canal begins as single canal from root canal orifice at the floor of pulp chamber and exits as single canal from apical foramen. CBCT also confirmed the presence of extra distal root i.e distolingual root. PDL space widening is seen with distolingual root. Radix showed a single root canal with no significant curvature. Working length was measured with the electronic apex locator (Root ZX mini; J Morita Co, Kyoto, Japan) and radiographic method (Figure 1.B). All the canals were prepared with hybrid instrumentation technique. Initial filing was done with hand K files (Mani Inc.) which was then followed by rotary instrumentation using ProTaper (Dentsply Maillefer, Ballaigues, Switzerland). Canals were irrigated with 5.25% sodium hypochlorite and 17 % liquid EDTA (Canalarge, Ammdent; Amrit Chemicals and Minerals Agency, Mohali, Punjab, India). In addition to copious irrigation; agitation with endoactivator was performed. Canals were then dried with paper points. Obturation was done using warm vertical compaction technique with touch & heat device & sealapex (Kerr Corporation 28200 Wick Road, Romulus, MI 48174 USA) sealer. (Figure 1.C) Post endodontic restoration was made with composite filling (Filtek Bulk Fill 3M ESPE Dental Products 2510 Conway Ave,St.Paul,MN,USA) material which was then followed by coronal coverage with full coverage crown.

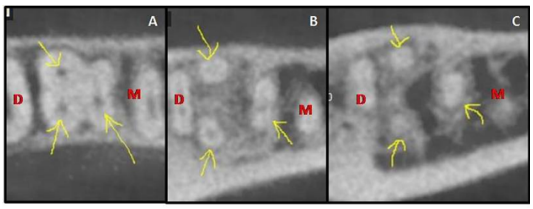

Figure 3. CBCT images: axial section at the coronal (A), midroot (B) and apical (C) level showing only one Mesial (M) and two Distal (D) canals.

Discussion:

Thorough debridement of the root canal system is essential for successful endodontic therapy. Complete knowledge of root canal anatomy and it's variations is mandatory for performing a root canal treatment. The presence of radix entomolaris (RE) in a mandibular first molar is a common occurrence in certain ethnic groups, but rare in mandibular second molar. [6] In mandibular second molar; prevalence of radix entomolaris is only 0 to 1.3%.[7]

Usually mandibular second molar has two mesial and one distal canal. It may also have one, two, three, four or five canals or C shaped canal. But there are very few cases reported with one mesial and two distal canals. R.H.Giriyappa reported a case of mandibular second molar with two roots having one mesial and two distal canals. [5]

Donald W. Wells, DDS, and William E. Bernier reported a case of mandibular second molar with only one canal which was not centrally located in mesial root and two canals which terminated in the distal root. The mesiobuccal canal was positioned distally. The distal and the apparent mesiobuccal canal were found to be associated in a Type II canal configuration. [3]

Masoud Parirokh et al reported 4 similar cases; out of which 2 were similar to case of Donald W. Wells while the other 2 were similar to that reported by R.H.Giriyappa. Unlike our case, in all the four cases, all the involved teeth had only two roots.

So, ours may be the first case of mandibular second molar presenting with both features i.e. radix entomolaris and reverse canal anatomy (one canal in mesial root and two separate canals in distal root with all the distinct orifices). Also, none of the above mentioned case reports have confirmed the canal anatomy with CBCT.

Conventional radiographs do not provide three dimensional visualization of the root canal system. This may result in incomplete cleaning and obturation leading to failure of treatment. CBCT provides accurate, high resolution & three-dimensional anatomical images for diagnosis and treatment planning of endodontic cases. [8] Hence in this case; we/authors advised CBCT images to confirm the variation in root canal anatomy. It helped us to know the exact three dimensional configurations of the canals and details about the curvature and anatomy of the extra root. This prevented unnecessary removal of dentin; in the search of another mesial canal and possible perforation was averted. The use of a dental operating microscope allows the detection of canals that have normally been difficult to recognize and treat in the absence of enhanced magnification.[9] Hence, in this case; the treatment was performed under dental operating microscope.

Root canal morphologies of mandibular second molar have been described in detail by several case reports. However; these reports have typically shown the percentage of root canals in an individual root. In cases where there is a single mesial root with a single root canal; number of root canals in distal root are difficult to predict. This justifies use of CBCT in our case. Hence, this case report is of great significance to the dentists because in most cases with single mesial root with single root canal; two distal roots with two separate root canals would not be expected. [3]

Conclusion:

It is of great importance to understand anatomic variations of root canal system for success of endodontic treatment. In teeth with variations in number and morphology of root canals; this success in turn depends upon a correct diagnosis and careful clinical as well as radiological inspection. Conventional radiographs have a limited role in diagnosis of aberrations of root canals as three-dimensional anatomy of the relatively compact root canal space is further compressed into a two-dimensional image. CBCT imaging has been used in the field of endodontics for the effective evaluation of the root canal morphology. Our case reinforces the importance of meticulous examination of the pulpal floor at high magnification under sufficient illumination of the dental operating microscope. It also highlights importance of CBCT in effective evaluation of root canal morphology. Thus; dental operating microscope and CBCT imaging are crucial in the assessment of aberrations of root canal system.

References :

1. Bala Saraswathi. K, Dr. C. Sunil Kumar, Dr. S. Datta Prasad, Jahnavi. B. Anatomical Variations in Mandibular Second Molar: A Case Series. International Journal of Health Sciences & Research. 2017 April;7 (4): 463- 467.
2. Rajeesh M K1, Gokulraj R2, Rakhee Ramdas3, Nadira K Rehman4, Muhammed Abdul Rehman5.Endodontic Management of Mandibular Second Molar with a Type II Vertucci Canal Configuration Evaluated Using Cone-Beam Computed Tomography Scanning – A Case Report. IOSR Journal of Dental and Medical Sciences. 2017 May ; 16(5) :54-57.
3. Parirok M1, VAbbottP2, YosefiMH3, Hosseini HR4.Presence of two distal and one mesial root canals in mandibular second molars: report of four cases. Iran Endod J. 2014 Summer;9(3):229-32.
4. Wells DW, Bernier WE. A single mesial canal and two distal canals in a mandibular second molar. J Endod. 1984 Aug;10(8):400-3.
5. Ramesh Halebathi Giriyappa,Kishore Kumar Majety, Bhavana Gandhi. Root canal anatomy of a mandibular second molar with a reverse anatomy. World Journal of Dentistry.2012 January – march; 3(1) :97-99
6. Hannah R1, Kandaswamy D1, Jayaprakash N2. Endodontic management of a mandibular second molar with radix entomolaris: a case report. Restor Dent Endod. 2014 May;39(2):132-6.
7. López-Rosales E1, Castelo-Baz P2, De Moor R3, Ruíz-Piñón M4, Martín-Biedma B5, Varela-Patiño P6. Unusual root morphology in second mandibular molar with a radix entomolaris,and comparison between cone- beam computed tomography and digital periapical radiography: a case report. J Med Case Rep. 2015 Sep 22;9:201
8. Lin YH1, Lin HN2, Chen CC3, Chen MS4. Evaluation of the root and canal systems of maxillary molars in Taiwanese patients:A cone beamcomputed tomography study. Biomed J. 2017 Aug;40(4):232-238.
9. Khalighinejad N1, Aminoshariae A2, Kulild JC1, Williams KA3, Wang J1, Mickel A1. The Effect of the Dental Operating Microscope on the Outcome of Nonsurgical Root CanalTreatment: A Retros pective Case- control Study. J Endod. 2017 May ;43(5):728-732.