Volume : 4 | Issue : 6 | June 2015 • ISSN No 2277 - 8179

Research Paper

Medical Science

KEYWORDS :

Management of ongoing arterial hemorrhage by transarterial embolisation following failed laparotomy: a case report.

RATNANI .R,RATNANI .D

ABSTRACT

The article presents a case report of a patient with haemorrhagic shock developing secondary to caesarean section as a complication treated by uterine arteries embolization. In obstetrics and gynecology this procedure was first described in 1979 by Brown et al. Embolization is a rapid, secure, efficient and low-invasive alternative to surgical intervention.

Introduction:

In obstetrics and gynecology, angiographic embolization has been successfully used in patients with life-threatening intractable pelvic hemorrhage when routine medical and conservative methods of bleeding control have been tried and not found effective.[1-4] Management options available to treat intractable pelvic hemorrhage include: Hysterectomy, bilateral internal artery ligation and uterine artery embolization (UAE). Since embolization preserves the uterus and avoids the hazards associated with its removal, it is emerging as a preferred technique to arrest intractable obstetrical hemorrhage. In the management of massive haemorrhage following obstetric surgeries, the risk of death is increased by a vicious cycle of hypothermia, coagulopathy and metabolic acidosis known as the triad of death. The "conventional" approach is known to reduce the mortality rate in high risk patients and is a common practice when patients develop the triad of death. The aim of conventional laparotomy is to control intra-abdominal haemorrhage. However, ongoing arterial haemorrhage after laparotomy remains a serious challenging problem. Active arterial haemorrhage could not be controlled by correction of coagulopathy and it requires an adjunctive endovascular intervention procedure such as transarterial embolisation (TAE). TAE has also been reported as a rapid and effective method for the control of retroperitoneal haemorrhage. We wish to report a similar case.

A 28 year old female was referred to us on fourth day of her caesarean section done at some centre in a state of hemorrhagic shock. On examination, her heart rate was 120/min, pulses were low volume, Blood pressure was 82/60 mm hg, she was severely pale and her skin was cold and clammy. On abdominal examination, a 30-34 week size lump was palpable which was firm to hard in consistency and uterus could not be felt seperately. On per speculum examination, her vagina was pale and mild bleeding through os was seen. Per vaginal examination revealed uterus to be well contracted although size could not be assessed. Bogginess was felt through both fornices. She was resuscitated with intravenous fluids and blood products and immediately taken up for exploratory laparotomy. On opening her abdomen, uterus was found well contracted, about 18-20 week size and sutural line was intact with occasional ooze seen through suture line. A huge hematoma was seen extending from right broad ligament extending superiorly upto the level of kidneys. No intervention could be attempted due to the size and location of the hematoma.Immediately interventional radiologist was called and she was shifted to adjoining cathlab for peripheral angiography through femoral route .Selective angiography revealed active bleeding in a branch of right internal iliac artery (Figure 1). Leaking artery was quickly embolised through glue (lipids tendocryl) and check angiogram was done . No active bleeding was seen and glue was seen nicely placed (Figure 2). Patient developed fever on day 3 of hospitalization which responded to intravenous antibiotics. There was no post procedural pain. Repeat ultrasonography on day 7 revealed right sided hydronephrosis. DJ stenting was done on right side leading to resolution of hydronephrosis (Figure 3). At 3 and 6 months of follow-up patient is doing well, her haemoglobin is 12 gm/dL, and her ultrasound is normal.

Discussion:

The role and efficacy of TAE in retroperitoneal haemorrhages is well known. Although the indication of TAE in ongoing retroperitoneal haemorrhage is clear, the decision of TAE depends on the individual attending physician's clinical judgment and this individual discretion affects the patient outcome. Various retrospective studies have showed that the clinical judgment was incorrect and TAE was delayed until haemodynamic instability and profound haemorrhagic shock occurred, resulting in deaths.[5] We tried conventional laparotomy as the primary management but it was failed due to large hematoma in situ and hence we have to ultimately take the patient for TAE, which was successful.

Uterine artery embolisation provides several advantages in an emergency, including avoidance of radical life-saving management such as hysterectomy and general

anaesthesia.[2,4] Another advantage is the ability to preserve fertility.[3] Quick, timely referral to a centre with an interventional radiology department is necessary in these cases.



Figure 1: Digital substraction angiography showing leak in a branch of right internal iliac artery

Volume : 4 | Issue : 6 | June 2015 • ISSN No 2277 - 8179

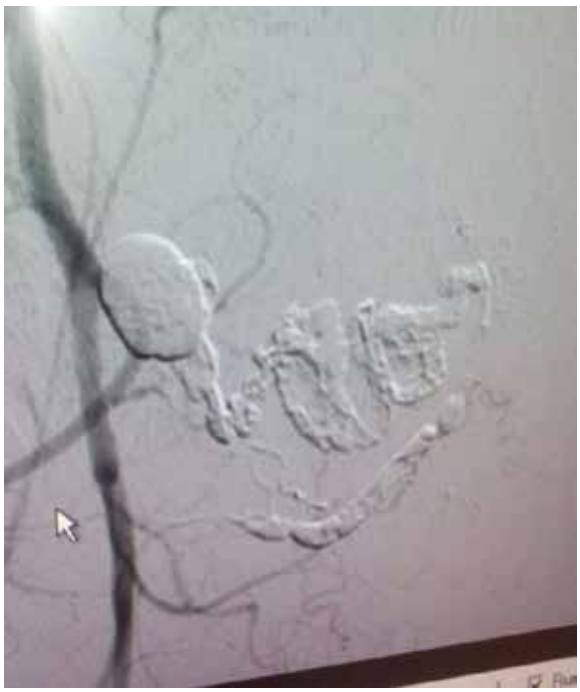

Figure 2: Digital substraction angiography showing total occlusion of vessel after injection of Lipid tendocryl



Figure 3: DJ stent in right hydronephrotic kidney

REFERENCE

1. Moatti Z, Nisner T, Saini A, Karoshi M. HYPERLINK "http://www.ncbi.nlm.nih.gov/pubmed/22674937"Delayed postpartum haemorrhage secondary to a ruptured uterine artery pseudo-aneurysm, successfully treated by transarterial embolisation. BMJ Case Rep. 2011 Dec 1;2011. pii: bcr0520114270. | 2. Chang CY, Wu MT, Shih JC, Lee CN. HYPERLINK "http://www.ncbi.nlm.nih.gov/pubmed/17197366"Preservation of uterine integrity via transarterial embolization under postoperative massive vaginal bleeding due to cesarean scar pregnancy. Taiwan J Obstet Gynecol. 2006 Jun;45(2):183-7 | 3. Tsai CC, Cheng YF, Changchien CC, Lin H. HYPERLINK "http://www.ncbi.nlm.nih.gov/pubmed/16515641"Successful term pregnancy after selective embolization of a large postmolar uterine arteriovenous malformation. Int J Gynecol Cancer. 2006 Jan-Feb;16 Suppl 1:439-41. | 4. Sugawara J, Senoo M, Chisaka H, Yaegashi N, Okamura K. HYPERLINK "http://www.ncbi.nlm.nih.gov/pubmed/15942155"Successful conservative treatment of a cesarean scar pregnancy with uterine artery embolization. Tohoku J Exp Med. 2005 Jul;206(3):261-5. | 5. Lin BC, Wong YC, Lim KE, Fang JF, Hsu YP, Kang SC. Management of ongoing arterial haemorrhage after damage control laparotomy: Optimal timing and efficacy of transarterial embolisation.Injury 2010 Jan;41(1):44-49. |