Volume : 3 | Issue : 2 | February 2014 • ISSN No 2277 - 8179

Research Paper

Medical Science

KEYWORDS : Women, Mulberry sericulture, Farmers, Knowledge, Adoption

Marfan Syndrome: an Accidental Diagnosis

T.Venkata Krishnan — Professor & HOD, Department General Medicine, Department of General Medicine, Narayana Medical College and Hospital, Chintharedy Palem, Nellore ,Andhra Pradesh.AP-India.

V. V. N. Goutham — Post Graduate Student, Department General Medicine, Department of General Medicine, Narayana Medical College and Hospital, Chintharedy Palem, Nellore ,Andhra Pradesh.AP-India.

ABSTRACT

Marfan syndrome is an autosomal dominant systemic disorder of the connective tissue. People affected by the Marfan syndrome carry a mutation in one of their two copies of the gene that encodes the connective tissue protein fibrillin-1. Marfan syndrome affects most organs and tissues, especially the skeleton, lungs, eyes, heart, and the large blood vessel that distributes blood from the heart to the rest of the body. An accidental diagnosis of Marfan Syndrome was made when the patient presented with fever to the outpatient department in Narayana Medical College and Hospital.

Introduction

Marfan syndrome is one of the most common inherited disorders of connective tissue.It is an autosomal dominant condition with a reported incidence of 1 in 3000 to 5000 individuals [1,2]. There is a broad range of clinical severity associated with MFS and related disorders, ranging from isolated features of MFS to neonatal presentation of severe and rapidly progressive disease involving multiple organ systems [3]. Although many clinicians view the disorder in terms of classic ocular, cardiovascular, and musculoskeletal abnormalities, manifestations include involvement of the lung, skin, and central nervous system.

We report one such case of Marfan syndrome which was diagnosed in our out patient department.

Description of the case

A 25-year-old male was brought to the outpatient department with complaints of fever since 4 days with chills and rigors. It is associated with burning micturition. It is not associated with cough ,headache,vomiting,rash,diarrhea .No history of any other major illness or drug abuse in the past.

On examination, he was a tall statured person.Height is 182cm and weight is 49 kg. BMI:16kg/m2.

Scoliosis+
High arched palate +
Arachnodactyly+
Pectus Excavatum+
Wrist sign+
Thumb sign+

Arm span is 196cm

Signs of aortic run off like dancing carotids +,Hill's sign +,bounding dorsalis pedis+.

No markers of rheumatic heart disease.

There was no pallor,oedema, cyanosis,clubbing, icterus and lymphadenopathy.Jvp was normal 3cm above sterna angle.

He was fully conscious and oriented. Pulse rate was 80/min, regular; BP was 100/600 mm Hg in right upper limb and Bp:130/70 in right lower limb; respiratory rate was 20/min, regular; and he was febrile with 100 degree F.

On Systemic examination :-apical impulse found in 6th interostal space ½ inch lateral to midclavicular line and hyperdynamic in nature.on auscultation s1 soft with midsystolic click best heard at apex during standing position and a high pitched blowing early diastolic murmer was heard in neo aortic area.other systems are normal.A provisional diagnosis of urinary tract infection with mitral valve prolapsed and aortic regurgitation with Marfanoid features with no signs of infective endocarditis.

Urinary tract infection was treated with antibiotics and was referred to cardio thoracic vascular surgery for further management.

Investigations	Results
Hb(g%)	13.4
TLC(cm3)	10,800
Platelet count(cm3)	2,80,000
Rbs(mg/dl)	100
Blood urea	26
Serum creatinine(mg/dl)	0.8
cue	Pus cells and bacteria
QBC for malarial parasite	negative
ASO titres	Below 200
Urine culture	E.coli
2D echo showed mitral valve prolapse with aortic regurgitation with no vegetations	
Chest xray PA view was normal.	
U/S abdomen was normal with no abnormality	

Discussion

Marfan syndrome (also called Marfan's syndrome) is a genetic disorder of the connective tissue. People with Marfan tend to be unusually tall, with long limbs and long, thin fingers.The syndrome is carried by the gene *FBN1, which encodes the connective protein* fibrillin-1[4]. Marfan syndrome is named after Antoine Marfan,[5] the French pediatrician who first described the condition in 1896.[6][7] The gene linked to the disease was first identified by Hal Dietz[8][9] and Francesco Ramirez in 1991.[10]

CRITERIA FOR DIAGNOSIS OF MFS

Revised Ghent nosology — The 2010 revised Ghent nosology puts greater weight on aortic root aneurysm/dissection and ectopia lentis as the cardinal clinical features of MFS and on testing for mutations in FBN1 and other relevant genes .

In the absence of family history of MFS, the presence of one of any of the following criteria is diagnostic for MFS:

- Aortic criterion (aortic diameter Z≥2 or aortic root dissection) and ectopia lentis*
- Aortic criterion (aortic diameter Z≥2 or aortic root dissection) and a causal FBN1 mutation as defined above
- Aortic criterion (aortic diameter Z≥2 or aortic root dissection) and a systemic score ≥7*
- Ectopia lentis and a causal FBN1 mutation as defined above that has been identified in an individual with aortic aneurysm

In the presence of family history of MFS (as defined by the above

Volume : 3 | Issue : 2 | February 2014 • ISSN No 2277 - 8179

criteria), the presence of one of any of the following criteria is diagnostic for MFS:-

- Ectopia lentis
- Systemic score ≥7 points*
- Aortic criterion (aortic diameter Z≥2 above 20 years old, Z≥3 below 20 years, or aortic root dissection)*

For criteria with an asterisk (*), the diagnosis of MFS can be made only in the absence of discriminating features of Shprintzen-Goldberg syndrome (SGS), Loeys-Dietz syndrome (LDS), or vascular Ehlers-Danlos syndrome (vEDS) and after TGFBR1/2, collagen biochemistry, or COL3A1 testing if indicated.

Systemic score — The revised Ghent nosology includes the following scoring system for systemic features :

- Wrist AND thumb sign: 3 points (wrist OR thumb sign: 1 point)
- Pectus carinatum deformity: 2 (pectus excavatum or chest asymmetry: 1 point)
- Hindfoot deformity: 2 points (plain pes planus:1 point)
- Pneumothorax: 2 points
- Dural ectasia: 2 points
- Protrusio acetabuli: 2 points
- Reduced upper segment/lower segment ratio (US/LS) AND increased arm span/height AND no severe scoliosis: 1 point
- Scoliosis or thoracolumbar kyphosis: 1 point Reduced elbow extension (≤170 degrees with full extension): 1 point
- Facial features (at least 3 of the following 5 features: dolichocephaly [reduced cephalic index or head width/length ratio], enophthalmos, downslanting palpebral fissures, malar hypoplasia, retrognathia): 1 point
- Skin striae: 1 point
- Myopia >3 diopters: 1 point
- Mitral valve prolapse (all types): 1 point

A systemic score ≥7 indicates systemic involvement.

Conclusion

The most life threatening complication of Marfan syndrome is aortic aneurysm which can lead to aortic dissection, rupture or both. Echocardiogram is recommended six months following the initial examination to determine the rate of aortic dilation and afterwards annually if aortic size is stable. In instances of aortic dilation of more than 45 mm, more frequent imaging of the aorta should be considered [11]. Management and treatment of the aorta in Marfan syndrome patients should be based on regular imaging of the aorta to evaluate its size and to determine the eventual dilation and its progression; administration of Beta adrenergic receptor antagonist therapy; and prophylactic aortic repair when aorta reaches a size that may threaten dissection or aortic regurgitation. In the pre open-heart surgery era, the average life expectancy of patients with Marfan syndrome was 45 years.

Beta blockers and ARBs are recommended in patients with Marfan syndrome mainly to delay aortic root enlargement. However, studies suggest that beta-blockers must be given early in the course of the disease, when aortic diameter has not exceeded 40 mm, in order to achieve beneficial results [12]. Prophylactic aortic root replacement in patients with Marfan syndrome is recommended when aortic diameter reaches 50 mm. Exercise restriction represents another preventive approach in patients with Marfan syndrome. Patients are recommended to avoid exhausting exercise activity, particularly isometric exercises [13].

Early recognition of clinical findings in different organ systems in patients with Marfan syndrome is of major value in order to prevent serious consequences of this disorder. Ghent criteria represent the standard for diagnosing Marfan syndrome in accordance with clinical signs and family history. Diagnosis is made if major criteria are identified in at least two different organ systems and involvement of a third organ system is noted. If family history for Marfan syndrome is positive or FBN1 mutation has been found, then a major criterion in one organ system and involvement of another organ system is necessary for diagnosis.

Image-1 (marfanoid facial features)



Image -2(arm span>height)



Image -3(pectus excavatum)

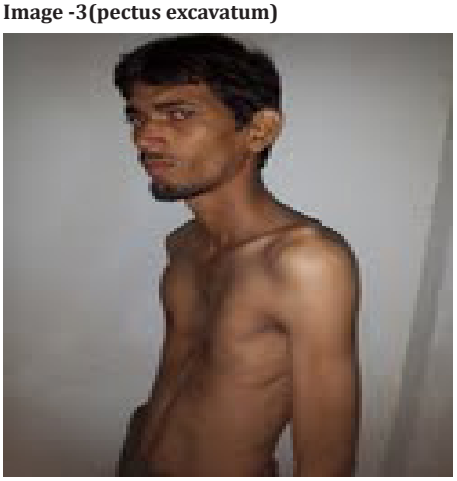

Image -4(thumb sign)



Image -5(wrist sign)



REFERENCE

1. Ramirez, F, Godfrey, M, Lee, B, et al. Marfan syndrome and related disorders. In: The Metabolic and Molecular Basis of Inherited Disease, 7th ed, Scriver, CR, Beaudet, AL, Sly, WS, et al (Eds), McGraw Hill, New York 1995. p. 4079. | 2. Judge DP, Dietz HC. Marfan's syndrome. Lancet 2005; 366:1965. | 3. Dietz HC (Updated June 30, 2009). Marfan syndrome. In: GeneReviews at GeneTest: Medical Genetics Information Resource (database online). Copyright, University of Washington, Seattle. 1997-2011. Available at file://www.genetests.org (Accessed on April 20, 2011). | 4. Kainulainen K, Karttunen L, Puhakka L, Sakai L, Peltonen L (January 1994). "Mutations in the fibrillin gene responsible for dominant ectopia lentis and neonatal Marfan syndrome". Nat. Genet. 6 (1): 64–9. | 5 .(French) Marfan, Antoine (1896). "Un cas de déformation congénitale des quartre membres, plus prononcée aux extrémitiés, caractérisée par l'allongement des os avec un certain degré d'amincissement [A case of congenital deformation of the four limbs, more pronounced at the extremities, characterized by elongation of the bones with some degree of thinning]". Bulletins et memoires de la Société medicale des hôspitaux de Paris 13 (3rd series): 220–226. | 6 .Johns Hopkins Comprehensive Marfan Center. John Hopkins Medicine. Retrieved on January 6, 2009. | 7.Antoine Bernard-Jean Marfan at Who Named It? | 8 .Dietz et al" Genomics 1991 Feb;9(2) 355-61 | 9 .Dietz et al. Nature. 1991 Jul 25;352(6333) 337-9 | 10.Brown P (July 27, 1991). "Marfan syndrome linked to gene". New Scientist. Retrieved on August 11, 2008. | 11. Milewicz DM, Dietz HC, Miller CD: Treatment of aortic disease in patients with Marfan syndrome. Circulation 2005, 111:150-157. PubMed Abstract | Publisher Full Text | 12. Shores J, Berger KR, Murphy EA, Pyeritz RE: Progression of aortic dilation and the benefit of long-term beta-adrenergic blockade in Marfan's syndrome. N Engl J Med 1994, 330:1335-1341. | 13. Braverman AC: Exercise and the Marfan syndrome. Med Sci Sports Exerc 1998, 30:S387-S395. PubMed Abstract | Publisher Full Text. |