ORIGINAL RESEARCH PAPER

Volume-6 | Issue-9 | September-2017 | ISSN No 2277 - 8179 | IF : 4.176 | IC Value : 78.46

INTERNATIONAL JOURNAL OF SCIENTIFIC RESEARCH

MECKEL'S DIVERTICULUM PRESENTING AS INTESTINAL OBSTRUCTION–EXPERIENCE OF FIVE CASES

General Surgery

Dr K M Garg PHOD, Dept of Gen Surgery JNU IMSRC, Jaipur.

Dr Manish Kr Gupta Asst Professor, Dept of Gen Surgery JNU IMSRC, Jaipur. Corresponding Author

KEYWORDS

Meckel's diverticulum; diverticulitis; Intestinal obstruction.

Introduction :

Small bowel obstruction accounts for about one-fifth of all acute surgical admissions. The etiology of small bowel obstruction includes several pathological factors, with the most common cause being postoperative adhesions followed by hernia [1]. However, in patients who present with symptoms and signs of bowel obstruction and who have had no previous abdominal surgery, or any detectable hernia on physical examination, other causes such as a Meckel's diverticulum should be considered.

A Meckel's diverticulum is a congenital pouch on the wall of the distal ileum, usually about 2 inches from the ileocecal valve. It represents a vestigial remnant of the omphalo-mesenteric duct and occurs in approximately 2% of the population, found twice as frequently in males as females. Of those individuals who have a Meckel's diverticulum, only 2% are symptomatic.

Here, we present experience of 5 cases of Meckel's diverticulum causing small bowel obstruction in adults.

Material & methods : Five cases of intestinal obstruction due to Meckel's diverticulum were operated during last 2 years at JNU hospital, Jaipur. Detailed findings are depicted in table no1.

Table no 1

Case number	Age	sex	Intra operative findings
1	14	Male	Diverticulum at anti mesenteric border of ileum 2cmx2cm, with sealed perforation
2	34	Female	Long diverticula attached to umbilical scar causing compression of ileal loop
3	22	Male	Fibrosed band from diverticulum tip to umbilicus causing band obstruction
4	36	Male	Band obstruction with volvulus
5	40	Male	Perforation peritonitis (frank) with perforation at base of diverticula.

In all five cases resection of Meckel's diverticulum along with adjoining part of ileum , and end to end ileo-ileal anastomosis was done.

Discussion:

Meckel's diverticulum is the most common congenital anomaly of the small intestine, with a prevalence of approximately 1-3%, and is a true diverticulum containing all layers of the bowel wall. Intestinal obstruction is presenting feature in about 40% of symptomatic cases of Meckel's diverticulum in adults. The most common etiology of obstruction is intussusception with diverticulum being the lead point, or a mechanical volvulus of the small intestine around a persistent fibrous band that attaches the Meckel's diverticulum to the umbilicus [2]. Obstruction has been found to occur more frequently with a giant Meckel's diverticulum [2, 3], three of our cases had giant diverticulae (photo 3). Further in three cases obstruction was caused by trapping of a bowel loop by a mesodiverticular band (photo1).

Various imaging modalities have been used for diagnosing Meckel's diverticulum. Conventional radiographic examination is of limited value. High-resolution sonography usually shows a fluid-filled structure in the right lower quadrant having the appearance of a blind-ending, thick-walled loop of bowel[4]. On computed tomography (CT), Meckel's diverticulum is difficult to distinguish from normal small bowel in uncomplicated cases. However, a blind-ending fluid or gas-filled structure in continuity with the small bowel may be revealed [5].

The main complications caused by a Meckel's diverticulum, include intussusception and volvulus in adolescents and acute bleeding in adults [4]. However, there are cases reported in the literature of a Meckel's diverticulum causing small bowel obstruction [5-7], but this predominantly occurs in adolescents where the bowel lumen is narrower and the intra-abdominal contents are more closely packed together.

The management of any acute surgical abdomen, including acute bowel obstruction, follows 4 stages:

(I) formation of an initial diagnosis, (II) confirmation of a diagnosis, (III) confirmation of the aetiology underlying the diagnosis and (IV) surgical intervention to treat the emergency.

A diagnosis of acute bowel obstruction is made initially on clinical judgment based on the history and physical examination of the patient. The cardinal symptoms and signs are colicky abdominal pain, vomiting, absolute constipation and abdominal distension. Confirmation of bowel obstruction is then usually made with a plain supine abdominal x-ray. This simple and easily performed test provides the surgeon with several useful pieces of information, including whether there is small and/or large bowel obstruction and the degree of obstruction.

Having established and confirmed a diagnosis of small bowel obstruction, the next goal is to identify the etiology underlying the obstruction. The two most common causes of small bowel obstruction in the developed world are postoperative adhesions and hernia [1]. However, no previous abdominal surgery and no hernia on physical examination, rules out both these causes.

The next imaging investigation to identify etiology is computed tomography scan with oral contrast. The result of this revealed a stricture in the terminal ileum, with dilatation of the small bowel proximal and collapse of the large bowel distal to the stricture. However the etiology of the stricture, and therefore the cause of the small bowel obstruction, remained unidentified.

Based on these findings and the absence of clinical improvement whilst on IV fluids and nasogastric tube aspiration, surgery should therefore be indicated. At laparotomy, usually a long Meckel's diverticulum is found, which managed to entirely wrap itself around the terminal ileum thereby forming an internal hernial orifice in which the bowel incarcerates and subsequently obstructs. Two of our cases were found to have perforation of Meckel's diverticulum though in one it was a sealed perforation.

In asymptomatic patients; whether all cases of incidental Meckel's diverticulum should be resected or not is an unresolved question. On the other hand, for the symptomatic patients; treatment should always include resection of the diverticulum or the segment of the bowel affected by the pathology [8, 9]

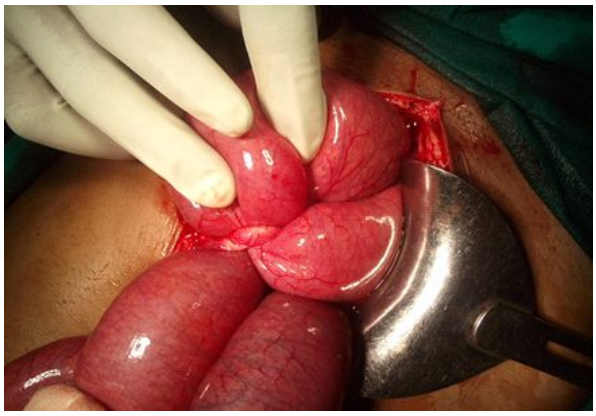

Photo 1: Internal herniation of bowel loop with compression(case2)

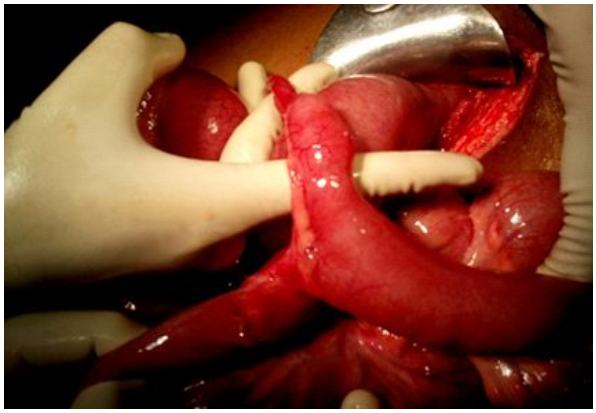

Photo 2: Meckel's diverticulum with space for internal herniation of bowel loop

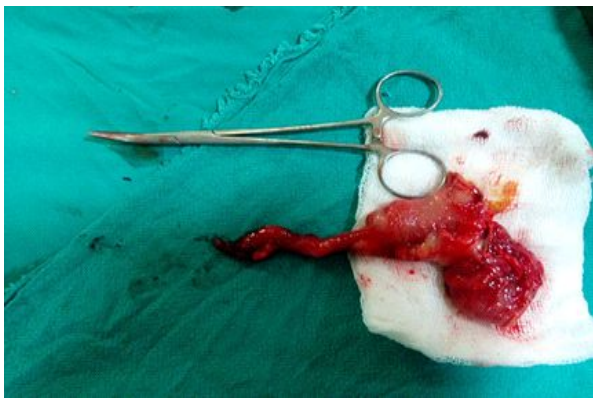

Photo 3: Resected segment of small bowel with diverticulum(case 4)



Photo4: Perforation at base of meckel's diverticulum(case 5)

References :

1. Foster NM, McGory ML, Zingmond DS, Ko CY. Small bowel obstruction: a population-based appraisal. J Am Coll Surg. 2006;203:170–176.
2. C. Cartanese, T. Petitti, E. Marinelli, et al. Intestinal obstruction caused by torsed gangrenous Meckel's diverticulum encircling terminal ileum World J. Gastrointest. Surg., 3 (2011), pp. 106-109.
3. S. Akbulut, Y. Yagmur Giant Meckel's diverticulum: an exceptional cause of intestinal obstruction World J. Gastroenterol., 6 (2014), pp. 47-50
4. Park JJ, Wolff BG, Tollefson MK, Walsh EE, Larson DR. Meckel diverticulum: the Mayo Clinic experience with 1476 patients (1950-2002) Ann Surg. 2005;241:529–533.
5. Prall RT, Bannon MP, Bharucha AE. Meckel's diverticulum causing intestinal obstruction. Am J Gastroenterol. 2001;96:3426–3427.
6. Ishigami S, Baba K, Kato K, Nakame K, Okumura H, Matsumoto M, Natsugoe S, Aikou T. Small bowel obstruction secondary to meckel diverticulum detected and treated laparoscopically-case report. Surg Laparosc Endosc Percutan Tech. 2006;16:344–346.
7. Nath DS, Morris TA. Small bowel obstruction in an adolescent: a case of Meckel's diverticulum. Minn Med. 2004;87:46–48.
8. Whang EE, Ashley SW, Zimmer MJ. Small intestine. In: F.Charles Brunicardi, editor. Schwart's Principles of Surgery. McGraw-Hill 2005; pp.1017-1054
9. Evers BM. Small bowel. in: Courtney M. Townsend jr., editor. Sabiston Textbook of Surgery. Philadelphia, Pennsylvania. W.B. Saunders 2001; pp.: 873-916.