Research Paper

Volume : 4 | Issue : 10 | October 2015 • ISSN No 2277 - 8179

Medulloblastoma: A Case Report

Medical Science

KEYWORDS : Medulloblastoma, Children, Headache

DR.HARSHPREET KAUR	PATHOLOGY RESIDENT, M.G.M MEDICAL COLLEGE, KAMOTHE, NAVI MUMBAI
DR.SHILPI SAHU	ASSOCIATE PROFESSOR, PATHOLOGY, M.G.M MEDICAL COLLEGE, KAMOTHE, NAVI MUMBAI
DR.REETA DHAR	HEAD OF DEPARTMENT, PATHOLOGY, M.G.M MEDICAL COLLEGE, KAMOTHE, NAVI MUMBAI
DR. PRIYANKA JADHAV	ASSISTANT PROFESSOR, PATHOLOGY, M.G.M MEDICAL COLLEGE,KAMOTHE, NAVI MUMBAI

ABSTRACT

Medulloblastoma was first named after Bailey and Cushing in 1925 and described as an aggressive, highly malignant small cell tumor of midline cerebellum. Medulloblastoma is one of the most common primary tumors of CNS of children. Medulloblastoma is a malignant brain tumour most frequently seen in children. We report a case of a 14 year old female having chief complaints of recurrent vomiting and headache since 2 months. Medulloblastoma was diagnosed on Frozen section and was confirmed on H&E section

Introduction:

Medulloblastoma is one of the most common primary tumor of the CNS in children. Medulloblastoma is a malignant brain tumor seen in children. Because a medulloblastoma in adults is a rarity, there are not many studies concerning the treatment of these tumours. In children Medulloblastoma are located in midline of the cerebellum. Medulloblastoma are highly malignant tumors of primitive neuroectodermal origin, representing more than 20% of childhood brain tumor and 1 % of the adult brain tumors . It is the third most common central nervous system tumor to exhibit systemic metastases after glioblastoma and meningioma.

Case Report: We report a case of 14 years old, female presented with 2 months history of headache and recurrent vomiting. MRI of brain was performed using T1,T2 and Flair sequences, a 4.4x3.2x3.7 cm sized heterogeneously enhancing intraxial space occupying lesion in region of fourth ventricle and cerebellar vermis with significant mass effect on ventricle and brain stem. VP Shunt seen in situ.CT Scan suggested a neoplastic mass in posterior fossa. Surgical excision of Brain stem tumor was done and frozen sections of the tumor was diagnosed as high grade small round cell tumor. Histomorphological diagnosis given was Medulloblastoma (grade -IV) .



Figure 1-T-1 Saggital image showing midline posterior fossa –IV Ventricle SOL

Microscopically:

Microscopic examination revealed a poorly differentiated tumor composed of sheets of small-to-medium sized cells with focally molded, hyperchromatic nuclei and scanty cytoplasm . Numerous apoptotic cells and mitotic figures were observed. Horner Wright Rosettes were also observed with central fibrils that protrude from the surrounding cells.

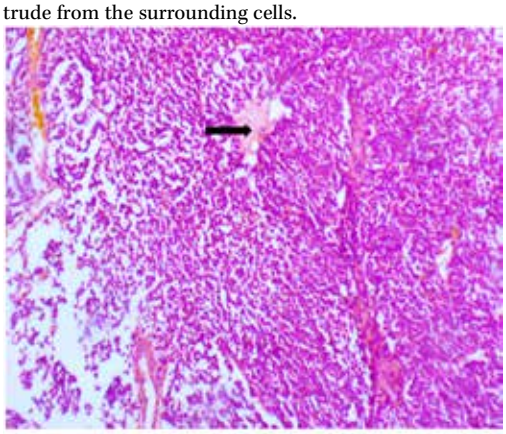

Figure 2: H&E Stained shows Horner wright rosettes with central fibrils that protrude from the surrounding cell (Higher Magnification-40x)

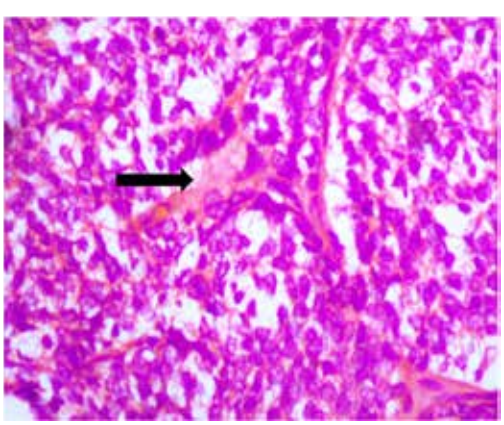

Figure 3: H&E Stained section showing rosette in the centre of image surrounded by densely crowded malignant cells (Higher magnification 40x)

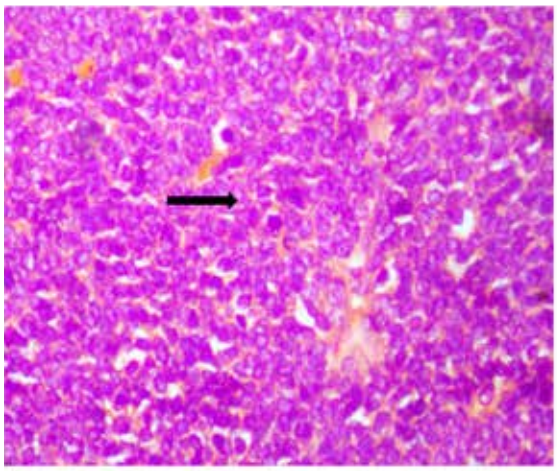

Figure 3: H&E Stained section showing small round blue cell tumor with marked hypercellularity, anaplastic nuclei and high nuclear cytoplasmic ratio. (High magnification-40x)

Discussion: Medulloblastoma is believed to arise from precursor cells of the external granular layer of the developing cerebellum and is predominantly composed of densely packed cells with round-to-oval hyperchromatic nuclei with generally abundant mitotic activity . They account for 40% of all posterior fossa tumors in children and they represent only 0.5–1% of all intracranial neoplasms in adults. Medulloblastoma is a highly malignant neoplasm that originates in cerebellum or in roof of the fourth ventricle.

Conclusion: This case report highlights the importance of clinical suspicion. A brain CT scan should be done to rule out any possibility of an organic lesion. Close monitor is required in order to treat medulloblastoma early and confirmation with histopathological diagnosis so that patient gets treatment in proper time .

REFERENCE

1. David KF, Casey ATH, Hayward RD, et al. Medulloblastoma: is the 5 year survival rate improving?-A review of 80 cases from a single institution. J Neurosurg. 1997; 86:13-21. 2. Ferrara M, Bizzozero L, Fiumara E, et al. Primary leptomeningeal dissemination of medulloblastoma. Report of an unusual case. J Neurosurg Sci. 1989; 33:219-23. 3. Suman R, Santosh V, Anandh BA. Primary leptomeningeal medulloblastoma. Pediatr Neurosurg. 2007; 43:544-5. 4. Mehta R, Cutler A, Lasky J, et al. Primary leptomeningeal medulloblastoma. Human Pathology. 2009; 40:1661-5. 5. Rushing EJ, Smith AB, Smirniotopoulos JG, et al. Occult leptomeningeal large cell medulloblastoma in an adult. Clin Neuropathol. 2009; 28:188-92. 6.Girolami UDe, Douglas C, Anthony, Frosch MP. The central nervous system. Pathologic basis of disease. Robins. 6th edition. Philadelphia: WB Saunders Company; 1999. p. 1348-9. 7.Bailley P. Further notes on the cerebellar medulloblastomas. The effect of roentgen radiation. Am J Path 1930;6:126-36. 8.Nelson A A. Metastases of intracranial tumours. Am J Cancer 1936;28:1-12. 9. Weiss L. A metastasizing ependymoma of the cauda equina. Cancer 1955;8: 161-71. 10.Rochkind S, Blatt I, Sadeh M, Goldhammer Y. Extracranial metastases of medulloblastoma in adults: literature review. J Neural Neurosurgeon Psychiatry 1991;54:80-6.