Volume : 2 | Issue : 4 | Apr 2013 • ISSN No 2277 - 8179

Research Paper

Meningo-orbital Foramen in the Lateral Orbital Wall – Topographical Anatomy and Clinical Relevance

Medical Science

KEYWORDS : Meningo-orbital foramen, Fronto-sphenoidal suture, Fronto-zygomatic suture, Superior orbital fissure,

Renu Chauhan — Associate Professor, Department of Anatomy, UCMS and GTB Hospital Dilshad Garden Delhi-110095

Jugesh Khanna — Professor, Department of Anatomy, UCMS and GTB Hospital, Dilshad Garden, Delhi-110095

ABSTRACT

Sometimes one foramen is seen lying near or along the fronto-sphenoidal suture, superolateral to the lateral end of superior orbital fissure. This inconsistent foramen, known as meningo-orbital foramen (MOF), transmits a branch of anterior meningeal artery, providing additional blood supply to the orbit. The frequency of occurrence of MOF, its distance from supraorbital notch/foramen and frontozygomatic suture has not been seen in North Indian population therefore a study was conducted on 100 orbits of fifty North Indian skulls.

MOF was found to be present in 32 orbits (Right =18, Left=14). The mean distance from MOF to the supra-orbital notch/foramen was 36.2 mm on the right and 36.6 on the left side. The mean distance from MOF to frontozygomatic suture was 21.0 mm on the right and 20.5 mm on the left side. As in some surgical interventions, MOF may lie near the operating field, surgeons need to be familiar about its presence and location.

Introduction

Meningo-orbital foramen (MOF) is found in the lateral wall of orbit, lateral to the lateral end of superior orbital fissure (Figure 1). Standard text books of Anatomy 1 - 5 do not describe its topography. It links the interior of orbit with anterior or middle cranial fossae. In Anatomical literature some of the authors call MOF as cranio-orbital foramen 6 stapedial ophthalmo lacrimal foramen 7, sinus canal foramen, sphenofrontal foramen, foramen of Hyrtl and Lacrimal foramen 8.

Awareness about the variable presence of MOF is important for ophthalmologists while performing orbital reconstructive procedures and neurosurgeons while operating on base of anterior or middle cranial fossae. Therefore, the present study was undertaken in order to explore the frequency and positional anatomy of this foramen in fifty dry adult human skulls of North Indian origin.



Figure 1: Arrow pointing at the meningo-orbital foramen seen in the right orbit, lateral to superior orbital fissure. marked at the superior orbital fissure

Materials and methods

One hundred orbits of 50 North Indian, dried human skulls of either sex were obtained from the department of Anatomy, University College of Medical Sciences and Guru Teg Bahadur Hospital, Delhi, India, for the study. The frequency of occurrence of meningo-orbital foramen in the right and left orbit were noted. The position of MOF with reference to supra orbital notch/foramen and frontozygomatic suture were recorded by measuring distances between MOF and these landmarks (Figure 2).The distances were carefully measured using vernier callipers with a least count of 0.02 mm.

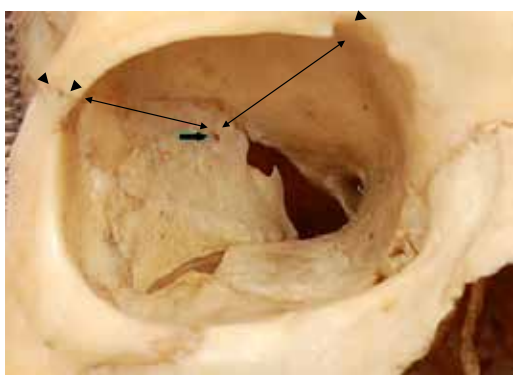

Figure 2: Right orbit showing distances measured between
a) MOF and supraorbital notch
b) MOF and frontozygomatic suture
Arrow pointing at MOF, ► supraorbital notch, ▼ frontozygomatic suture

Results

One hundred orbits of 50 dried human skulls of either sex were examined. MOF existed in thirty two orbits (18 right, 14 left) out of the hundred orbits studied. No MOF was seen in some of the orbits (figure 3).



Figure 3: Lateral wall of the orbit showing no foramen

Only in one skull, the foramen was seen in both the orbits and in majority of skulls it was present unilaterally (figure 4).

Volume : 2 | Issue : 4 | Apr 2013 • ISSN No 2277 - 8179



Figure 4: Arrow pointing at the meningo-orbital foramen seen bilaterally in only one skull

It was located either at or below the frontosphenoidal suture (figure 5,6).

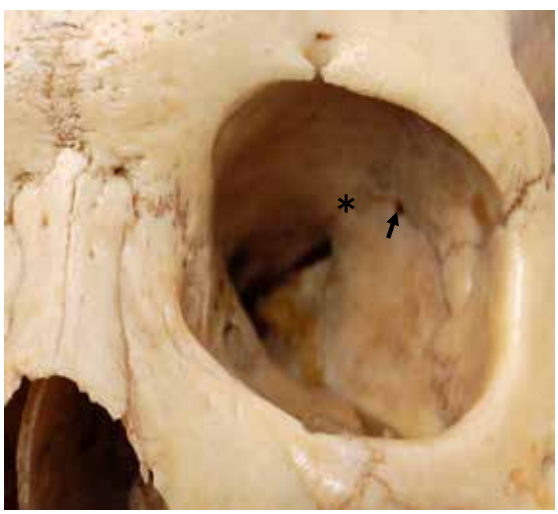

Figure 5: Arrow pointing at the meningo-orbital foramen seen in the left orbit on the frontosphenoidal suture, * at the frontosphenoidal suture

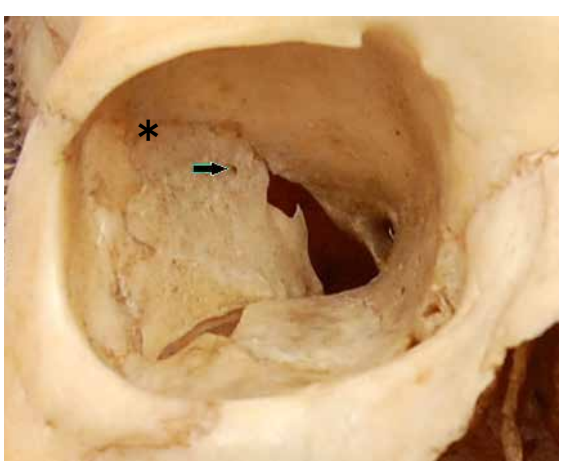

Figure 6: Arrow pointing at meningo-orbital foramen seen in the right orbit below the frontosphenoidal suture, * at the frontosphenoidal suture

The distance of the foramen from the frontozygomatic suture was 18.0-25.0 mm on the right side and 18.0 – 24.0 mm on the left side with a mean of 21.0 mm and 20.5 mm respectively. The distance of the foramen from the supra orbital notch/foramen was 32.0 – 39.0 mm on the right side and 33.0 – 39.0 mm left side with a mean of 36.2 mm and 36.6 mm respectively (Table 1).

Table 1. Incidence of meningo-orbital foramen and its distance to the supra- orbital notch/foramen and the frontozygomatic suture
(MOF= Meningo-orbital foramen)

Side of orbit	Incidence of MOF (%)	Distance from MOF to Supra-orbital notch/ foramen mm)	Distance from MOF to frontozygomatic suture at the entrance of the orbit (mm)
Right	18	32.0 - 39.0, Mean= 36.2	18.0-25.0, Mean=21.0
Left	14	33.0-39.0, Mean= 36.6	18.0-24.0, Mean=20.5

Discussion

In the present study, MOF was found to be present in 32 orbits (Right = 18, Left = 14) of the 50 skulls examined. MOF was present unilaterally in majority of cases and was seen bilaterally in only one of the 50 skulls. The present investigation revealed MOF to be present in 62% cases. In a study conducted on the South Indian population, MOF was found to be present in 44.32% of the 97 skulls seen 8. Regional variation could be a possible explanation of this difference. Some authors have reported fewer incidence of this foramen. Kwiatkowski, Wysocki and Nitek 9 reported it to be 28% while Neto et al 10 reported it to be 6%.Other authors have reported quite high incidence of MOF, Erturk et al 6 reported the incidence of MOF as 82.39% Krishnamurthy et al 11 found it to be in 80.4% of the skulls studied while Mysorekar and Nandedkar 12 found MOF to be present in 44 right orbits and 46 left orbits of the 100 skulls examined.

The mean distance from MOF to Supra-orbital notch/foramen in the current study was 36.2 mm, 36.6 mm on the right and left sides respectively. Kwiatkowski, Wysocki and Nitek 9 suggested the mean distance from MOF to Supra-orbital notch/ foramen to be 34.4 mm and 35.8 mm on the right and left sides respectively The mean distance from MOF to Supra-orbital notch was 34.2 mm on the right side and 34.1 mm left side in another work carried out on 138 skulls by Krisnamurthy et al 11 (Table 2). The mean distance from MOF to Supra-orbital notch/foramen obtained from the current work corresponds to the study conducted by Kwiatkowski, Wysocki and Nitek 9 and Krisnamurthy et al 11.

Table 2: Distances between the MOF to the supra orbital foramen/notch and MOF to frontozygomatic suture in mm (Various studies).

Study	MOF to the supra orbital foramen/ notch	MOF to frontozygomatic Suture
Kwiatkowski et al. (2003)	34.4: 35.8, R:L	25.0:26.8, R:L
Krishnamurthy et al. (2008)	34.2:34.1, R:L	26.5:25.7, R:L
Present study (2013)	36.2 :36.6, R:L	21.0 : 20.5, R:L

The morphometric observations of MOF with reference to supraorbital notch/foramen and frontozygomatic suture noted in the present investigation were compared with those of earlier studies (Table-2). It needs to be emphasized that the position of MOF is much closer to frontozygomatic suture in the present study.

MOF links orbit to the cranial cavity. In adults it represents a passage for the vessel connecting the orbital branch of the anterior division of the middle meningeal artery and lacrimal branch of the ophthalmic artery. This connecting vessel is an accessory blood supply to the orbit 9. The foramen represents an embryonic conduit between the supraorbital division of the stapedial artery and the permanent stem of the ophthalmic artery

7. Although the location of MOF is not fixed, it lies superolateral to superior orbital fissure. Ophthalmologists should be aware of presence of this foramen and its distance from important landmarks while performing any surgical procedure through the lateral wall of the orbit in order to avoid injury of this vessel accidently.

Neurosurgeons also need to be familiar about presence of this foramen while operating on the base of anterior or middle cranial fossae to avoid any vascular catastrophe.

The current investigation is a humble attempt to provide data with reference to topographical anatomy of meningo-orbital foramen in North Indian population.

Conclusion

It becomes evident from the current study that the MOF is found in 62% of North Indian skulls and is generally present unilaterally. Precise information pertaining to the topographical anatomy of MOF is undoubtedly relevant to ophthalmologists and neurosurgeons in their clinical practice.

REFERENCE

1. Standring S, 2008, Gray's Anatomy, Edinburgh, UK, Churchill Livingstone, 40th edition. 2. Keith L Moore, Anne M. R. Agur, Arthur F. Dalley, 2011, Essential Clinical Anatomy, Baltimore, Philadelphia, Lippincott Williams & Wilkins, Wolter Kluwer, 4th edition. 3. Keith L Moore, Arthur F. Dalley, Anne M. R. Agur, 2009, Clinically Oriented Anatomy, Baltimore, Philadelphia, Lippincott Williams & Wilkins, Wolter Kluwer, 6th edition. 4. Snell RS, 2012, Clinical Anatomy by Regions, Baltimore, Philadelphia, Lippincott Williams & Wilkins, Wolter Kluwer, 9th edition. 5. Snell RS, 2007, Clinical Anatomy by Systems, Baltimore, Philadelphia, Lippincott Williams & Wilkins, Wolter Kluwer , 1st edition. 6. Erturk M , Kayalioglu G, Govsa F, Varol T, Ozgur T. The cranio-orbital foramen, the groove on the lateral wall of human orbit, and the orbital branch of the middle meningeal artery. Clinical Anatomy. 2005;18(1):10-4. 7. Georgiou C, Cassell MD. The Foramen Meningo-Orbitale And Its Relationship To The Development Of The Ophthalmic Artery. J Anat. 1992;180(1):119–125. 8. Yuvaraj BK, Sivanandan R, Saraswathy P. Incidence of Foramen Meningo - Orbitale in South Indian Population. Recent Research in Science and Technology. 2011;3(10):43-44. 9. Kwiatkowski J, Wysocki J, Nitek S. The morphology and morphometry of the so-called "meningo-orbital foramen" in humans. Folia Morphol (Warz). 2003;62(4):323-5. 10. Neto HS, Penteado CV, De Carvalho VC. Presence of a groove in the lateral wall of the human orbit. J Anat. 1984;38(4):631-33. 11. Krishnamurthy A, Nayak SR, Prabhu LV, Mansur DI, Ramanathan L, Madhyastha S, Saralaya V. The morphology of meningo-orbital foramen in south Indian population. Bratisl Lek Listy. 2008;109(11):517-9. 12. Mysorekar VR, Nandedkar AN. The groove in the lateral wall of Human orbit. J Anat. 1987;151:255-257.