ORIGINAL RESEARCH PAPER

Volume-8 | Issue-1 | January-2019 | PRINT ISSN No 2277 - 8179

INTERNATIONAL JOURNAL OF SCIENTIFIC RESEARCH

MINIMALLY INVASIVE TECHNIQUE FOR FIXATION OF MIDDLE SHAFT OF CLAVICLE FRACTURES BY TITANIUM ELASTIC NAIL.

Orthopaedics

Dr Himanshu D Shah* Assistant Professor, Department of Orthopaedics, Government Medical College, Vadodara.*Corresponding Author

ABSTRACT

BACKGROUND: Conventionally middle third shaft clavicle fractures are treated conservatively. Recently there is trend favouring fixation and achieving length and early mobilization. Plate fixation is standard approach. Minimally invasive fixation using TEN by tiny incision is alternative of plating with several advantages.

METHOD: Twenty two patients were operated using tiny 1 cm vertical incision for TEN insertion under IITV guidance after closed reduction. K wire was used as joystick to manipulate the distal fragment.

RESULTS: All patients were operated by close method. Average union time was 10 weeks without any complication. Four patients had skin impingement due to TEN at entry site which were subsequently extracted.

CONCLUSION: TEN of Clavicle is minimally invasive surgery of middle third non comminuted shaft clavicle fracture which requires minimum soft tissue dissection, preservation of fracture hematoma, early union, less blood loss, less hospital stay and early mobilization.

KEYWORDS

INTRODUCTION:

Clavicle fractures account for approximately 2.5% to 10% of all fractures. Out of all clavicle fractures, middle third shaft fracture contributes to 70-80% and over half of these fractures are displaced by muscular force mainly trapezius & sternocleidomastoid. Mode of trauma is usually fall on outstretched hand or on shoulder or due to road traffic accident in which it is usually associated with other injuries. Conventionally, midshaft clavicle fractures are treated by figure of eight bandage and has good outcome. Functional outcome is not only related to union but also to its length. Hill Et al.

showed that more than 2 cm displacement is associated with 15% of non-union rate. Mackee et al reported 20 mm displacement is associated with cosmetic deformity and poor patient compliance due to deformity (1). So recently, there is trend favouring surgical reconstruction of displaced midshaft clavicle fractures for better functional and cosmetic outcome.

Open reduction and plating is still standard surgical option for fixation of midshaft displaced fractures. Associated complications following plate fixation of clavicle fractures are infection, non union, implant related complications like impingement on soft tissue, exposed implant & implant failure are rated higher than other modality of treatment which includes nail fixation. Titanium elastic nailing of middle shaft clavicle fractures was first described by Jubel et al. It acts as internal splint with achievement of adequate length of clavicle and requires tiny incision for insertion (1).

The aim of this study is to show technique of Titanium elastic nail insertion in middle shaft clavicle fractures and its outcome.

MATERIALS AND METHOD:

Twenty two patients with displaced middle shaft clavicle fractures were included in the study.

Inclusion criteria were displaced middle third non comminuted fractures. Exclusion criteria were fractures associated with neurovascular injuries, the same upper limb fractures in addition to clavicle fracture and floating shoulder entity.

There were 17 male patients and 5 female patients which were included in the study. All patients were operated under General Anaesthesia with pillow in interscapular region. Vertical 1 cm of incision was kept just lateral to the sternoclavicular joint. Entry was taken with an awl under IITV guidance. Titanium elastic nail of appropriate thickness was chosen to insert. With handle, the nail was guided through entry site and into the medullary canal of clavicle. Closed reduction was performed by gentle upper limb traction and retraction of shoulder. K wire was used as joystick for distal fragment reduction by elevating it. K wire was used just inferior to distal shaft fragment to elevate it. After reduction was achieved, the TEN was inserted into distal shaft fragment under IITV guidance. Before final TEN insertion, it is cut so as to keep its length appropriate as per length of clavicle. Wound is closed by skin sutures. All the patients were kept in shoulder sling postoperatively with intermittent shoulder mobilization allowed as per pain tolerance. Heavy weight lifting was not allowed till 8 weeks or till consolidated union visible on xray. Follow ups were carried out at 2 weeks, 4 weeks and then at 4 weeks interval till radiological union was seen up to maximum of 9 months.

We assessed radiological union as formation of callous or absence of fracture line in follow up x-rays.

All the patients were assessed using Quick DASH score at final follow up.

RESULTS:

Out of 22 patients, 17 were male patients and 5 were female patients. Fifteen patients had fall on outstretched hand while 7 patients had clavicular fracture due to road traffic accident without other associated ipsilateral upper limb fractures. All patients had middle shaft closed noncomminuted clavicular fractures without neurovascular deficit. The average age of presentation was 23.5 years with range of 19-39 years of age. The average follow up time was 12 weeks with average union time of 10 weeks. All the patients had closed reduction and nailing and none of the patient require open reduction with no suture related complications in follow up. Twenty patients out of 22 required K-wire Joysticking for reduction. All patients had nearly full range of shoulder movement. Average quickDASH score at final follow up was 9.8. Four patients developed implant related complication as impingement at entry site which required removal after union achieved. None of the patients was diagnosed with non union or infection during follow up period.

Conventionally shaft of clavicle fractures were treated by conservative method using figure of eight bandage and shoulder sling. Neer and Rowe in 1960 had reported very good outcome of conservative treatment of clavicle fractures (2). More recent studies have shown significant higher rate of non union and deformities of malunion. For better outcome, surgical fixation is recommended. Plate fixation ofmidshaft clavicular fractures has been standard surgical fixation technique. Achievement of anatomical length and reduction is possible with plating. However, excessive periosteal stripping leading to higher non-union rates, deep infections, implant failure and implant backout are common complications encountered during plating. Saha P.et al reported the same complications in their series(2). N.Narsariya et al also reported these complications with 2 patients required revised major surgery in their series of plating (3). Zeng L. Et al reported stress shielding with the use of clavicular plate (4).

In comparison to plating, intramedullary TEN requires very tiny skin incision and that too away from fracture site which preserves fracture

hematoma favouring early healing of fracture. Less implant related complications were noted in our study. Minimally invasive technique is favourable cosmetically also (5). Four patients required implant extraction following bony union due to impingement over skin on medial entry site in this study.

Intramedullary implants are load sharing devices with optimum from biomechanical point of view as the tension side of clavicle changes with respect to rotation of arm and direction of loading. The benefit of this technique includes tiny incision, minimum soft tissue dissection, preservation of fracture hematoma and optimum implant as per biomechanical stability.

Beigang Fu reported better clinical outcome in terms of less operative time, less hospital stay, less wound size, shorter average union time and good functional outcome (6).

Important implant related complication of TEN is impingement over entry site over skin which requires extraction of implant. Literature has reported such incidence as 5-38% of all TEN clavicle surgeries. Secondary nail displacement due to telescoping effect or inadequately cut medial end of TEN may be responsible for the impingement (2).

The drawback of this study is less number of subjects enrolled with short term follow up.

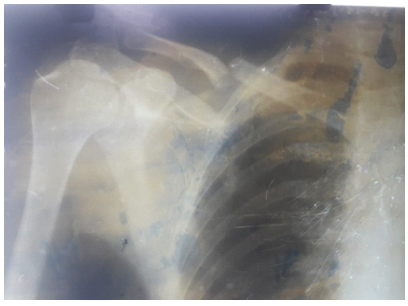

Figure 1: preoperative xray of midshaft clavicle fracture

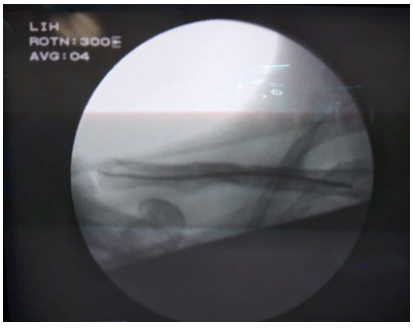

Figure 2: IITV image of TEN across well reduced fracture site.

REFERENCES

1. Anish P. Kadakia et al.titanium elastic stable intramedullary nailing of displaced midshaft clavicular fractures: a review of 38 cases.Int journal shoulder surgery 2012 july-sept.; 6(3):82-85.
2. Partha Saha et al. Plate versus titanium elastic nail in treatment of displaced midshaft clavicle fractures A comparative study. Indian journal of orthopaedics, November 2014; 48(6):587-93.
3. Nidhi Narsaria, Ashutosh K. Singh, G. R. Arun, R. R. S. Seth. Surgical fixation of displaced midshaft clavicle fractures: elastic intramedullary nailing versus precontoured plating. J Orthopaed Traumatol (2014) 15:165–171.
4. Zeng L. Et al. TEN versus plate reconstruction repair of midshaft clavicular fractures: A finite element study. PLos one 2015 May 12; 10(5).
5. Paul Hoogervorst, Peter van Schie, Michel PJ van den Bekerom. Midshaft clavicle fractures: current concepts. Efort open Reviews 2018 June; 374-380.
6. Beigang Fu. Minimally invasive intramedullary nailing of clavicular fractures by a new titanium elastic nail. Acta Orthopaedica et Traumatologica Turcica.2016; 50:494-500.