ORIGINAL RESEARCH PAPER

Volume-8 | Issue-1 | January-2019 | PRINT ISSN No 2277 - 8179

INTERNATIONAL JOURNAL OF SCIENTIFIC RESEARCH

MODIFICATION OF SURGICAL TECHNIQUE - ONE WAY TO PREVENT PROXIMAL JUNCTIONAL KYPHOSIS (PJK) IN ADOLESCENT IDIOPATHIC SCOLIOSIS (AIS) TREATED BY POSTERIOR INSTRUMENTATION AND FUSION

Orthopaedics

Suresh Pillai

ABSTRACT

Introduction: PJK is a kyphotic deformity in the spinal motion segments immediately cephalad to the instrumented segments. The incidence ranges from 9-28% in the reported literature.This can occur in different conditions

***Hypothesis*:** Resection of the posterior ligament complex between the upper instrumented and un instrumented vertebra is proposed as one cause of PJK

Materials and Methods: A prospective study from 2007 to 2011 was done with a minimum follow up of 2 yrs. A modification of the procedure was done . The posterior ligament complex between the upper two instrumented vertebrae and the non instrumented vertebra are retained.. Fusion is done till the UIV. 32/36 AIS patients underwent modification. Patients were assessed at regular intervals

Results: All the 32 patients who underwent this modification did not develop PJK.. 4 patients who did not undergo this modification developed increase in kyphosis.

Discussion: This study was done from 2007-2011. A recent article published by The Springer ((Curr Rev Muskuloskelet Med (2016)9:299-308, Robert. A . Hart etal) describes posterior ligament disruption has important role in the development of PJK and PJF. Reinforcing the posterior tension band may be effective in reducing the risk for developing PJK. Hart etal proposes mesilene tape augmentation between the UIV and UIV+1 inorder to create a functional tension band. Preserving the PLC is a biological way to preserve the posterior tension band and prevent development of PJK in AIS patients .

Conclusion: This modified procedure is one way to prevent PJK in AIS patients undergoing posterior instrumented correction.

KEYWORDS

PJK, AIS, Modification

INTRODUCTION:

PJK is a kyphotic deformity in the spinal motion segments immediately cephalad to the instrumented segments. There are reported incidents of PJK ranging from 9-46% in different literature. Pedicle screw instrumentation, combined anterior and posterior procedure etc. are reported as potential causes for this. Based on this hypothesized that the resection of the posterior element collection to the uninstrumented vertebra above and the damage to the facet capsule while putting the upper screws causes forward slippage of the vertebra resulting in proximal junctional kyphosis.

PJK can cause deformity, pain, neurological injury, which may warrant revision surgery. This may lead to osteotomy or extension of instrumentation to the proximal levels The etiology of PJK is believed to be multifactorial[3]. No variable consistently predicts its development. The factors described are greater curvature correction, combined anterior posterior spinal fusion, fusion to the sacro-pelvis and residual sagittal imbalance. The use of hooks,

pedicle screws, or wires at the proximal levels has not been consistently shown to significantly affect the risk of PJK across different studies.

Helgeson et al[1] has described significantly increased PJK with pedicle screws. Kim et al[2] has shown combined anterior posterior fusion as an increased risk factor in the development of PJK

HYPOTHESIS

With this back ground it is hypothesized that the resection of the posterior element connection to the uninstrumented vertebra above causes forward slippage of the vertebra above resulting in PJK.

MATERIALS AND METHODS

A prospective study was done from 2007 onwards with minimum 2 yr follow up. 32/36 AIS patients underwent posterior correction with modification of the routine procedure. The spinous process of the upper instrumented vertebra, supraspinous and inter spinous ligaments connections to the upper instrumented vertebra and the vertebra above uiv-1 are retained. Care is taken not to damage the facet capsules at the junction

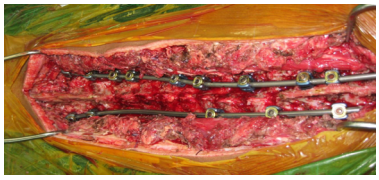

PICTURE 1: Picture showing the modification—Interspinous connection is retained

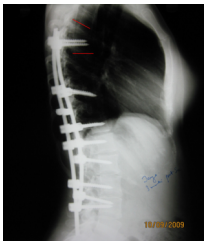

PICTURE 2: PJK resulted from resecting the PLC up to the instrumented vertebra



PICTURE 3: No PJK with retention of the interspinous connection between the instrumented and un instrumented vertebra

4/36 patients underwent resection of the spinous process of the upper instrumented vertebra , thus the ligaments also are sacrificed . 29 out of 36 patients were-females and 7 were males. Cobb angle ranged from 40-120 degrees in the studied patients. There was no strict specification on curve types. All pedicle screw construct was used in all the cases. 24 out of 36 cases underwent grade 2 anterior release (resection of the disc and anterior longitudinal ligament) around the apex and fusion with rib graft and a second stage (one week later). Posterior correction and fusion with spinous process and transverse process graft was done. The anterior release did not extend to the end vertebrae. It was limited to the peri-apical discs. Anterior release was done in stiff curves (less than 50% flexibility in side bending films) and in skeletally immature children. 12 out of 36 patients underwent posterior fusion alone. Semi rigid titanium rods were used for correction. No brace was used postoperatively. Patients were mobilized from second postoperative day. PJK was measured in standing, lateral, whole spine x-ray films from the lower endplate of

upper instrumented vertebra to the upper endplate of UIV+1. The criteria for diagnosing PJK was, >10 degree kyphosis at proximal segment and >10 degree angle compared to pre –operative values (SPINE ;33(20), 2008) PJK was assessed pre operatively, post operatively, at 6 months , 1 yr and 2 yrs.

Table 1- Details of patients

No.	Cobb angle	Pre op PJK(Deg)	Post op	6 months	1yr post op	2 yr post op
1.	T50,L30	10	8	8	7	7
2	T40	14	7	0	5	9
3	T 100, L 70	0	7	5	5	5
4	T70 L40	5	5	6	7	8
5	TL 55	5	5	15	25	30
6	TL 80	13	13	13	13	13
7	T 45 L25	17	2	2	2	2
8	TL 60	0	5	3	3	3
9	T 80 L 45	0	0	0	0	5

Table 2- Details of patients

No.	Cobb angle	Pre op PJK(deg)	Post op	6 months	1yr post op	2 yr post op
10	D45 DL 70	5	5	5	5	5
11	T 60	17	13	25	30	30
12	T4 5	7	10	10	15	15
13	T45 L30	7	4	5	4	4
14	T45 L30	20	24	25	24	24
15	T 40 L45	12	10	10	8	13
16	T60 L30	10	10	10	12	12
17	T 135 L140	7	7	8	8	8
18	T55	0	0	0	0	0

Table 3—details of patients

No.	Cobb angle	Pre op PJK(Deg)	Post op	6 months	1yr post op	2 yr post op
19	T 65 L65	8	9	10	10	10
20	TL 65	15	15	10	10	10
21	T 60	10	5	5	7	7
22	T65 L40	15	10	12	12	12
23	T 60 L 60	12	10	10	10	10
24	T 40 L50	15	10	10	10	10
25	T50 L 60	7	8	8	9	9
26	T82 L 80	10	8	5	5	5
27	T50 L40	8	8	5	5	5

Table 4- details of patients

No.	Cobb angle	Pre op PJK(deg	Post op	6 months	1yr post op	2 yr post op
28	T80 L 120	2	0	0	0	0
29	T75 L 45	10	5	5	5	5
30	T 55	15	12	15	14	14
31	T70 L25	10	5	3	3	3
32	T45 L50	9	12	12	15	15
33	T40 L40	5	10	12	12	12
34	T 60	5	5	2	2	2
35	TL 45	10	10	10	10	10
36	T 76 L 30	10	10	12	12	12

STATISTICALANALYSIS

A total of 36 patients with AIS were included of which 32 underwent the modification. Study was conducted from 2007 to 2011 respectively. 29 of 36 were females and 7 out of 36 were males in the adolescent age group. Among the 32 patients, pre operative PJK score was 9.03, and it has reduced to 7.72 post operatively but it is not statistically significant (p value 0.069). At six months it is significantly reduced to 7.25 from base line (p value 0.031). At one year follow up it is increased to 7.56 and at two year follow up it increased to 8.03. Among the four cases who underwent no modification the scenario was different. Even though only one patient have PJK more than or equal to 10 pre operatively, at 2 years follow up all of them reported PJK more than 12 and two participants recorded a score of 30 each. The average increase in PJK score reported at two year follow up in this group offour patients is 12.75.

Table 5- statistical analysis

	Pre op	Post op	6 months	One year	Two year
Mean ± SD	9.03 ± 5.19	7.72 ± 4.7	7.25 ± 5.24	7.56 ± 5.13	8.03 ± 5.02
Median	10	8	7	7	8
Minimum	0	0	0	0	0
Maximum	20	24	25	24	24
p value compared to pre op score		0.069	0.031*	0.068	0.207

STATISTICAL METHODS USED:

Data were analyzed using SPSS 21.0. Continuous data were expressed as mean with standard deviation or as median. Paired continuous variables were analyzed using paired sample t test and a p value less than 0.05 was considered as statistically significant

DISCUSSION

Out of the 36 patients who underwent the modification of the surgical technique by keeping the posterior ligamentous complex connection between UIV+1, UIV and UIV-1 did not develop PJK in 2 years of serial follow up. All the four patients who did not undergo the modification developed PJK significantly. Two of the participants developed PJK to the tune of 30 degrees. Modification in the technique can prevent PJK in AIS patients undergoing posterior instrumented correction

In a recent publication (Ngoc-Lam M.Nguen, Christopher Y Kong, Robert A Hart - Proxymal junctional kyphosis and failure– diagnosis, prevention and treatment, Curr Rev Muskuloskeletal med (2016)9:299-308) Hart et al described a technique of looping a mersiline tape around the spinous process of upper instrumented vertebra (UIV) and UIV+1 in order to create a functional posterior tension band called spinous process augmentation to prevent proximal junctional kyphosis and failure. The method described here is a biological way to prevent PJK in AIS patients undergoing posterior instrumented correction & fusion. This study is a prospective one from 2007 onwards.

CONCLUSION

Modification in the technique can prevent PJK in AIS patients undergoing posterior instrumented correction

REFERENCE

1. Melwin d Helgeson et al : Spine, Vol 35, No.2; 2010
2. Kim etal- Spine:vol 33,no.20,2008
3. Ngoc-Lam M.Nguen, Christopher Y Kong, Robert A Hart - Proxymal junctional kyphosis and failure– diagnosis, prevention and treatment, Curr Rev Muskuloskeletal med (2016)9:299-308
4. Pierre Roussouly • Colin Nnadi et al Sagittal plane deformity: an overview of interpretation and management Eur Spine J (2010) 19:1824–1836 DOI 10.1007/s00586-010-1476-9
5. Tom P.C. Schl€osser, MDa, Suken A. Shah, MDb, Samantha J. Reichard, Kenneth Rogers, PhD, ATCb, Koen L. Vincken, PhDc, Ren_e M. Castelein, MD, PhD Differences in early sagittal plane alignment between thoracic and lumbar adolescent idiopathic scoliosis. The Spine Journal 14 (2014) 282–290 2013 Outstanding Paper Runner-up
6. Nicoladoni C. Anatomie und mechanismus der skoliose. In:Kocher ET, K€onig FJ, von Mikulicz J, eds. Bibliotheca Medica. Stuttgart, Germany: Verlag von Erwin Nagele, 1904
7. Machida M, Murai I, Miyashita Y, et al. Pathogenesis of idiopathicscoliosis. Experimental study in rats. Spine 1999;24:1985–9.
8. Yong Q, Zhen L, Zezhang Z, et al. Comparison of sagittal spinopelvic alignment in Chinese adolescents with and without idiopathic thoracic scoliosis. Spine 2012;37:E714–20.
9. Mac-Thiong JM, Pinel-Giroux FM, de Guise JA, Labelle H. Comparison between constrained and non-constrained cobb techniques for the assessment of thoracic kyphosis and lumbar lordosis. Eur SpineJ 2007;16:1325–31.
10. Cobb JR. Outline for the study of scoliosis. In: . Instructional courselectures Vol 5, 2nd ed. Rosemont, IL: American Academy of Orthopaedic Surgeons, 1948:261.