ORIGINAL RESEARCH PAPER

Volume-8 | Issue-3 | March-2019 | PRINT ISSN No 2277 - 8179

INTERNATIONAL JOURNAL OF SCIENTIFIC RESEARCH

MOORENS ULCER:A SERPENT INDEED

Ophthalmology

Dr Ravindra Kumar Chowdhury Assistant Professor, Department Of Ophthalmology, Vssimsar, Burla

Dr Sharmistha Behera* Associate Professor, Department Of Ophthalmology, Vssimsar, Burla *Corresponding Author

Dr Kshyanaprava Priyadarshini 2nd Year Resident, Department Of Ophthalmology, Vssimsar, Burla

Dr Jayashree Dora Professor & Hod, Department Of Ophthalmology, Vssimsar, Burla

ABSTRACT

AIM: To evaluate the clinical characteristics and treatment outcomes of Mooren's corneal ulcer in Western Odisha.
METHODS: 51 cases of Mooren's corneal ulcer were analysed, including age, sex, laterality ,ulcer location,perforation rate,cure rate, topical & intravenous steroids, recurrence rate, peritomy, penetrating keratoplasty and immunomodulator eye drops.
RESULTS: The average age of onset was 47.6 years of age. The ratio of males to females was 1.4:1. 15(30%) cases were bilateral, of which 5(31.5%) occurred in the young(<35) & 15(68.5%) in the old age (>35)group. In 37 eyes (72%) ulcer was located at the limbus.The perforation rate was 5%.
CONCLUSION: Chronic serpiginous being its nature, this autoimmune disease has a bad prognosis. However, topical & systemic steroids alongwith peritomy & immunomodulators help stabilize the disease progression.

KEYWORDS

moorens, chronic serpiginous ulcer

INTRODUCTION:

Mooren's ulcer is a painful, relentless, chronic ulcerative keratitis that begins peripherally and progresses circumferentially and centrally[1]. Mooren's ulcer was first described by Bowman in 1849[2], and then by McKenzie in 1854 as "chronic serpiginous ulcer of the cornea or *ulcus rodens*"[3]. Mooren's name, however, became attached to this rare disorder because of his publication of cases in 1863 and 1867[4]. He was the first to clearly describe this insidious corneal problem and define it as a clinical entity. Mooren's ulcer is, by definition, idiopathic occurring in complete absence of any diagnosable systemic disorder that could be responsible for the progressive destruction of the cornea. It is strictly a peripheral ulcerative keratitis (PUK), with no associated scleritis.[5] Although organ-specific autoimmunity is the most accepted theory [6], the etiopathogenesis of the disease remains unclear. The essential aim of the treatment is to promote the epithelialization, to control the inflammation, and to prevent the progression. Treatment options include medications and surgery. However, there is not enough evidence to show which one is the most effective. Despite the advances made in management of this disorder, a significant percentage of cases remain refractory to available therapies and end in severe visual morbidity.

MATERIALS AND METHODS:

INCLUSION CRITERIA:

Patients with no other identifiable infectious or systemic causes of peripheral ulcerative keratitis

EXCLUSION CRITERIA:

Patients with infectious and systemic diseases such as Wegener's granulomatosis,rheumatoid arthritis, systemic lupus erythematosus,Patient's with H/O previous ocular surgery or any trauma

66 eyes of 51 cases from Western Odisha were analyzed based on their age, sex, laterality, ulcer location,perforation rate,topical & intravenous steroids,recurrence rate,peritomy, penetrating keratoplasty and immunomodulator eye drops at a tertiary care centre from July 2017-December 2018.

The diagnosis was established by the typical ulcer morphology , detailed case history taking, physical examination, and comprehensive laboratory tests (erythrocyte suspension rate, antistreptolysin O, rheumatoid factor, and antinuclear antibody). Patients presented with symptoms of pain, redness, photophobia, watering, foreign body sensation and vision loss.

A step-wise approach was followed for management

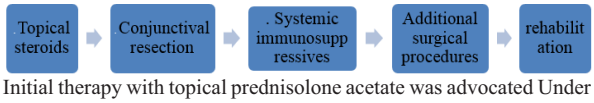

Initial therapy with topical prednisolone acetate was advocated Under topical anaesthesia, conjunctival excision to bare sclera extending at least 2 clock hours to either side of the peripheral ulcer [peritomy], and approximately 4 mm posterior to the corneoscleral limbus and parallel to the ulcer was done in cases not responding to topical steroids Cases of bilateral or progressive Mooren's failing the preceding therapeutic attempts were given systemic steroids and immunomodulators to bring a halt to the progressive corneal destruction.

Penetrating keratoplasty(tectonic grafting) was performed on patients refractory to above therapeutic modalities
The period of follow-up was 18months

RESULTS:

The average age of onset was 47.6 years of age.Age of the patients ranged from 10-70 years.Male to female ratio was 1.4:1. 15(30%) cases were bilateral, of which 5(31.5%) occurred in the young(<35) & 10(68.5%) in the old age (>35)group.

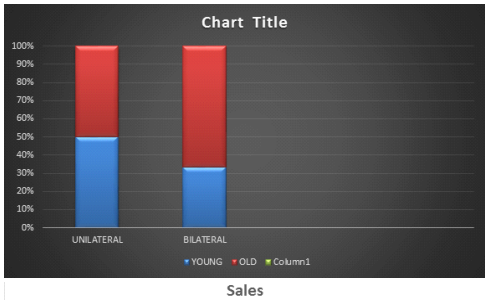

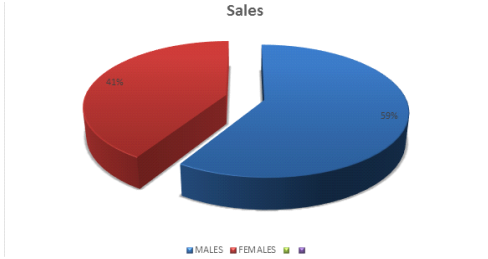

In 66 eyes of 51 cases,47(70.5%) eyes presented with redness while pain was presented in (64.7%) eyes.Foreign body sensation was present in 8(45.6%) cases with photophobia in 9(52.9%),tearing in 7(41.1%) and visual loss in 3(19.8%) cases.

Treatment	Number Of Cases	Improvement Seen In
1.Topical & systemic steroids	51	21(41.4%)
2.Topical steroids plus immunosuppressants(cyclosporine-A)	30	21(71.4%)
3.Conjunctival resection	9	7(33.3%)
4. PK	2	1(50%)

The perforation rate was 5%.In bilateral cases recurrence was seen in 3 case in 6 months follow-up.In 12 months follow-up recurrence was seen in 6 of the unilateral and 6of the bilateral cases.In 18 months follow-up recurrence was seen in 9 of the unilateral cases

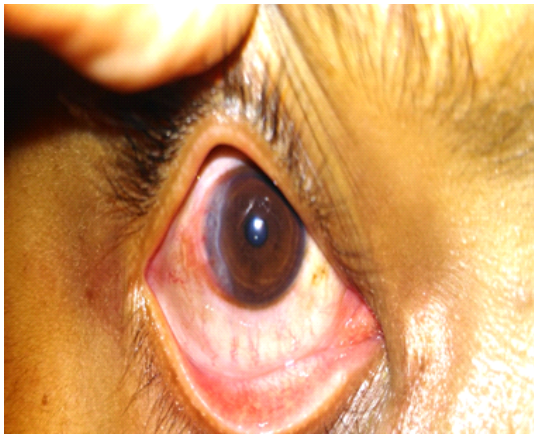



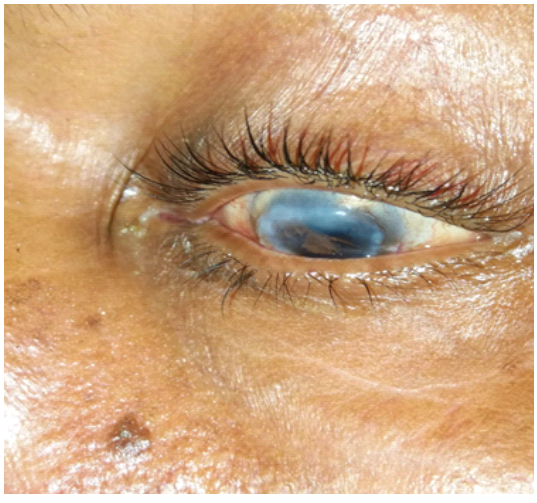



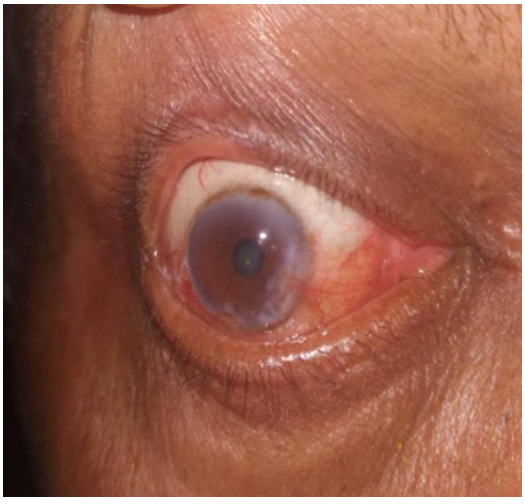

DISCUSSION:

Mooren's ulcer is a relentless PUK characterized by stromal loss and absence of identifiable systemic disease [7,8]. The prevalence of Mooren's ulcer and the blindness caused by the disease is unknown [9] We analysed 17 cases of Mooren's ulcer and found that the average age of the first attack was 47.6years which was similar to a study by Chen etal(48years),Fasina etal (30.9+16.6 years)& Srinivasan etal(61 years) .13(75.5%)cases were over the age of 35, indicating that Mooren's ulcer was predominantly a disease of adults, and the ratio of male:female was 1.4:1.i.e., men were 1.4 times more likely to have the disease than women, which is similar to what was reported abroad—1.6 times.[10] In 1971, Wood and Kaufman reported that Mooren's ulcer is more common in men, which is consistent with our findings. The disease was found to be unilateral in 70% cases,similar to the study by Chen etal(70%),Fasina etal (65.2%),Srinivasan etal (64%).The most common presenting feature was found to be redness which was present in (70.5%) cases followed by pain(64.5%). Perforation was noted in 5% which was lower than the 13.3% noted in the study by Chen et al.

CONCLUSION:

Mooren's ulcer although a distinct clinical entity, remains a diagnosis of exclusion. Proper history and thorough evaluation is necessary for diagnosing a case of Moorens ulcer. Chronic serpiginous being its nature, this autoimmune disease has a bad prognosis. Despite of advances made in the step wise approach for management significant proportion of cases still remain refractory to treatment modalities. However, topical & systemic steroids alongwith peritomy & immunomodulators help stabilize the disease progression to some extent.

REFERENCES:

1. V. S. Sangwan, P. Zafirakis, and C. S. Foster, "Mooren's ulcer: current concepts in management," Indian Journal of Ophthalmology, vol. 45, no. 1, pp. 7–17, 1997.
2. Bowman W: Case 12, pll2 in The parts concerned in the operations of the eye (1849),

cited by Nettleship E: Chronic Serpiginous Ulcer of the Cornea (Mooren's ulcer). Trans Ophthalmol Soc UK 22:103-144,190
3. Mckenzie H: Disease of the Eye. 1854, p 631
4. Mooren A: Ulcus Rodens. Ophthalmiatrische Beobachtungen. Berlin, A. Hirschwald:107-110, 1867
5. http://www.ijo.in/article.asp?issn=0301-4738;year=1997;volume=45;issue=1;spage=7;epage=17;aulast=Sangwan;aid=IndianJOphthalmol_1997_45_1_7_15030
6. B. Kietzman, "Mooren's ulcer in Nigeria," American Journal of Ophthalmology, vol. 65, no. 5, pp. 679–683
7 P. G. Watson, "Management of Mooren's ulceration," Eye, vol. 11, no. 3, pp. 349–356, 1997.
8. C. Y. Chow and C. S. Foster, "Mooren's ulcer," International Ophthalmology Clinics, vol. 36, no. 1, p. 1, 1996.
9. D. H. Kim, M. K. Kim, W. R. Wee, and J. Y. Oh, "Mooren's ulcer in a cornea referral practice in Korea," Ocular Immunology and Inflammation, vol. 24, no. 1, pp. 1–5, 2016
10. Lewallen S, Courtright P(1990) Problems with current concepts of the epidemiology of Mooren's corneal ulcer. Ann Ophthalmol 22:52–55.