ORIGINAL RESEARCH PAPER

Volume-7 | Issue-2 | February-2018 | PRINT ISSN No 2277 - 8179

INTERNATIONAL JOURNAL OF SCIENTIFIC RESEARCH

MORPHOLOGICAL STUDY OF CLAVICULAR RHOMBOID IMPRESSION IN SOUTH INDIAN POPULATION WITH ITS CLINICAL SIGNIFICANCE.

Anatomy

Vani PC* Assistant Professor, Department of Anatomy, Mahatma Gandhi Medical College & Research Institute, SBV University, Puducherry, India. *Corresponding Author

Malsawmzuali JC Tutor, Department of Anatomy, Mahatma Gandhi Medical College & Research Institute, SBV University, Puducherry, India.

Anbalagan J Professor, Department of Anatomy, Mahatma Gandhi Medical College & Research Institute, SBV University, Puducherry, India.

Rajasekar SS Professor and Head, Department of Anatomy, Mahatma Gandhi Medical College & Research Institute, SBV University, Puducherry, India.

ABSTRACT

Introduction: Morphology of clavicle varies according to race, sex, nutrition status and geographic distribution of the population chosen for study. An in-depth knowledge on morphological appearance of clavicle in relation to rhomboid impression is important for radiologists and physicians. Hence the present study aims to describe the morphology of rhomboid impression in South Indian population.

Materials and method: Hundred adult dry human clavicles obtained from the Department of Anatomy, Mahatma Gandhi Medical College & Research Institute, Puducherry were used for the study. Various patterns of attachment of costoclavicular ligament to clavicle and its surface area were studied. The distance between medial end of clavicle and the medial most point of attachment of costoclavicular ligament at the rhomboid impression was measured by using a vernier caliper.

Results: The most common type of pattern of rhomboid impression was elevated and rough (34%) followed by depressed and rough (24%).The other parameters were recorded and tabulated.

KEYWORDS

Clavicle, Costoclavicular ligament, Rhomboid impression.

Introduction:

Variations in morphology of clavicle occur according to race, nutrition status and geographic distribution of the population under study. The clavicle is placed almost horizontally at the root of neck and presents two ends and a shaft. The medial or sternal end is enlarged, articulates with clavicular notch of manubrium sterni and adjacent superior surface of the first costal cartilage. The flattened lateral end or acromial end articulates with acromian process of scapula. The medial two thirds of shaft on the inferior surface, near sternal end, presents the impression for attachment to costoclavicular ligament (Stranding S, Borley NR, & Gray H, 2008).

The costoclavicular (rhomboid) ligament is disposed as an inverted truncated cone flattened antero-posteriorly with anterior and posterior lamina of ligamentous fibers and a bursa intervening between them (Cave, 1961). By connecting medial end of clavicle with the upper surface of first rib and its cartilage, the rhomboid ligament assists the movements of pectoral girdle. It also stabilizes sterno-clavicular joint by resisting the lateral pull of the pectoralis major muscle and the upward pull by the clavicular head of sternocleidomastoid muscle. This ligament is prone to injury in the painters, construction workers and kayakers (Rani et al., 2011). The rhomboid ligament acts as important land mark during resection of medial end of clavicle for sterno-clavicular instability resistant to conservative treatment (Bisson, Dauphin, & Marzo, 2003).

The attachments of rhomboid ligament produce various morphological traits as tubercles, roughened impressions, shallow groove like fossae, deep fossa. A pit or depression at this site is called “rhomboid fossa”. These being normal variants of clavicle, may be misinterpreted as pathological conditions (Bisson, Dauphin, & Marzo, 2003 ; Paraskevas et al., 2009). Rhomboid impression has been used in anthropology as a criteria for age and sex estimation (Prado et al., 2009). The subclavian vein is present just behind the costoclavicular ligament, thus this anatomical relation becomes crucial while placing venous catheters and pacemakers (Harada et al., 2005; Krutchen et al., 1996; Magney et al., 1993).

The present study aims to study the morphology of clavicle in relation to the rhomboid impression with its clinical significance and to highlight the anatomical characteristics and normal variants of clavicle in South Indian population.

Materials and methods:

The present study has been approved by the ethics committee of our institution with respect to the human rights. The morphological features of rhomboid impression was studied using 100 fully ossified adult human clavicles of unknown age and sex (50 right and 50 left sided) collected from the Department of Anatomy, Mahatma Gandhi Medical College & Research Institute, SBV University, Puducherry. Bones having distorted gross morphological features, obliterated anatomical landmarks and pathological changes were excluded from the study. The side determination of the bones was done using various anatomical features (Stranding S, Borley NR, & Gray H, 2008).

The attachment of rhomboid ligament to the clavicle was identified on the medial end of inferior surface of clavicle (Fig 1).The various patterns of rhomboid impression was observed macroscopically by direct inspection and classified into 6 types as follows (Cave, 1961)

Type IA: Flat and Rough
Type IB: Flat and Smooth
Type IIA: Elevated and Rough
Type IIB: Elevated and Smooth
Type IIIA: Depressed and Rough
Type IIIB: Depressed and Smooth

The marginal outline of the rhomboid impression on the surface of the bone was outlined onto an Over Head Projector Sheet (OHP sheet).This outline was then overlaid on a graph sheet to calculate the surface area of the rhomboid impression. The distance between the medial end of clavicle and the medial most point of attachment of the costoclavicular ligament was measured using Vernier Caliper with accuracy of 0.01mm (Aerospace) (Fig 1). Statistical analysis was done using the SPSS version 13.0 (SPSS Inc, Chicago, IL, USA). Student unpaired “t” test was applied to find statistical difference between the parameters of right and left bones. A p-value less than 0.05 were taken statistically significant.



Fig 1: Inferior surface of right clavicle 1.Rhomboid impression, 2.Distance between the medial end of the clavicle to the medial most point of attachment of the rhomboid ligament

Results:
The rhomboid impression was present in all the 100 clavicles taken up for the study. The bony impression for the costoclavicular ligament attachment to the clavicle was mostly flat (42%) followed by an elevated pattern (34%). Depressed or pit pattern (24%) of rhomboid impression was the less observed. The area of attachment of rhomboid ligament was found to be rough in 84% and smooth in 16% of cases. The distribution of various patterns of attachment of rhomboid ligament to clavicle are shown in Table 1.

Table 1: Distribution of patterns of attachment of rhomboid ligament to clavicle

Side	Pattern of rhomboid impression				
	Rough	Smooth	Flat	Elevated	Depressed
Right	45	5	21	17	12
Left	39	11	21	17	12
Total	84	16	42	34	24

The distribution of the types of rhomboid impression is shown in Table 2.The various types of rhomboid impression on clavicle is shown in Fig.2. The type IIA: Elevated and rough (34%) pattern was the most common on both right and left sided clavicles followed by the type IIB: flat and rough (26%).

Table 2: Distribution of types of rhomboid impression on the clavicle

Type of rhomboid impression	Right sided clavicle (n=50)	Left sided clavicle (n=50)	Total (n=100)
IA: Flat and Rough	17	9	26
IB: Flat and smooth	4	12	16
IIA: Elevated and Rough	17	17	34
IIB: Elevated and Smooth	-	-	-
IIIA: Depressed and Rough	12	12	24
IIIB: Depressed and Smooth	-	-	-

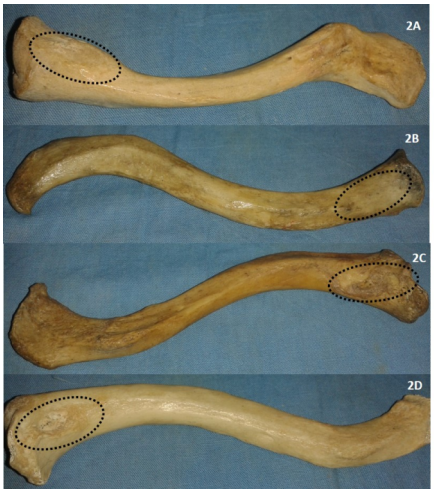

Fig 2.Types of rhomboid impression on clavicle 2A-flat and rough (type IA), 2B-flat and smooth (type IB), 2C-elevated and rough (type IIA), 2D-depressed and rough (type IIIA)

The mean surface area of rhomboid impression was 127mm with arange of 50-320mm. The mean surface area of rhomboid impression was 128.74±46.64mm and 127.21±53.69mm for right and left sided clavicles. The difference in the surface area among the right and left sided clavicles was not statistically significant (p=0.993).The distribution of the clavicles based on the surface area of rhomboid impression is shown in Table 3.

Table 3: Distribution of clavicles based on the surface area of rhomboid impression

Surface area of Rhomboid Impression(mm)	Number of clavicles		
	Total(n=100)	Right(n=50)	Left(n=50)
0-75	14	7	7
76-150	55	25	30
151-225	28	18	10
226-300	2	0	2
>300	1	0	1

The mean distance between medial end of clavicle and medial most point of attachment of costoclavicular ligament was 8.33 mm with a range of 2 mm- 17 mm. Hence resection of 8.33 mm of medial end of clavicle would result in minimal damage to costoclavicular ligament and prevent costoclavicular instability iatrogenically.

Discussion:
A study on clavicles of North American population described the attachment of costoclavicular ligament as tubercles, deep fossae, shallow groove like fossae or no impression but hasn't discussed about the various patterns (Rogers, Flournoy & McCormick, 2000). In a study reported on 153 clavicles of Europeans, it was stated that flat and rough pattern of rhomboid impression was the most common type observed in 20% of right and 38.8% of left clavicles followed by flat and smooth rhomboid impression in 29% (Cave AJE, 1961). Similar results were obtained in another study on 60 clavicles of Vidarbha region of Maharashtra in which flat and rough (Type I) was present in 63.33% of the total cases (Trupti Keshavrao Balvir et al, 2015). A study on 118 Indian clavicles observed the depressed and rough pattern (30.97%) of rhomboid impression as major type. The depressed and smooth (1.77%) being the least (Rani et al., 2011)

But the present study differed from the above and showed elevated and rough (type IIA) as the commonest type of pattern of rhomboid impression present in 34% of specimen followed by flat and rough pattern (type III A) in 26% of specimen. Elevated and smooth, depressed and smooth patterns of rhomboid impression were not observed in the present study. Table 4 shows the comparison on the distribution of types of rhomboid impression between various studies.

Table 4: Comparison between studies on types of rhomboid impression

Types of rhomboid impression	AJE Cave (1961) n=153		Trupti et al.(2012) n=60		Present study n=100	
	R	L	R	L	R	L
Flat & Rough	20	28	18	20	11	7
Flat& smooth	21	21	14	18	4	10
Depressed & Rough	15	12	9	9	12	10
Depressed& Smooth	13	3	5	5	-	-
Elevated & Rough	5	8	7	7	13	13
Elevated & Smooth	4	0	1	1	-	-

R-Right sided clavicle, L-left sided clavicle

The rough attachment of costoclavicular ligament suggests absence of an intervening bursa and its direct attachment to the clavicle. The smooth morphology indicates the presence of intervening bursa between anterior and posterior lamina as described by other authors (Cave, 1961; Stranding S, Borley NR, & Gray H, 2008).

The present study have shown majority of the clavicles (55%) had a surface area of 76-150 mm for the rhomboid impression. To the best of our knowledge there are no studies reported in literature about the surface area of rhomboid impression. Previous studies have shown the importance of rhomboid ligament in resection of medial end of clavicle (Bisson, Dauphin, & Marzo, 2003; Carrera et al., 2007).The mean distance between medial end of clavicle and the medial most point of attachment of costoclavicular ligament was 8.33 mm. Hence a resection length of 8.33 mm on medial side of clavicle is safe without much of damage to the rhomboid ligament. Our study correlates with the study done on 86 cadavers that showed that the resection of 1 cm of medial end of clavicle is safer in 84% of men and 0.9 cm is safe in 89% of women without much disruption of costoclavicular attachment.

Conclusion:
The data obtained in the present study about the morphological variations of rhomboid impression, its surface area and the distance between the medial end of clavicle to the medial most point of attachment of rhomboid ligament will be helpful to radiologists, anesthetists and cardiologists clinically.

REFERENCES
[1] Bisson, L. J., Dauphin, N., & Marzo, J. M. (2003). A safe zone for resection of the medial end of the clavicle. Journal of Shoulder and Elbow Surgery, 12(6), 592–594.
[2] Carrera, E. F., Archetti Neto, N., Carvalho, R. L., Souza, M. A. R., Santos, J. B. G., & Faloppa, F. (2007). Resection of the medial end of the clavicle: An anatomical study. Journal of Shoulder and Elbow Surgery, 16(1), 112–114.
[3] Cave, A. J. E. (1961). The nature and morphology of the costoclavicular ligament.

Journal of Anatomy, 95(2), 170.
[4] Harada, Y., Katsume, A., Kimata, M., Hikosaka, T., Yamanaka, S., Akashi, K., Matsubara, H. (2005). Placement of pacemaker leads via the extrathoracic subclavian vein guided by fluoroscopy and venography in the oblique projection. Heart and Vessels, 20(1), 19–22.
[5] Krutchen, A. E., Bjarnason, H., Stackhouse, D. J., Nazarian, G. K., Magney, J. E., & Hunter, D. W. (1996). The mechanisms of positional dysfunction of subclavian venous catheters. Radiology, 200(1), 159–163.
[6] Magney, J. E., Flynn, D. M., Parsons, J. A., Staplin, D. H., Chin-Purcell, M. V., Milstein, S., & Hunter, D. W. (1993). Anatomical mechanisms explaining damage to pacemaker leads, defibrillator leads, and failure of central venous catheters adjacent to the sternoclavicular joint. Pacing and Clinical Electrophysiology: PACE, 16(3), 445–457.
[7] Paraskevas, G., Natsis, K., Spanidou, S., Tzaveas, A., Kitsoulis, P., Raikos, A., Anastasopoulos, N. (2009). Excavated-type of rhomboid fossa of the clavicle: a radiological study. Folia Morphologica, 68(3), 163–166.
[8] Prado, F. B., de Mello Santos, L. S., Caria, P. H. F., Kawaguchi, J. T., Preza, A. d'O.G, Daruge, J. E.,Daruge, E. (2009). Incidence of clavicular rhomboid fossa (impression for costoclavicular ligament) in the Brazilian population: forensic application. Journal of Forensic Odonto-Stomatology, 27(1), 12–16.
[9] Rani, A., Chopra, J., Rani, A., Mishra, S. R., Srivastava, A. K., Sharma, P. K., & Diwan, R. (2011). A study of morphological features of attachment area of costoclavicular ligament on clavicle and first rib in Indians and its clinical relevance. Biomedical Research, 22(3), 349-54.
[10] Ray, L. J. (1959). Metrical and non-metrical features of the clavicle of the Australian Aboriginal. American Journal of Physical Anthropology, 17(3), 217–226.
[11] Rogers, N. L., Flournoy, L. E., & McCormick, W. F. (2000). The rhomboid fossa of the clavicle as a sex and age estimator. Journal of Forensic Sciences, 45(1), 61–67.
[12] Stranding S, Borley NR, & Gray H. (2008). Gray's anatomy: the anatomical basis of clinical practice. 40th ed., anniversary ed. [Edinburgh]: Churchill Livingstone/Elsevier.
[13] Trupti Keshavrao Balvir et al. (2015). Estimation of stature from the length of clavicle in Vidarbha region of Maharashtra. Int J Biol. Med Res, 3(4), 2535–7.