Original Research Paper

Volume : 5 | Issue : 7 | July 2016 • ISSN No 2277 - 8179 | IF : 3.508 | IC Value : 69.48

MRI Features of Eosinophilic Meningoencephalitis : A Rare Presentation of Neurocysticercosis

Medical Science

KEYWORDS : Neurocysticercosis, Eosinophilic meningoencephalitis, T. solium, MRI, EIA.

Shoibam Subhaschandra Singh	Associate Professor, Department of Radiodiagnosis, RIMS, Imphal
*** Shweta Bhalothia**	Post Graduate Trainee, Department of Radiodiagnosis, RIMS, Imphal , * Corresponding author
Veeraraghavan. G	Post Graduate Trainee, Department of Radiodiagnosis, RIMS, Imphal

ABSTRACT

Neurocysticercosis is the commonest central nervous system parasitic disease worldwide but cysticercal meningoencephalitis without parenchymal cysticercal granulomatous lesions is a rare entity. Here we are reporting radiological features of cysticercal meningoencephalitis in a 6 year old boy, who was admitted to our hospital with history of fever and headache since last three months and recently developed right sided weakness. Cerebrospinal fluid analysis of the patient showed eosinophilia with multiple bilateral cerebral hemispheric lesions at magnetic resonance imaging. Enzyme immune assay demonstrated IgG cysticercosis antibody in serum. Improvement in clinical and laboratory results was achieved using albendazole and corticosteroids.

CASE REPORT

A 6 year old boy was admitted to our hospital for right sided weakness, for 2 days. He had a history of fever and headache, since last three months. There was no history of seizures. On examination the patient was febrile. A right inguinal hernia and rashes were noted on general physical examination. Cranial nerve examination showed left facial nerve palsy. On motor examination, hypotonia on the right side of the body noted with grade four power in upper and lower extremities. Babinski sign was present on the left side. Mental status was normal. Fundoscopy revealed papilloedema.

Laboratory investigations gave the following results: Hemoglobin 8.4 g/dl (normal range: 11 - 15 g/dl); total white blood cell count 6,570 cells/mm^3 (normal range: 4000 – 10,000 cells/mm^3); differential count – neutrophils: 36%, lymphocytes: 59%, monocytes: 3%, eosinophils: 2%; platelets adequate; and erythrocyte sedimentation rate 126 mm/1st hour (normal range: 0 – 20 mm). Pleural fluid ADA (0.9 U/L) noted within normal range. Serum electrolytes, renal and liver function tests were within normal limits. Chest X-ray did not reveal any abnormality.

CSF analysis showed the following results: Total cell count 520 cells/μL (normal range 0–5 cells/μL); differential count – eosinophils: 75%, lymphocytes: 15%, neutrophils: 10%; RBC 4+; protein 100 mg/dl (normal range 15 – 60 mg/dl); and glucose 13 mg/dl (normal range 40 – 80 mg/dl). Gram stain and Ziehl–Neelsen stain did not reveal any organism. CSF culture was negative.

Computed tomography scan of his brain was normal. MRI brain revealed multiple fluffy nodular hyperintense signals in T2-weighted MR images involving the deep white matter of bilateral frontal lobes and left parietal lobe [Fig. 1a-b], left centrum semiovale [Fig. 1c] and left pons [Fig. 1d]. Similar findings were noted in the fluid attenuated inversion recovery (FLAIR) sequence [Fig. 1e-h]. The lesions were more distinct on the diffusion imaging. The diffusion weighed images [Fig. 2a-b] were showing hyperintense deep white-matter lesions with corresponding low signal intensity on the axial ADC map Fig. 2c-d], reflecting restricted diffusion. The lesions were appearing relatively hypointense on T1-weighted images [Fig. 3a] with focal enhancement of the genu of corpus callosum [Fig.3b]. Subtle enhancement of the basal meninges was also noted [Fig. 3c].

Serum analysis - Fluoroimmunoassay was non - reactive for IgG & IgM Toxoplasma antibody. Enzyme immune assay (EIA) demonstrated high titer of IgG cysticercosis antibody in serum [Index 1.63 U with Bio. Reference Interval < 0.9 U].

The patient received oral albendazole and prednisolone for 2 weeks and was discharged after gradual improvement of symptoms as well as laboratory results.

DISCUSSION

Cysticercosis, the most common and serious parasitic infection of the central nervous system, is the result of infection with intermediate stage of *Taenia solium,* the pork tapeworm**.** The intermediate stage of *T. solium* is infectious for humans and preferentially invades the CNS, causes neurocysticercosis**.** Humans acquire the intermediate stage by ingestion of food or water contaminated with the eggs of *T. solium* [1].

In most of the developing countries, NCC comprises 10% of acute neurologic cases. Epilepsy is the usual presentation, other known manifestations include raised intracranial pressure, meningoencephalitis, focal neurological deficit and psychiatric symptoms [2]. The entity of eosinophilic meningoencephalitis as part of the spectrum of NCC is observed to be rare in comparison to other symptoms. A very few cases have been reported in the literature [3-4].

The diagnosis of eosinophilic meningoencephalitis is based on clinical manifestations and microscopic identification of eosinophils present in cerebrospinal fluid (CSF). CSF eosinophilia is defined by counts higher than 10 eosinophils per ml or 10% of the total CSF leukocyte count. Although any tissue-migrating helminths can cause eosinophilic meningitis, the most common cause is human infection with *Angiostrongylus cantonensis*. Other parasites that can cause eosinophilic meningitis include *Gnathostoma spinigerum*, *Baylisascaris procyonis*, *Toxocara canis, Toxoplasma gondii,* and *T. solium.* Neurocysticercosis is most frequent cause of eosinophilia in CSF [3,5], although cysticercal meningitis is uncommon in India [3].

Radiologic abnormalities in eosinophilic meningitis have been described rarely, though MR findings may aid premortem diagnosis and help predict the prognosis. A few MR findings in previously reported cases of eosinophilic meningoencephalitis include hyperintense signals throughout the cerebral cortex on T2-weighted images. Abnormal enhancing subcortical, periaqueductal and basal cisternal lesions probably related to disruption of the blood-brain barrier caused by the eosinophilic inflammatory reactions, are also described [6]. The brain computed tomographic (CT) scan can be normal or can reveal cerebral edema, ventricular dilatation, enhancing ring or disc lesions, resembling tuberculomas [7].

Cysticercal meningoencephalitis is caused by infiltration of the meninges and the parenchyma of the brain by a large number of parasites, and inflammation in the surrounding tissue is responsible for meningitis and encephalitis [3].

Around 60% cysticercal meningoencephalitis cases have been reported to have associated brain parenchymal lesions [3]. Imaging features of parenchymal neurocysticercosis varies with stages. Vesicular stage exhibits cyst with "dot" (scolex), without significant edema or enhancement. Colloidal vesicular stage appears as ring enhancing lesion with striking edema. In granular nodular stage faint rim enhancement can be seen. A small calcified nodule without surrounding edema or enhancement is seen in nodular calcified stage [8].

In a previous case report of cysticercal meningitis, contrast enhanced CT study of the brain showed single hypodense lesion with an eccentric enhancing mural nodule suggestive of granulomatous parenchymal lesion [3]. In another case report by Amir M. et al. MR study of brain revealed multiple intraparenchymal and intraventricular cysticercal lesions (peripheral rim enhancing lesions) with hydrocephalus [9]. Our MR findings revealed T2 hyperintense signal involving deep white matter. These are nonspecific findings that may indicate small vessel ischemic changes, demyelination or gliosis. Focal enhancement of genu of the corpus callosum was noted, without any specific imaging feature of granulomatous parenchymal lesion.

The CSF findings in cysticercal meningitis consist of pleocytosis (usually lymphocytic but frequently polymorphonuclear), reduced glucose and elevated protein, with up to 70% patients with cysticercal meningitis having CSF eosinophilia between 2-40% [3].

There are no guidelines for the treatment of acute cysticercal meningitis. Anti-parasitic therapy is recommended for chronic meningitis [10]. Albendazole is the antiparasitic drug of choice. Associated seizures can be readily controlled using standard anticonvulsants [1]. Steroids may decrease the duration of headache in adults with eosinophilic meningitis [5].

The prognosis of eosinophilic meningitis is good; 70% of patients improve sufficiently to leave the hospital in 1–2 weeks, presence of motor deficit and coma can worsen the prognosis [11]. Mortality associated with eosinophilic meningitis is < 1% [5].

TEACHING POINTS

Cerebral cysticercal infestations are usually seen as inflammatory granulomas of different stages. The differential diagnosis of cysticercal meningoencephalitis should always be considered in case of CSF eosinophilia even in the absence of typical inflammatory granulomatous lesions.

ACKNOWLEDGMENTS

Authors acknowledge the immense help received from the scholars whose articles are cited and included in references of this manuscript. The authors are also grateful to authors/ editors/publishers of all those articles, journals and books from where the literature for this article has been reviewed and discussed.

Figure 1

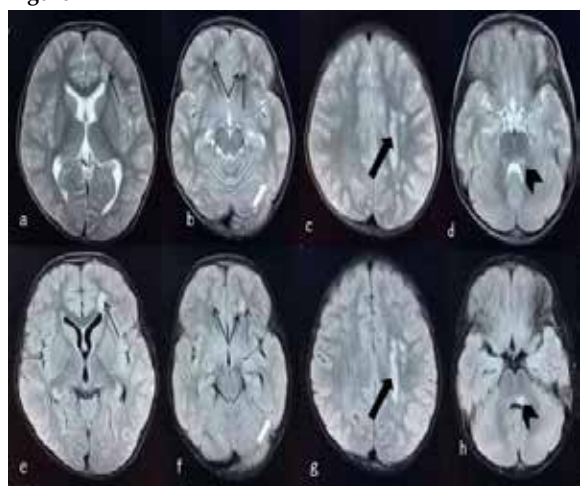

A 6 year old boy with cysticercal eosinophilic meningoencephalitis. Axial T2 weighted MR images [Fig. 1a-d] are showing multiple fluffy nodular hyperintensities, involving the bilateral frontal lobes (thin arrows), left parietal lobe (solid white arrow), left centrum semiovale (solid black arrow) and pons in left paramedian plane (arrowhead). (Protocol: Magnet strength - 1 Tesla, TR- 4000, TE - 99, slice thickness – 5 mm, FOV- 187*230). Axial FLAIR (1e-h) images are demonstrating similar findings. (Protocol: Magnet strength - 1 Tesla, TR - 9000, TE - 112, slice thickness – 5 mm, FOV - 187*230).

Figure 2

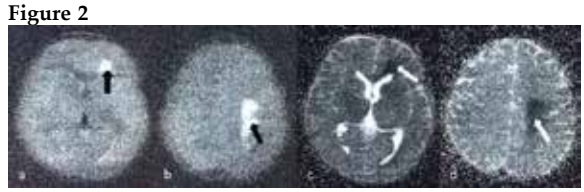

A 6 year old boy with cysticercal eosinophilic meningoencephalitis. Axial DWI (2a-b) are showing hyperintense deep white-matter lesions (solid black arrows) with corresponding low signal intensity (solid white arrows) on the axial ADC map (2c-d), reflecting restricted diffusion. (Protocol: Magnet strength – 1 Tesla, TR - 3000, TE - 123, FOV - 226; b value - 900/180).

Figure 3

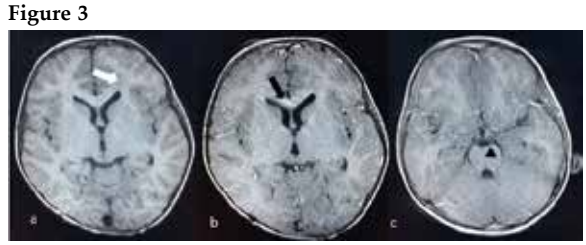

A 6 year old boy with cysticercal eosinophilic meningoencephalitis. Axial T1 weighted (3a) MR image showing relatively low signal intensity, involving the left corona radiata (solid white arrow). Post Gadolinium (5 ml) contrast im-

Volume : 5 | Issue : 7 | July 2016 • ISSN No 2277 - 8179 | IF : 3.508 | IC Value : 69.48

ages (3b) demonstrating focal enhancement of genu of corpus callosum (solid black arrow) with subtle enhancement of the meninges (arrowhead). (Protocol: Magnet strength - 1 Tesla, TR - 500, TE - 14, slice thickness – 5 mm, FOV - 187*230).

REFERENCES

1. Blanton R. **Cysticercosis. In:** Kliegman RM, Behrman RE, Jenson HB, Stanton BF, editors. Nelson textbook of pediatrics. 18th ed. Philadelphia: Elsevier, 2007; 1234-36. ISBN: 9781437707557
2. Parija SC, Sahu PS, Dhanya H. Detection of Cysticercus antigens and antibodies in cerbrospinal fluid of patients with chronic meningitis. Rev Inst Med trop Oct2007;49(5):331-4. PMID:18026642
3. Mishra D, Sharma S, Gupta S, Das M, Chauhan D. Acute Cysticercal Meningitis– Missed Diagnosis. Indian J Pediatr 2006;73(9):835-37. PMID: 17006046
4. Iglesiasa CH, Moulya S, Ducrosb A, Sarfatic C, Sulahianc A, Bergmanna JF. Late-onset eosinophilic chronic meningitis occurring 30 years after Taenia solium infestation in a white Caucasian woman. Journal of Infection July 2006;53(1):35-38. PMID: 16253336
5. Prober CG, Dyner L. **Central Nervous System Infections. In:** Kliegman RM, Behrman RE, Jenson HB, Stanton BF, editors. Nelson textbook of pediatrics. 18th ed. Philadelphia: Elsevier, 2007; 2086-100. ISBN: 9781437707557
6. Kanpittaya J, Jitpimolmard S, Tiamkao S, Mairiang E. MR Findings of Eosinophilic Meningoencephalitis Attributed to Angiostrongylus cantonensis. AJNR June/July2000;21(6):1090–94. PMID: 10871020
7. Tsai HC, Liu YC, Kunin CM, et al. Eosinophilic Meningitis Caused By Angiostrongylus Cantonensis Associated With Eating Raw Snails: Correlation Of Brain Magnetic Resonance Imaging Scans With Clinical Findings. Am J Trop Med Hyg 2003;68(3):281–85. PMID: 12685630
8. Osborn AG. Osborn's brain: imaging, pathology, and anatomy. Salt Lake City, Utah: Amirsys Pub; 2013. ISBN: 9781931884211
9. Torabi AM, Quiceno M, Mendelsohn DB, Powell CM. Multilevel Intramedullary Spinal Neurocysticercosis With Eosinophilic Meningitis. Arch Neurol May 2004;61(5):770-72. PMID: 15148157
10. Garcia HH, Evans CAW, Nash TE, et al. Current consensus guidelines for the treatment of Neurocysticercosis. Clin Microbiol Rev 2002;15(4):747-56. PMID: 12364377
11. Delgado MJF, Cruz GCTR, Mendez RA. Eosinophilic meningoencephalitis in Villa Clara (Cuba). A study of 17 patients. Rev Neurol Sep 2000;31(5):417-21. PMID: 11027091

ABBREVIATIONS

MRI- Magnetic resonance imaging
EIA- Enzyme immune assay
CT- Computed tomographic
NCC- Neurocysticercosis
CSF- Cerebrospinal fluid
FLAIR- Fluid attenuated inversion recovery
DWI- Diffusion weighted images
ADC- Apparent diffusion coefficient