VOLUME-6 | ISSUE-2 | FEBRUARY-2017 • ISSN No 2277 - 8179 | IF : 3.508 | IC Value : 78.46

NEGLECTED URETERAL D J STENT –OUR EXPERIENCE AND REVIEW OF LITERATURE.

Urology

KEYWORDS: Neglected , Double J stent, Complication

Mandeep Phukan	Assistant Professor , Department of Urology , Gauhati Medical College
Debanga Sarma	Assistant Professor , Department of Urology , Gauhati Medical College
Rajeev T. P.	Professor and Head of the Department , Department of Urology , Gauhati Medical College
S. K. Barua	Associate Professor , Department of Urology , Gauhati Medical College
Jyoti P. Morang	MCh trainee , Department of Urology , Gauhati Medical College
P. K. Bagchi	Associate Professor , Department of Urology , Gauhati Medical College

ABSTRACT

Introduction : A stent is a important armamentarium used in segment of a tubular organ to drain or relieve obstruction. There are no universal guidelines regarding their use, handling and effect. DJ stent associated with various complication.

Material and Methods: Datas reviewed retrospectively from January 2010 to January 2015 for patients with retained DJ stent . All patients with retained DJ stent attending to the Department of Urology were included in our study and patients with ureteral DJ stent in situ for less than 6 months were excluded. Patients were evaluated and various procedures were performed to make them stent free.

Results : A total 26 retained DJ stent cases were enrolled in our study. 21 were men and 5 women (M : F =80 % : 19.23%) with a mean age of 34 years (range 18–69 years). The encrustation was confined to the upper end in 4 and the upper end and body in 3 and the lower end in 8 ,of which 3 were fragmented as well. A total of 62 sessions of auxiliary procedures were required to render patients stent free.

Conclusion : Double J stent used various urological procedures. It has different type of complication. It may be stent itself related , handling procedure or various patients related or due to health professionals. Proper universal guidline regarding its use probably will reduce its complications.

Introduction :

A stent is a scaffold in segment of a tubular organ to drain or relieve obstruction. As a foreign body it has various adverse effects in body. There are various advances in stent biomaterials and design, Double J (DJ) stents are not free of complications and there are no universal guidelines regarding their use, handling and effect [1]. Complications of D J stent may be categorized as early and late complication. Late complication may lead to the most significant morbidity or even mortality to the patient. In this study we tried to assess the management approaches and results in patients with retained and neglected ureteral DJ stents who presented to our centre and brief review of literature.

Material and Methods:

Medical records of Department of Urology, Gauhati Medical College were reviewed retrospectively from January 2010 to January 2015 for patients with retained DJ stent . All patients with retained DJ stent were included in our study and patients with ureteral stent in situ for less than 6 months were excluded . Patients presented to our department with retained DJ stent which were placed during treatment for renal and ureteral calculi by extracorporeal shockwave lithotripsy (ESWL), ureteral calculi, after percutaneous nephrolithotomy, pyeloplasty, or in case of renal and ureteral injury. Total 26 cases with retained DJ stents were included in our study. We recorded patient history , physical examination findings and investigations like Routine Urine Examination and culture/sensitivity, Routine Blood Examination, Random Blood sugar, Serum creatinine , blood urea ,X-Ray KUB, Ultrasonography KUB, DTPA Renal Scan.

After proper evaluation we performed various endourological and open surgical procedures necessary for retrieval of the stent and final outcome was analysed.

RESULTS :

A total 26 retained DJ stent cases were enrolled in our study. 21 were men and 5 women (M : F =80 % : 19.23%) with a mean age of 34 years (range 18–69 years) with right sided retained stent in 15 cases , left sided 9 cases and bilateral in 2 cases. The average duration of stent placement was 14 months (range 7 months–9 years).

Indication for stent placement :

Pyelolithotomy	-8
Pyeloplasty	-3
Ureterolithotomy	-9
Post URSL	-1
For ESWL	-2
VVF Repair	-1
Bilateral Renal Calculi with CRF	-1
Nephrolithotomy	-1

The encrustation was confined to the upper end in 4 and the upper end and body in 3 and the lower end in 8 ,of which 3 were fragmented as well. In 16 (61.58 %) patients serum creatinine was more than 1.30 mg/dl with a mean of 1.8 mg/dl (range 0 .89 – 7.6 mg/dl)

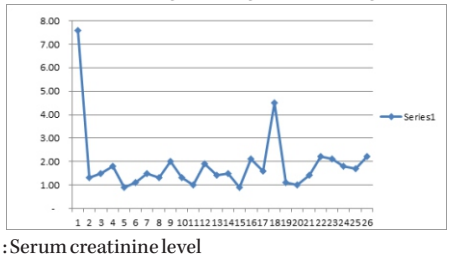

Figure 1 : Serum creatinine level

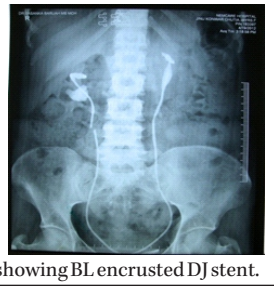

Figure 2 : X ray KUB showing BL encrusted DJ stent.



Figure 3: Encrusted and expulsed DJ stent from a male patient.

A total of 62 sessions of auxiliary procedures were required to render patients stent free. They underwent one or more of the following procedures to make them stent free with an average of 2.21 procedures per side.

Extracorporeal lithotripsy	-12
ESWL and retrograde ureteroscopic manipulation	- 4
Cystolithotomy	- 4
cystolithotripsy	- 3
cystolithotomy and pyelolithotomy	-1
ESWL -pyelolithotomy – ureteroscopic manipulation	- 1
cystolithotripsy and ureteroscopic manipulation	-1

Discussion :

Ureteral stents are used commonly in urology practice now a days to prevent or relieve ureteral obstruction. Double J stent indwelling time should be as short as possible. If indwelling stenting is necessary for prolonged period it should be replaced with a new one in due time or alternative procedures should be performed. Vigilant follow-up and patient counseling could exclude possibility of a stent being forgotten at all [2]. Neglected ureteral stents are hazardous to patient and can cause various morbidity due to migration, occlusion, encrustation, breakage, stone formation, and even death, due to life-threatening urosepsis or complications related to operative intervention [3]. It may also have adverse economical impact on patient as well as health care facilities mainly in developing countries like India as these facilities are already over stressed. Various studies concluded that prevention of "forgotten stent" is easy with awareness and so its complications [4]. Long-term complications of DJ stents are associated with prolonged indwelling times. All stents loose tensile strength after certain spatulated time period according to the makers, cracks are started at the holes initially leading to breakage of the stents [5]. Some time neglected stent may lead to deterioration of the renal function. Thomas AZ concluded that texisting system of ureteric stent follow-up is not effective. So we have to introduced a new system that we feel is a safer and a satisfactory alternative to the stent logbooks. This includes a patient education leaflet and removal date scheduling prior to discharge from hospital [6] which is following in our institution now. Incidence of broken double J stent is 1.3% - 57.89% [7]. Migration can occur either way but upward migration is more common[8]. It is related to stent design and faulty technique of insertion. The incidence of stent migration 9.5%.-26.32% [7]. Stone encrustation is another problem in long term use . Risk factors are chronic recurrent stone formers with a lithogenic history, uricosuria, chronic renal failure, congenital anomalies, urinary tract infection, stasis, dehydration and long indwelling times[9]. DJ stent related complication is not uncommon even in the era of modern urology even in the developed world. Fortunately such unwanted complications could be managed successfully with the use of endourological techniques in most of the times. Extracorporal lithotripsy ,Cystolithotripsy and ureterorenoscopic lithotripsy with a Holmium laser also also has been reported to remove the D-J stent[10]. Open procedures to removed the neglected double J stent are usually reserved for selected cases.

The following measures can be adopted to increase the compliance of the patient [9]

1. Counseling of the patient.
2. Selection of the appropriate stent size
3. Giving Post procedure X-ray to the patient to show the stent left in the body
4. Maintaining registry of the patients with double J stent to ensure timely replace or removal [11]
5. Further imaging was necessary both medically and legally to exclude a retained stent or part of a stent.

Conclusion:

Neglected double J stent leading to encrustation and retention is a serious complication. Successful management of encrusted retained stents requires multimodality procedures. With proper record keeping of stent insertion and removal and patient counseling incidence of neglected double J stent and its complications can be prevented and reduced which is beneficial not only to the patient but also to health care provider.

Reference

1. Saltzman B. Ureteral stents. Indications, variations, and complications. Urol Clin North Am 1988;15:481-91.
2. Ivica S, Dragan . Long-term indwelling double-J stents: bulky kidney and urinary bladder calculosis, spontaneous intraperitoneal perforation of the kidney and peritonitis as a result of "forgotten" double-J stent. Vojnosanit Pregl 2009 Mar; 66(3):242-4.
3. Ferruti M, Paparella S, Cozzi G, Oliva I, Finkelberg E, Maggioni A, Rocco F. Single session cystolitholapaxy and PCNL for encrusted DJ stent with large associated stone burden. Urologia. 2010 Oct-Dec;77(4):267-70.
4. Bhuiyan ZH, Bhuiyan NI, Khan SA, Tawhid MH, Islam MF. Forgotten urological stent. Mymensingh Med J. 2011 Oct;20(4):632-9.
5. Kumar M, Aron M, Aggarwal AK, Gupta NP. Stenturia: An unusual manifestation of spontaneous ureteral stent fragmentation. Urol Int. 1999;62:114–6.
6. Thomas AZ , Casey RG, Grainger R, McDermott T , Flynn R, Thornhill . The forgotten ureteric JJ stent and its prevention: a prospective audit of the value of a ureteric stent logbook. JA Ir J Med Sci. 2007 Jul-Sep;176(2):117-9.
7. Rajendra Prasad Ray, Rajkumar Singha Mahapatra, Partha Pratim Mondal, and Dilip Kumar Pal. Long-term complications of JJ stent and its management: A 5 years review. Urol Ann. 2015 Jan-Mar; 7(1): 41–45.
8. Lawrentschuk N, Russel JM. Ureteric stenting 25 years on: Routine or risky? ANZ J Surg. 2004;74:243–7.
9. Singh I. Indwelling JJ ureteral stents - a current perspective and review of literature. Indian J Surg. 2003;65:405–12.
10. Tsai CC1, Shen JT, Huang SP, Chang SF, Tsai LJ, Wu WJ, Huang CH . Use of a Holmium laser to treat a forgotten double-J stent with whole stent encrustations: a case report. Kaohsiung J Med Sci. 2009 Oct;25(10):567-71.
11. Finney RP. Experience with new double J ureteral catheter stent. J Urol. 1978;120:678–81. [PubMed: 731804]