ORIGINAL RESEARCH PAPER

Volume-7 | Issue-11 | November-2018 | PRINT ISSN No 2277 - 8179

INTERNATIONAL JOURNAL OF SCIENTIFIC RESEARCH

NOTOMELIA : A RARE CASE OF POLYMELIA

Neurosurgery

K B Shankar* Head of Department, Department of Neurosurgery, Safadarjung Hospital & Vardhman Mahavir Medical College, New Delhi,India *Corresponding Author

Manish Rawat Assistant Preofessor, Department Of Neurosurgery, Safadarjung Hospital & Vardhman Mahavir Medical College, New Delhi,India,

Maulik B Patel 3rd year resident, Department Of Neurosurgery, Safadarjung Hospital & Vardhman Mahavir Medical College, New Delhi,India,

ABSTRACT

BACKGROUND: Polymelia (from Greek poly= many, melia = limb) or supernumerary limb is very rare congenital anomaly reported in humans. Notomelia is when extra limb attached to dorsum of body.

KEYWORDS

Polymelia, Notomelia, Neural Tube Defect, Meningocele

CASE REPORT:
Our patient is 8 months old girl child presented to us with accessory limb arising from nape of neck from birth. She is the 4th living issue born by non consangenious marriage; full term vaginal home delivery. Parents belong to low socio- economic strata. The earlier issues were all uneventful delivery with no congenital anomaly.

The child's parents noted this accessory limb arising from nape of neck from birth. The limb had grown in size with age of child. But it remained non functional. Child had no other symtoms; no other congenital anomaly. She had normal developmental milestones and was able to hold her neck. The accessory limb showed limited spontaneous movements only.

The clinical examination revealed normal other limbs with no neurological deficit. The accesseory limb had formed arm; forearm and hand. It was attached posteriorly at nape of neck in midline to upper cervical vertebrae.

Imaging and management
Child was investigated with MRI and CT Angio Neck and Cervical Spine.

This revealed C1; C2 and C3 vertebrae as bifid with meningocele with attached accessory limb bone to posterior elements of C1 C2 vertebrae. The forearm bone was partially splited single bone. Hand showed metacarpals and phalanges. The vascular supply was from branches of vertebral artery. Spinal cord was normal.

Patient was operated in prone position. The vascular supply first controlled and limb excised at bony attachment. Child tolerated the procedure well and discharged on 5th post OP day.

DISCUSSION
Polymelia (from Greek = many, melia = limb) is a birth defect involving limbs in which affected individual has more than usual number of limbs. Extra limb is most commonly shrunken and/or deformed. There are only few cases described in human beings. Many cases have been described in animals.

The notomelia is when extra limb is attached to back.

Limb differentiation occurs roughly between 4th and 5th weeks of embryonic development,[5] and it follows a dorsal to ventral and proximal to distal pattern, with many factors involved in the process.[3,4]

Initially, two pairs of limb buds – anterior and posterior – protrude from both sides of the embryo, and comprise cells of ectoderm and mesoderm. Their interaction is responsible for cell positioning and limb differentiation. The covering ectodermal layer of the limb bud is termed the apical ectodermal ridge (AER). The zone of proliferating activity (ZPA), another group of cells is located subjacent to the AER. Both are necessary for limb development. Mesodermal cells in the ZPA stimulate AER formation and the AER maintain the ZPA.[6,7]

The level and manifestation of limb deformity can thus be used to determine approximate timing of teratogenic event that occurred during limb development. As the AER grows more distal, the induced mesoderm cells, comprising rudimentary parts of the limb, can continue to grow without any developmental interference even if AER is transplanted to adjacent region. This leads to an assumption that duplication of limb arises from the influence of AER with abnormal splitting creating two sets of limbs.[8,9]

A case of left lower limb polymelia with limb rudimentary limb attached to left hip joint was successfully operated.[10] 5 rare interesting cases are available on link http://www.itervis.com/rarest-cases-of-polymelia-in-humans/5/. The case presented by us had not been reported in literature before. The child was named Santoshi and was being considered special child and sometimes was also being sought after for blessings (as goddess) in her village.

CONCLUSION
In our case, child had favorable outcome and evolution subsequent to surgery, with no sequelae or disability whatsoever to date.Many factors could be attributed to this anomaly including use of teratogenic drugs during pregnancy, genetic factors and in vitro fertilisation techniques. Treatment for such cases is surgical. Incision have to planned to give good cosmetic result.



Figure 1 : Pre operative

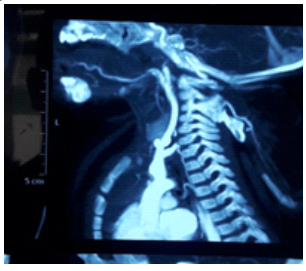

Figure 2 : Accessory limb bone attached to posterior elements of C1 C2

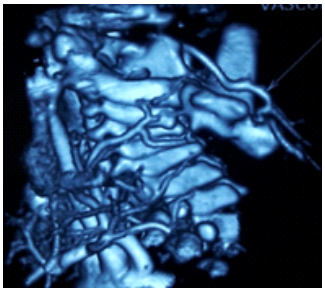

Figure 3 : CT Angio neck showing vascular supply from vertebral artery



Figure 4 : Patient kept in prone position

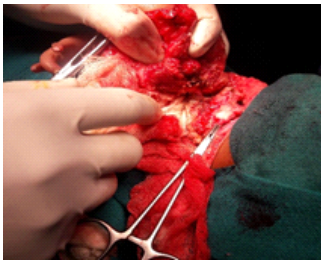

Figure 5 : vascular supply first controlled



Figure 6 : Post op.image

REFERENCES

1. Griffet J, Bastiani-Griffet F, Jund S, Moreigne M, Zabjek KF. Duplication of leg - Renal agenesis: Congenital malformation syndrome. J Pediatr Orthop B. 2000; 9:306–8.
2. La Torre R, Fusaro P, Anceschi MM, Montanino-Oliva M, Modesto S, Cosmi EV. Unusual case of caudal duplication (dipygus) J Clin Ultrasound. 1998;26:163–5.
3. Kher AS, Gahankari DR, Tambwekar SR, Doraiswamy A, Iyer S, Bharucha BA, et al. Supernumerary limbs: A case report of rare congenital anomaly. Ann Plast Surg. 1996;37:549–52.
4. Kojima T, Hirakawa M, Hirase Y, Hwang KH. Complete congenital duplication with incomplete separation of a lower extremity. Plast Reconstr Surg. 1993;91:926–9.
5. O'Rahilly R, Muller F. Developmental Stages in Human Embryos. Washington: Carnegie Institution; 1987. Publication No 637.
6. Roberts DJ, Tabin C. The genetics of human limb development. Am J Hum Genet. 1994;55:1–6.
7. Scherz PJ, Harfe BD, McMahon AP, Tabin CJ. The limb bud Shh-Fgf feedback loop is terminated by expansion of former ZPA cells. Science. 2004;305:396–9.
8. Packard DS Jr, Levinsohn EM, Hootnick DR. Extent of duplication in lower-limb malformations suggests time of teratogenic insult. Pediatrics. 1993;91:411–3.
9. Zhao L, Li MQ, Sun XT, Ma ZS, Guo G, Huang YT. Congenital lumbosacral limb duplication: A case report. J Orthop Surg (Hong Kong) 2006;14:187–91.
10. Satyajeet Verma, Manish Khanna, V. N. Tripathi,and N. C. Yadav Occurrence of Polymelia in Female Child J Clin Imaging Sci. 2013; 3: 18.