VOLUME-6 | ISSUE-3 | MARCH - 2017 • ISSN No 2277 - 8179 | IF : 4.176 | IC Value : 78.46

Ocular manifestations of dengue hemorrhagic fever and its relation to platelet count.

Ophthalmology

KEYWORDS: Dengue, petechial hemorrhages, macular edema.

Dr. Ritu Agarwal	2nd year resident, Dept. of ophthalmology,SPMC, Bikaner. SPMC, Bikaner.e Professor, Department of Plastic Surgery, Christian Medical College, Ludhiana
Dr. Kalpna Jain	Professor, Dept. of ophthalmology, SPMC, Bikaner.
Dr. Jaishree Murli Manoher	Professor and Unit head, Dept of ophthalmology, SPMC, Bikaner.

ABSTRACT

PURPOSE: To study ocular manifestations of dengue hemorrhagic fever and its association with platelet count

METHODS: Cross sectional observational study of 30 patients was done at PBM hospital, Bikaner. IgM and IgG positive dengue cases were selected over 4 months period. Ocular and systemic examination was carried out during hospitalization and follow up visits

RESULTS: From 30 patients 25(83.3%) were males and 5(16.7%) were females. Mean age was 32 years. Ocular manifestations were present in 19(63.3%) patients from which 15(50%) patients had petechial subconjunctival hemorrhage and 5 (16.7%) patients had dot, blot hemorrhages and macular edema. All 16(53.3%) patients with platelet count of <35,000/µl had ocular manifestations. Ocular changes resolved in all the cases after 6 weeks.

CONCLUSION: Incidence of ocular complications in dengue is increasing hence all patients should be referred to ophthalmologist to prevent any sight-threatening complications.

Introduction

Dengue is self-limiting common arthropod-borne viral disease which is transmitted to humans by mosquitoes. It is endemic in tropics and warm temperate regions of the world. It is caused by 4 antigenically similar but immunologically distant serotypes of dengue virus of genus flavi virus, transmitted by Aedes Aegypti mosquito. Highest incidence occurs in South Asia and American tropics.[1]

Dengue infection is characterized by an abrupt onset of fever along with symptoms of malaise, sore throat, rhinitis, cough, headache, muscle ache, retro-orbital pain, lumbosacral pain, and rash. Other clinical manifestations of dengue are related to the bleeding diathesis from thrombocytopenia.[2]

A myriad of ocular manifestations ranging from mild subconjunctival hemorrhage to vision threatening complications such as optic neuropathy and panophthalmitis have been reported in literature.3-9 The main ocular manifestations included conjunctival hemorrhages, macular edema and retinal hemorrhages. Less common features included exudative retinal detachment, anterior uveitis, periphlebitis, branch retinal vein occlusion, and vitreous hemorrhage. A majority of patients were reported to have retro-orbital pain that can be due to sinusitis or due to myalgia. Visual impairment occurs secondary to maculopathy and optic neuropathy.5,8 The main objective of this study was to evaluate the ophthalmic manifestations associated with dengue hemorrhagic fever

Materials and Methods

A cross sectional observational study was conducted in 30 patients of dengue hemorrhagic fever, who were admitted in Sardar Patel Medical College and PBM hospital, Bikaner (Rajasthan) India. The study was carried out for a period of 4 months from September 2016 to December 2016. Diagnosis was made by physician on basis of characteristics clinical signs and symptoms. It was confirmed by using dengue IgM and IgG capture ELISA test. After Informed consent, a detailed clinical history including systemic and visual complaints was taken. Patients underwent complete ophthalmic examination including visual acuity testing, anterior segment examination by slit lamp and posterior segment examination by direct and indirect ophthalmoscope and 90D lens .

Patients with ocular findings were called for weekly follow up upto 6 weeks in ophthalmology clinic after they were discharged from the hospital.

Result

Of the 30 patients diagnosed with dengue, 25(83.3%) were males and 5(16.7%) were females [figure 1] with mean age was 32 years (20–60 years). All patients presented with fever while 28 (93.3%) patients also had myalgia. Other uncommon systemic findings were vomiting, lumbosacral pain and bleeding gums. Retrobulbar pain was present in 8 (26.7%) patients. Marked thrombocytopenia <50,000/µl was found in 26(86.7%) and all patients with thrombocytopenia <35,000/µl had ocular manifestations with maximum in range between 15,000/µl and 35,000/µl.

The mean time interval of presentation of ocular features was eighth day with range of 5–11 days. Ocular findings were present in 19 patients; of which 17 (56.7%) had subconjunctival hemorrhage [Figure 3] as the most common anterior segment finding and 4 patients had conjunctival chemosis. Subconjunctival hemorrhage was either petechial type (15 patients) or diffuse type (2 patients)

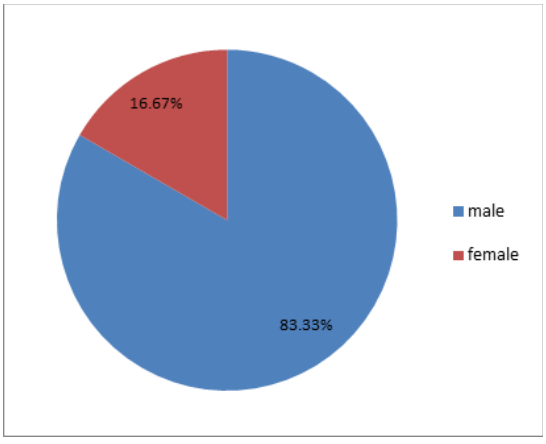

Figure 1: Gender distribution

Posterior segment findings were present in 5 patients (16.7%), of which 2 (40%) had peripheral retinal hemorrhages, 2(40%) had hard exudates and 4(80%) had macular oedema. Complete resolution of ocular findings was noticed within 6 weeks in all the 19 patients who had ocular manifestations [Figure 2].It was mainly attributed to the improving platelet count.

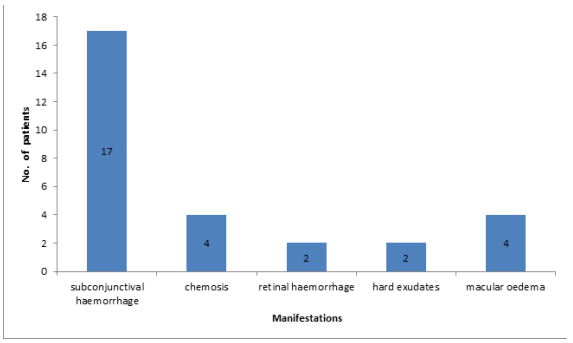

Figure 2: Ocular manifestations



Figure 3: A 31 year old male presented with petechial subconjunctival haemorrhage

Discussion

Dengue is one of the most important emerging viral diseases affecting the humans, especially in Southeast Asian countries posing a public health problem.10 It is a communicable disease transmitted by the bite of an Aedes mosquito infected with any one of the four dengue viruses (DEN-1, DEN-2, DEN-3, and DEN-4). Recovery from infection by one provides lifelong immunity against that particular serotype. Subsequent infections by other serotypes increase the risk of developing severe dengue known as dengue hemorrhagic fever1

Ocular findings are usually seen 7-8 day after onset of fever. The spectrum of ophthalmologic manifestations would lead one to conclude that several pathophysiologic processes are involved. The first and most obvious pathogenesis would be the thrombocytopenic state with its resultant bleeding tendency, which gives rise to increased incidence of hemorrhage. Another pathogenesis of DHF, involves immune clearance by way of induction of cross-reactive T-cell memory, T-cell proliferation, and recognition of dengue viral antigens on infected monocytes by sensitized cytotoxic T cells. This results in the release of cytokines with vasoactive and procoagulant properties (interleukins, tumor necrosis factor, platelet-activating factor, and urokinase)11. Vasoactive and inflammatory mediators cause capillary leakage, which may form the basis for macular edema and conjunctival chemosis while breakdown of the blood aqueous barrier result in anterior uveitis and periphlebitis.

Ocular manifestations reported to be associated with dengue infection are mostly posterior segment such as macular edema, vascular occlusion, vitreous hemorrhage, optic neuropathy, chorioretinitis, vasculitis with retinal hemorrhages, and cotton wool spots.[4,5,8,12,13]

Anterior segment manifestations has been mostly reported in the form of subconjunctival hemorrhage and anterior uveitis.[14,15] Other very rare associations are ptosis and periorbital ecchymosis and globe rupture.[3,16,17]

Our study is similar to that by Kapoor et al.[14] and Hussain et al.[3] with regard to male preponderance. The mean age group of our study is 32 years that is also similar in other studies.[3,14]

Kapoor et al studies showed prevalence of ocular findings in 40.3% of patients and 37.3% patients had anterior segment findings in form of petechial and diffuse type subconjunctival hemorrhage[14]. In our study, the prevalence was 63.3% and majority of patients 50% had petechial hemorrhage. The most common ocular manifestation in our patients was subconjunctival hemorrhage followed by retinal hemorrhages. It was similar to the studies by Kapoor et al.[14] and Hussain et al.[3]

In our study, the ocular findings were varied involving both anterior and posterior segments in contrast to study reported by Lim et al.[8] and Haritoglou et al.[18] wherein the ocular features were mainly limited to the macula.

A total of 73.3% of our patients had platelet count <50,000/µl and all our patients with ocular complications had platelet count of <35,000/µl as compared to the study reported by Kapoor et al.[14] which had 90.7% of similar association. The onset of ocular manifestations in our study correlated with the nadir of thrombocytopenia as seen in other studies.[3,9,12,17]

None of the patients in our study presented with bilateral periorbital ecchymosis or unilateral ptosis and proptosis, secondary to anterior orbital and retrobulbar hemorrhage respectively, or globe rupture as compared to other previously reported studies.[3,14]

Because there is expected increase in epidemicity of dengue fever, hence even the ophthalmic manifestations are expected to rise, so the treating physician should be aware and promptly refer any such case to the ophthalmologist as early as possible so that proper treatment can be give to prevent any vision threatening condition .

Conclusion

Dengue fever can result in varied ocular manifestations ranging from subconjunctival hemorrhage to macular oedma. Manifestations were more common in patients with decreased platelet count. Such patients are predisposed to spontaneous ocular hemorrhages and macular oedema, which can lead to impairment of vision. It is advisable for a detailed ocular examination in patients with thrombocytopenia to avoid any residual impairment of vision. Hence all patients with dengue hemorrhagic fever should be referred to an ophthalmologist to prevent any sight-threatening complications.

References

1. Teoh SCB, Chan DPL, Nah GKM, Rajagopalan R, Laude A, Ang BSP, Barkham T, et al. A re-look at ocular complications in dengue fever and dengue haemorrhagic fever. Dengue bulletin 2006; 30:184-90.
2. Yip VC, Sanjay S, Koh YT. Ophthalmic complications of dengue fever: a systematic review. Ophthalmol Ther 2012;1(1):2.
3. Hussain I, Afzal F, Shabbir A, Adil A, Zahid A, Tayyib M. Ophthalmic manifestation of dengue fever. Ophthalmology Update 2012;10:93–6.
4. Nainiwal S, Garg SP, Prakash G, Nainiwal N. Bilateral vitreous haemorrhage associated with dengue fever. Eye (Lond) 2005;19:1012-3.
5. Cruz-Villegas V, Berrocal AM, Davis JL. Bilateral choroidal effusions associated with dengue fever. Retina 2003;23:576–8.
6. Chlebicki MP, Ang B, Barkham T, Lande A. Retinal hemorrhages in 4 patients with dengue fever. Emerg Infect Dis 2005;11:770–2.
7. Siqueira RC, Vitral NP, Campos WR, Orefice F, de Moraes Figueiredo LT. Ocular manifestations in dengue fever. Ocul Immunol Inflamm 2004;12:323–7.
8. Lim WK, Mathur R, Koh A, Yeoh R, Chee SP. Ocular manifestations of dengue fever. Ophthalmology 2004;111: 2057–64.
9. Wen KH, Sheu MM, Chung CB, Wang HZ, Chen CW. The ocular fundus findings in dengue fever. Gaoxiong Yi Xue Ke Xue Za Zhi 1989;5:24–30.
10. National Vector Borne Disease Control Programme. Dengue Cases and Deaths in the Country Since 2008. Available at: http://nvbdcp.gov.in/den-cd.html (last accessed on November 4, 2012).
11. Kurane I, Ennis FA. Immunity and immunopatholgy in dengue virus infections. Semin Immunol. 1992;4:121.
12. Chan DP, Teoh SC, Tan CS, Nah GK, Rajagopalan R, Prabhakaragupta MK, et al. Ophthalmic complications of dengue. Emerg Infect Dis 2006;12:285–9.
13. Sanjay S, Wagle AM, Au Eong KG. Optic neuropathy associated with dengue fever. Eye 2008;22:722–4.
14. Kapoor HK, Bhai S, John M, Xavier J. Ocular manifestations of dengue fever in an East Indian epidemic. Can J Ophthalmol 2006;41:741–6.
15. Gupta A, Srinivasan R, Setia S, Soundravally R, Pandian DG. Uveitis following dengue

VOLUME-6 | ISSUE-3 | MARCH - 2017 • ISSN No 2277 - 8179 | IF : 4.176 | IC Value : 78.46

fever. Eye 2009;23:873–6.
16. Kumar V, Ghosh B, Raina UK, Goel N. Bilateral periorbital ecchymosis in a case with dengue fever. Indian J Ophthalmol 2009;57:242–3.
17. agaraj KB, Jayadev C, Yajmaan S, Prakash S. An unusual ocular emergency in severe dengue. Middle East Afr J Ophthalmol 2014;21(4):347–9.
18. Harioglou C, Dotse SD, Rudolph G, Stephan CM, Thurau SR, Klaub V. A tourist with dengue fever and visual loss. Lancet 2002; 360:10. 70.