ORIGINAL RESEARCH PAPER

Volume-7 | Issue-6 | June-2018 | PRINT ISSN No 2277 - 8179

INTERNATIONAL JOURNAL OF SCIENTIFIC RESEARCH

ONLAY VERSUS RETRORECTUS MESH PLACEMENT FOR REPAIR OF VENTRAL ABDOMINAL HERNIAS

General Surgery

Dr. Renu Post Graduate, Department of General Surgery, Government Medical College and Hospital, Sector-32, Chandigarh.

Dr.Rajesh Kumar Bansiwal* Associate Professor, Department of General Surgery, Government Medical College and Hospital, Sector-32, Chandigarh.*Corresponding Author

Dr. Rajeev Sharma Professor, Department of General Surgery, Government Medical College and Hospital, Sector-32, Chandigarh.

Dr. Robin Kaushik Professor, Department of General Surgery, Government Medical College and Hospital, Sector-32, Chandigarh.

Dr. Sanjay Gupta Associate Professor, Department of General Surgery, Government Medical College and Hospital, Sector-32, Chandigarh.

Dr. Kumar Abhishek Assistant Professor, Department of General Surgery, Government Medical College and Hospital, Sector-32, Chandigarh.

ABSTRACT

INTRODUCTION: Abdominal wall hernia is one of the most important subjects for all surgeons operating on abdomen. Ventral hernia is an umbrella term that includes several types of hernias occurring along the anterior abdominal wall. About 5% of the population develop a ventral hernia at some time in their life. Several techniques for the repair of ventral hernia have been described from time to time. Mesh repair has become the gold standard in the elective management of most ventral hernias. It can be categorized according to the way in which the mesh is placed as well as its relationship to the abdominal wall fascia. Each mesh location has its own risks and benefits. The ideal technique should result in low recurrence, reconstruction of a functional abdominal wall and low rate of complications.

AIMS AND OBJECTIVES: The aim of the present study is to evaluate and compare the efficacy of onlay and retrorectus mesh placement for repair of ventral abdominal hernia taking in consideration the intraoperative aspects and postoperative complications. This study is an effort to suggest the best open approach for repair of ventral hernia**.**

MATERIALS AND METHODS: This is a prospective study in which a total of 50 patients were enrolled. Patients were divided into two groups, Group A included 25 patients managed by traditional onlay mesh repair and group B included 25 patients managed by retrorectus mesh repair. Only the patients with uncomplicated midline hernia not more than 10cm were included in the study.

RESULTS: The operative time for retro-rectus repair was significantly higher than that of onlay mesh repair but the postoperative hospital stay was shorter in retro-rectus group There was no significant difference between both the groups in terms of seroma formation, Surgical site infection (SSI), mesh infection or recurrence. However, onlay repair was associated with complications like seroma formation and wound infection while incidence of complications in retrorectus repair group was nil.

CONCLUSION: This study has a shorter follow-up period of 6 months, hence late recurrences could not be recorded. Although the operative time in the retro-rectus group was higher but the reduced postoperative stay and negligible incidence of postoperative complications emphasizes on the fact that retro-rectus mesh placement is a simple and effective technique that could be adopted widely by surgeons.

KEYWORDS

Onlay, Retrorectus, Seroma, Recurrence.

INTRODUCTION

Abdominal wall hernia is one of the most important subjects for all surgeons operating on abdomen. Ventral hernia is an umbrella term that includes several types of hernias occurring along the anterior abdominal wall. Ventral hernia may include primary (umbilical, epigastric, spigelian, or lumbar hernias not related to prior incisions) or incisional (following surgery including prior primary ventral hernia repair and trauma). They are considered as a leading cause of abdominal surgery and account for 2-10% of all abdominal wall hernias.[1]

About 5% of the population develop a ventral hernia at some time in their life.2 Despite the advances in the understanding of the anatomy and physiology of the abdominal wall, the choice of suture materials and the knowledge of closure techniques, it is estimated that as many as 1 in 5 patients who undergo a laparotomy will develop an incisional hernia with maximum incidence during first 24 months after surgery.3 With the advent of laparoscopy the need for laparotomies has decreased , but incisional hernias from prior midline and transverse incisions as well as trocar and extraction sites continue to pose a risk of life-threatening bowel obstruction and ischemia. A ventral hernia may cause patient symptoms like pain or discomfort; “unsightly bulge” affecting the patient's quality of life; or it may pose a “significant” risk of bowel strangulation which explains the reason why ventral hernia should be operated.

Several techniques for the repair of ventral hernia have been described from time to time. The initial method for such repair included anatomical repair, but it was associated with a high rate of recurrence. Subsequently, newer techniques have been added, including open prosthetic mesh repair and the laparoscopic repair, which have been reported to produce better results.

Mesh repair has become the gold standard in the elective management of most ventral hernias.4 It can be categorized according to the way in which the mesh is placed as well as its relationship to the abdominal wall fascia. Mesh can be placed as an underlay deep to the fascial defect (intra-peritoneal or pre-peritoneal), as an inter-lay either bridging the gap between the defect edges or within the abdominal wall musculo-aponeurotic layers (intraparietal) as an onlay (superficial to the fascial defect) or as a retro-rectus mesh placement. Each mesh location has its own risks and benefits.

Although mesh repair is considered as the treatment of choice, the use of prosthetic material carries the risk of wound complications, recurrence and further morbidity and hence there is no consensus on the best location to place the mesh.3 A surgeon's approach is often based on tradition rather than clinical evidence. An understanding of

the structural and functional anatomy of the abdominal wall and an appreciation of the importance of restoring dynamic function are necessary for the successful reconstruction of the abdominal wall5. The ideal technique should result in low recurrence, reconstruction of a functional abdominal wall and low rate of complications.

In developing countries like ours, laparoscopic repair cannot be widely adopted due to monetary constraints on institutions as well as patient's affordability. Among the open approaches, there lies a conflict between the onlay and sublay mesh placement.1 The aim of the present study is to evaluate and compare the effiacy of onlay mesh repair and retro-rectus mesh placement for repair of ventral abdominal hernia taking in consideration the intraoperative aspects and postoperative complications. This study is an effort to suggest the best open approach for repair of ventral hernia.

MATERIALS AND METHODS

The study was conducted in the Department of General Surgery of our hospital from 2015 to 2017. Patients for the study were included from amongst those attending the surgical outpatient department of the hospital with the diagnosis of ventral hernia.

A detailed information sheet was entered for each patient which included the informed written consent, demographic details, relative history pertaining to ventral hernia, general and local physical examination, routine haematological investigations along with chest X ray and ECG. Details regarding the type of procedure performed, type of anaesthesia, mesh used, duration of surgery and hospital stay were noted down A total of 50 patients were included in the study. Patients were divided into two groups, Group A included 25 patients managed by traditional onlay mesh repair and group B included 25 patients managed by retro-rectus mesh repair. The patients were included in the study based on the following criteria.

Inclusion Criteria

All patients of either sex of age between 18 to 70 years having a midline hernia measuring 2 to 10 cm in diameter

Exclusion Criteria

Emergency surgery (incarcerated hernia)
Previous attempt at hernia surgery
Parastomal hernias
Massive ventral hernias (more than 10 cm in diameter)

After preliminary investigations, pre-anaesthetic check-up, patients were subjected to the required surgery. Randomization was achieved using sealed envelope technique. If a patient did not agree to the procedure he/she was excluded from the study.

OPERATIVE TECHNIQUES

Group A

Under general anaesthesia, after giving skin incision using blunt/sharp dissection both the rectus sheath and the defect containing the hernia contents were identified. The hernia sac was clearly dissected and the sac excised or pushed along with its contents back into the peritoneal cavity. With non-absorbable suture, the defect in the linea alba was closed and a prolene mesh of adequate size was placed with a 5 cm overlap on the rectus sheath all around the defect and fixed with sutures. Hemostasis was secured and wound closed over a negative suction drain.

Group B

In retrorectus repair after the sac was dissected, contents were reduced in the peritoneal cavity. Preperitoneal plane was then created between the posterior rectus sheath and the rectus muscle for the placement of the mesh above the umbilicus and between the rectus muscle and peritoneum below the rectus muscle. The posterior rectus sheath along with the peritoneum was closed with Polydioxanol sutures. A prolene mesh tailored to the size was placed in the already created plane behind the recti. The mesh was secured with few interrupted 2/0 polypropylene sutures through myofascial aponeurosis. The anterior rectus sheath was then closed with continuous sutures with PDS loop no.1.

All patients were given intravenous antibiotic prophylactically: intravenous single dose within one hour of induction of anesthesia was given. Postoperatively, check dressing was carried out after 48 hours. Assessment of wound infection was done at regular intervals.



Figure 1:Onlay mesh placement

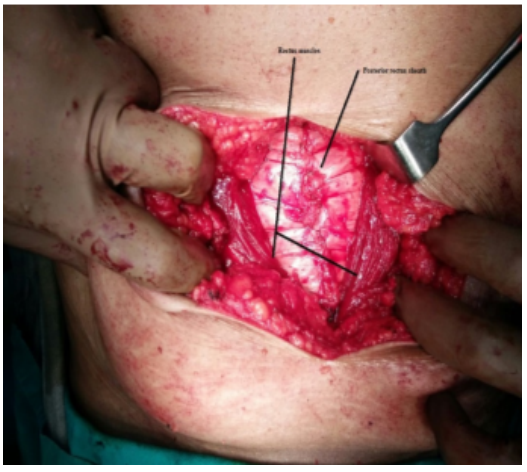

Figure 2: Posterior rectus sheath sutured in midline for mesh placement behind rectus muscle



Figure 3: Mesh placed in retro-rectus space

Postoperative follow-up:

Follow up was performed at 1week, 1 month, 3 months and 6 months

- Hospital stay was recorded
- A thorough local examination was performed to look for any seroma formation.
- Status of the wound was examined and surgical site infection was identified as per CDC guidelines.
- Patients were also examined for mesh infection
- Hernia recurrence if any was also recorded

RESULTS

AGE AND GENDER

Group A included 25 patients with age ranging from 21 to 75 years and mean age was 44.80 ± 13.58 and Group B included 25 patients with age ranging from 31 to 80 years and mean age was 54.40 ± 12.04 with p value > 0.05(table 1). Out of 25 patients in Group A who underwent traditional on-lay mesh repair there were 9 males and 16 females. Out

of 25 patients in Group B who underwent retro-rectus mesh repair there were 9 males and 16 females with p value > 0.05.(table 2)There was no statistically significant difference between both groups as regards age and gender.

Table 1: Mean Age and Sex distribution

Group	Mean ± SD	Males	Females
Group A	44.80 ± 13.58	9	16
Group B	54.40 ± 12.04	9	16

DURATION OF SURGERY

The operative time for Group A patients ranged from 40 to 120 minutes with mean of 67.4 ± 23.14 and the operative time for Group B patients ranged from 65 to 135 minutes with mean of 102.84 ± 18.70(table 3). The operative time for Group B patients was significantly higher than Group A patients with P value =0.00001 and Z score = -4.542.

Table 2: Duration of surgery

Procedure	Duration of surgery (Range in minutes)	Mean ± SD
Group A	40-120	67.4 ± 23.14.
Group B	65-135	102.84 ± 18.70.

p value = 0.00001
Z score = -4.542

DURATION OF HOSPITAL STAY

Postoperative hospital stay in Group A patients ranged from 2 to 7 days with mean of 4.12 ± 1.2 and postoperative hospital stay in Group B patients ranged from 2 to 6 days with mean of 2.88 ± 1.092(table 4). There was a significant difference between 2 groups as regards the hospital stay with p value = 0.00001 and Z score = -3.762 The postoperative hospital stay was significantly higher in Group A patients.

Table 3: Duration of hospital stay

Group	Duration of hospital stay (in days)	Mean ± SD
Group A	2-7	4.12 ± 1.2.
Group B	2-6	2.88 ± 1.092.

P value = 0.00001
Z score = -3.762

POSTOPERATIVE COMPLICATIONS

No statistically significant difference was observed between the two groups with regard to various post-operative complications at follow-up visits. Postoperative complications were nil at 24 hours in both groups. Incidence of wound infection at 1 week and 1 month was 3 patients and 2 patients respectively in Group A. In Group A, 2 patients had seroma formation at 1week, 1 month and 3 months follow-up managed by aspiration In Group A, 1 patient had seroma at 6 months follow-up. No postoperative complications were observed in Group B(table 4).

Table 4: Postoperative complications

Complications	Group A	Group B	Total
Wound infection	2(8%)	Nil	2(8%)
Seroma	3(12%)	Nil	3(12%)
Mesh infection	Nil	Nil	-
Recurrence	Nil	Nil	-

DISCUSSION

Repair of ventral hernia is an ongoing challenge for all abdominal surgeons. A wide spectrum of surgical techniques have been developed and recommended over a period of time, ranging from direct suture techniques to use of prosthetic material for strengthening the repair through open and laparoscopic approach. All of them aim to close the defect, strengthen the musculofascial tissues to avoid recurrence and provide maximum patient satisfaction. However, the optimal technique for mesh placement has not been established and remains controversial. This study is an effort to provide some insight into this area of research of pathophysiology and also to suggest an ideal method of open ventral hernia repair.

The incidence of ventral hernia especially incisional hernia is highest in 5th and 6th decades of life with female preponderance. In our study 39 out of 50 patients aged more than 40 years but there was no statistical difference between both the groups as regards age of the patients. In a study comparing various techniques of incisional hernia repair conducted at a tertiary care hospital in South India over a period of 7 years, incidence of incisional hernia was found to be more in 5th and 6th decades of life.6 In another study by Aly Saber et al comparing onlay and retrorectus repair, age of 200 patients enrolled ranged from 32 to 60 years.[7]

Both the groups were comparable in terms of sex distribution. The overall high incidence in females may be attributed to the majority of index operations being gynaecological with a lower midline incision resulting in incisional hernia. This compares favourably with our results, where 32(64%) out of 50 patients enrolled were females out of which 12(37.5%) had incisional hernia while only 5(27.7%) males out of 18 enrolled had incisional hernia. Similarly, in a prospective study by Vikram et al, incisional hernia occurred more commonly in women (n=76, 84.44 %) when compared to males (n=14, 15.55 %) and most commonly occurred after obstetric or gynaecological procedures such as lower section cesarean section, hysterectomy, or tubectomy.6 In another study by Bessa et al, out of total of 80 patients who were enrolled in the study with 40 patients in each group, there were 69 females (86.3 %) and 11 males (13.7 %).[8]

In our study the mean operative time in Group B (102.8 minutes) was significantly was significantly higher as compared to Group A (67.4 minutes). Significantly higher operative time in retrorectus repair group might be explained by more complex dissection required for creating retromuscular space for mesh placement. Elsesy et al in their study noted that the operative time for pre-peritoneal mesh repair (74 min) was more than that required for on-lay mesh repair (70 min).9 In another study by Kundan et al, the mean operative time was higher in retrorectus group(77.8 min) as compared to onlay group (69.8 min).10 In a study by Bessa et al, the operative time in the sublay group ranged from 74 to 118 min with a median of 91 min, while in the onlay group ranged from 38 to 72 min with a median of 52 min.[8]

In our study, the postoperative hospital stay was more in the onlay group(2 to 7 days)with mean of 4.12 as compared to retro-rectus repair group(2 to 6 days) with mean of 2.88. This may be attributed to no drain placement in retrorectus group allows patient to return to normal physical activities as compared to onlay repair. Ibrahim et al in a study reported, mean duration of hospital stay in the onlay group ranged from 3 to 9 (4.63 ± 0.35) days, whereas in the retrorectus group ranged from 1 to 4 (2.62 ± 0.74) days.[11]

There was no statistically significant difference between both groups in terms of seroma formation. However, the incidence of seroma formation in the onlay group was 8% at 1week, 1 month and 3 months follow up. One patient (4%) in onlay group had seroma formation even at six months. All patients were managed by serial aspirations. In retrorectus group th incidence of seroma formation was nil. Absence of seroma formation in retrorectus group is understandable owing to the absence of skin and subcutaneous flap dissection. Elsesy et al. noted seroma in 12.5% of the cases managed by on-lay mesh repair and 0% by pre-peritoneal mesh repair.6 However, Gleysteen et al found 10.7% seroma rate for on-lay and 16% for pre-peritoneal mesh repair.9 In a study by Bessa et al seroma formation was noted only in onlay group(5%).[8]

In onlay group superficial SSI was noted in 2 patients (12%) and 1(4%) patient at 1 week and 1 month respectively. The lower incidence of infection in retrorectus mesh repair may be attributed to the fact that this plane is highly vascular, hence, it prevents infection, and any infection occurring in the subcutaneous plane does not affect the mesh, as the mesh is retromuscular in a deeper plane. In a meta-analysis, fourteen of the 21 studies reported on sublay in which sublay was associated with lower risk of SSI compared to onlay, inlay, and underlay.12Gleysteen et al, in their study also found that rate of infection was higher in patients treated with on-lay mesh repair than those treated with retro-rectus mesh repair.9 Similarly in a study by Ahmed et al, wound infection in onlay group was 23% while in retrorectus group was 11%.[11]

The preperitoneal approach allows for an even distribution of forces along the surface area of the mesh. This accounts for the strength of the repair and the decreased recurrence associated with it. The repair capitalizes on the physics of Pascal's principle of hydrostatics by using the forces that create the hernia defect to hold the mesh in place. The prosthesis adheres to the posterior rectus sheath and renders it inextensible, permitting no further herniation, no dislodgement or rupture by intra-abdominal pressure but instead is held in place by the force that caused the hernia. Moreover, it is a virgin plane which makes the dissection for placement of mesh easier in case of recurrent incisional hernia.

CONCLUSION

From the present study it can be concluded that:

- Although the operative time for retro-rectus mesh placement is significantly higher than that of on-lay mesh repair but the postoperative hospital stay is significantly shorter in the retro-rectus repair group.
- The difference between both the groups in terms of postoperative complications was statistically insignificant.
- Few cases in the onlay repair group had postoperative complications like superficial SSI and seroma formation while the incidence of postoperative complications was nil in retro-rectus repair group.
- Incidence of mesh infection and recurrence was nil in both the groups

Retro-rectus mesh placement is not a new procedure. Most of the surgeons refrain from using this method as it is time consuming and are still practicing traditional on-lay repair. This study emphasizes the fact that retro-rectus mesh placement is a simple and effective technique with less postoperative hospital stay and lower incidence of complications thereby encouraging the surgeons to adopt this technique.

Thus, retro-muscular mesh repair may be a good alternative to traditional on-lay mesh repairs. However, large multicentre randomized trials are needed to substantiate this fact as the present study had a small sample size and limited follow-up period due to which late recurrences could not be taken into account.

REFERENCES

1. Stumpf M, Conze J, Klinge U, Rosch R, Schumpelick V. Open mesh repair. Eur Surg 2005; 35: 21–24
2. Bikhchandani J, Fitzgibbons R. Repair of Giant Ventral Hernias. Advances in Surgery 2013; 47: 1-27
3. Luijendijk RW, Hop WC, Vanden TMP, De Lange DCD, Braaksma MMJ, Ijzermans JNM, et al. A comparison of suture repair with mesh repair of incisional hernia. N Engl J Med 2000; 343: 392-8
4. Chichom MA, Guifo ML. Don't be scared: Insert a mesh! Pan Afr Med J 2011; 10: 1-18
5. Shell DH, de la Torre J, Andrades P, Vasconez LO. Open repair of ventral incisional hernias. Surg Clin North Am 2008; 88: 61-83
6. Vikram K, Gabriel R, Chandni R, Sampath K. A Comparative Analysis on Various Techniques of Incisional Hernia Repair–Experience from a Tertiary Care Teaching Hospital in South India. Indian J Surg 2013; 75: 271-73
7. Aly S, Emad K, Bayumi. Onlay Versus Sublay Mesh Repair for Ventral Hernia. J Surg. 2015; 4: 1-4
8. Bessa SS, Elgendi AM , Ghazal AHA , Alfayoumi TH. Comparison between the short-term results of onlay and sublay mesh placement in the management of uncomplicated paraumbilical hernia: a prospective randomized study. Hernia 2015; 19: 141-6
9. Elsesy A, Balbaa MA, Badr MLA, Latif MA. Retormascular Preperitoneal Versus Traditional Onlay Mesh Repair In Treatment Of Incisional Hernias. Menoufiya Med J 2008 ; 21: 209-20
10. Kundan K, Bharat BD, Sunil P, Karan VS, Srihari S, Sai K. A comparative study of onlay and retrorectus mesh placement in incisional hernia repair. Med J DY Patil Univ 2013; 3: 202-5
11. Ahmed H I, Ahmed S, Mostafa M. Comparative study between onlay and sublay hernioplasty in the treatment of uncomplicated ventral hernia. Menoufia Med J 2015; 28: 11–16
12. Holihan JL, Nguyen DH, Nguye MT, Mo J, Kaol LS, Liang MK. Mesh Location in Open Ventral Hernia Repair: A Systematic Review and Network Meta-analysis. World J Surg 2015; 40: 3252-9