Volume : 2 | Issue : 11 | November 2013 • ISSN No 2277 - 8179

Research Paper

Medical Science

KEYWORDS : situs inversus, cholelithiasis, common bile duct

Open Cholecystectomy and Common Bile Duct Exploration in Situs Inversus

Dr. Pallav Agrawal	Senior Resident, Department of Surgery, S. N. Medical College, Agra
Dr. Rajesh Gupta	Associate Professor, Department of Surgery, S. N. Medical College, Agra
Dr. Anoop Singh	Junior Resident, Department Of Surgery, S. N. Medical College, Agra
Dr. Utkarsh Srivastava	Junior Resident, Department Of Surgery, S. N. Medical College, Agra
Dr. Vibhu Shankar Parashar	Junior Resident, Department Of Surgery, S. N. Medical College, Agra

ABSTRACT

Situs inversus is a condition in which the heart is on the right side of the midline. It is also termed as the mirror image dextrocardia. The liver and the gall bladder are on the left side. The patients are usually asymptomatic. There is no racial predilection and both sexes are equally affected. The recognition of situs inversus is important for preventing surgical mishaps that result from the failure to recognize the reversed anatomy. Mostly it is detected due to cholelithiasis or appendicitis.

INTRODUCTION

Situs inversus totalis is a rare congenital disorder occurring in 0.01% of the population. It is characterized by the transposition of the major thoracic organs and all the visceral organs of the abdomen to the side opposite to normal position in the body. The liver and gall bladder are located on the left, while the stomach and the spleen are on the right. The normal development requires a 270 degree counterclockwise rotation that yields the normal anatomy. In situs inversus totalis, the 270 degree rotation is in the clockwise direction. The exact etiology is unclear; however, it is thought to be due to a single autosomal recessive gene of incomplete penetration. The male to female ratio is 1:1 and there is no racial predilection.

CASE PRESENTATION

A 70-year-old woman had occasionally dyspepsia, discomfort and some pain in the left upper quadrant for the last 6 months. She was admitted in our department due to aggravation of pain for the last 5 days. On physical examination tenderness in left hypochondrium and adjoining epigastrium and aching pain radiating to the left upper quadrant were reported . General physical examination was normal. Cardiovascular examination revealed the apex beat in the right 5th intercostal space with mild tachycardia. The hematological and biochemical parameters were normal except mild elevated serum bilirubin. Chest x-ray revealed dextrocardia.

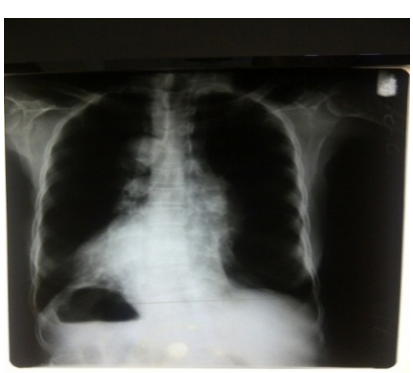

Figure 1

ECG showed transposition of lead 1st and 2nd and inversion of lead 1st. Ultrasound examination revealed liver and gall bladder on the left side and spleen and stomach on the right of the abdomen and presence of multiple stones in gall bladder and in CBD.



Figure 2



Figure 3

Patient underwent elective open cholecystectomy and CBD exploration through an upper midline incision

DISCUSSION

Situs inversus totalis(SIT) is a rare congenital disorder, found in 1:5000-20000 of the population[1] . This anomaly may involve thoracic organs or abdominal viscera (situs inversus partialis) or both (situs inversus totalis)[2]. No racial or gender predilection is presented. The patients have a normal lifetime unless cardiac defects are severe. The extrahepatic biliary, venous or arterial anomalies are the same as those in normal population. SIT can be easily diagnosed after chest x-ray, electrocardiogram, abdominal US, computerized tomography or barium swallow [3]. We noticed SIT after CXR and abdominal US in our case. The pain was in left upper quadrant and radiating to the left shoulder. It is important to be aware of the presence of the pain in unusual place (4). The pain in the right side is also possible in 10% of patients.Laparoscopic

cholecystectomy and CBD exploration has become the gold standard for treating symptomatic cholelithiasis and cholidochotomy and should be the procedure of choice wherever the expertise is available. In this case we performed open cholecystectomy and CBD exploration through upper midline approach because surgeons are right-handed, and to operate laparoscopically in a "mirror image" anatomical situation using mainly the left hand for dissection may be stressful, uncomfortable and more time-consuming [5]. Some recommendations to overcome this issue have been published: changing right and left hand for dissection, crossing laparoscopic tools to dissect in Calot's triangle with the right hand from the port in the left subcostal, or just performing dissection by the right hand from the epigastric port while the first assistant grasps the fundus and performs retraction of Hartmann's pouch to allow the surgeon to work in a more ergonomic position [5].

CONCLUSION

A high degree of suspicion combined with a thorough clinical examination should be maintained by an experienced surgeon while evaluating a patient with left upper abdominal pain. An open cholecystectomy should be performed when there is limited access to laparoscopic surgery

REFERENCE

1-Demetriades H, Botsios D, Dervenis C, et al. Laparoscopic cholecystectomy in two patients with symptomatic cholelithiasis and situs inversus totalis. Dig Surg. 1999;16(6):519-21. | 2-T. Z. Nursal, A. Baykal, D. Iret, and O. Aran, "Laparoscopic cholecystectomy in a patient withsitus inversus totalis," Journal of Laparoendoscopic & Advanced Surgical Techniques, vol. 11, no. 4, pp. 239–241, 2001 | 3- Pathak KA, Khanna R, Khanna NN. Situs inversus with cholelithiasis. J postgrad Med. 1995 Apr-Jun;41(2):45-6. | 4-Heimann T, Sicular A. Acute cholecystitis with situs inversus. N Y state J Med.1979 Feb;79(2):253-4. | 5-Puglisi F, Troilo VL, De Fazio M, et al. Cholecystectomy in situs viscerum inversus totalis. Does laparoscopy increase the pitalls? Chir Ital. 2006 Mar-Apr;58(2):179-83.