ORIGINAL RESEARCH PAPER

Volume-8 | Issue-1 | January-2019 | PRINT ISSN No 2277 - 8179

INTERNATIONAL JOURNAL OF SCIENTIFIC RESEARCH

ORAL CANCER RECONSTRUCTION BY PECTORALIS MAJOR MYOCUTANEOUS FLAP : A RETROSPECTIVE STUDY OF 25 CASES

Oncology

Manish Kumar Assistant Professor , Department Of Surgical Oncology , Igims , Patna .

Sanjeet Kumar Associate Professor , Department Of Pathology , Igims , Patna .

Vibhuti Bhushan Additional Professor , Department Of General Surgery , Igims , Patna .

Yogesh Kumar Yashaswi* Senior Resident , Department Of General Surgery , Igims , Patna, *Corresponding Author

ABSTRACT

INTRODUCTION : Oral cancer is one of the common cancer in our part. Usually the patients present in late stage due to lack of awareness, tobacco addiction, poor health care facility and social stigma. Now a day for reconstruction free flaps are ideal but due to its limited expertise and resources still Pectoralis Major Myocutaneous Flap (PMMC flap) is the most common mode of reconstruction.

MATERIAL & METHODS : We retrospectively analysed 25 cases (M:F=22:3) , age group 20-80 years of oral cancer who were reconstructed with PMCC flap at Department Of Surgical Oncology , Indira Gandhi Institute Of Medical Sciences, Patna from March 2017 to February 2018.

RESULT: All patients underwent composite resection with neck dissection with PMCC flap reconstruction for buccal mucosa defect. Flap necrosis was seen in 4 cases. There was no total loss of flap and 1 had major partial necrosis required surgical intervention and prolong hospital stay. 3 had minor flap necrosis who were managed conservatively without prolong hospital stay. Other complications were fistula formation , wound dehiscence, hematoma and infections. Chyle leak was present in 1patient.

CONCLUSION: PMMC flap is the most common reconstructive procedure for oral cancer surgery in our part because of its versatility and limited resources.

KEYWORDS

Oral cancer, Reconstruction, Pectoralis major myocutaneous (PMMC) flap

INTRODUCTION :

Oral cancer is one of the common cancer in our part . Usually the patients present in late stage due to lack of awareness, tobacco addiction, poor health care facility and social stigma. Now a day for reconstruction free flaps are ideal but due to its limited expertise and resources(1) still Pectoralis major myocutaneous flap (PMMC flap) is the most common mode of reconstruction (4). It was first described by Ariyan in 1979 with complication rate of 17-63% has got unmatched acceptance in oral reconstruction. At IGIMS , Patna oral malignancy constitute major load of cancer in surgical oncology department in adult population with most patients presenting in advanced stages. PMMC flap is the principal mode of reconstruction following surgery. It provides acceptable bulk for the defect and good cosmetic and functional outcome.

MATERIAL AND METHODS :

We retrospectively analysed 25 cases (M:F=22:3) , age group 20-80 years of oral cancer who were reconstructed with PMCC flap at Surgical Oncology department ,Indira Gandhi Institue Of Medical Sciences (IGIMS),Patna from March 2017 to July 2018 with regard to clinical presentation, tumor stage (TNM), operative procedure and post-operative complications. Ipsilateral PMCC flap was used for reconstruction.

SURGICAL TECHNIQUE FOR PMCC FLAP (10) :

Vascular pedicle of PMMC flap was marked by drawing a line from the ipsilateral acromian to the xiphisternum and another line vertically from the mid point of clavicle to intersect the first line. Skin paddle of the flap was taken over the pectoralis major muscle along the course of the pectoral branch of the thoracoacromial artery.Care was taken not to undercut the skin paddle during flap elevation, to include the myocutaneous perforators. The skin paddle was sutured to the underlying pectoralis muscle with a few sutures to protect the myocutaneous perforators from shearing injury. dissection was started from the lateral border of the pectoralis major muscle and the plane between the pectoralis minor and pectoralis major muscle with its vascular pedicle was found.The pectoralis major muscle was divided lateral to the pedicle while keeping the pedicle in view. Subcutaneous tunnel was created superficial to the clavicle to pass the flap into the neck which was omodate the flap without any compression. Suturing of the flap was done with 2–0 vicryl interrupted sutures. Suction drains were placed in the neck and chest, and the wounds were closed in layers. The donor site was closed primarily(10).

OBSERVATION AND RESULTS :

Total 25 patients (M:F= 22:3) of oral cancer with age group 20-80 years (mean : 49.76 years) were retrospectively reviewed. Maximum incidence was found in 3rd decade (28%), followed by 4th decade (24%) and 20% each in 5th and 6th decade.

Youngest was of age 27 yrs and oldest was 75 yrs. Twenty one (21) have history of tobacco addiction and only four (4) were non addict. Squamous cell carcinoma was the histopathological tissue diagnosis. Most common site was retromandibular region (12 cases).

Reconstruction was done with Pectoralis major myocutaneous flap for mucosal defect.



Primary oral carcinoma



Primary oral cancer



Markings for PMMCflap

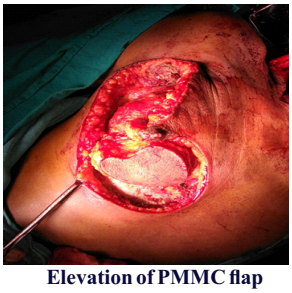

Elevation of PMMC flap

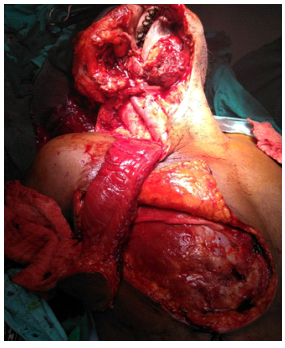

PMMC flap pssed through tunnel

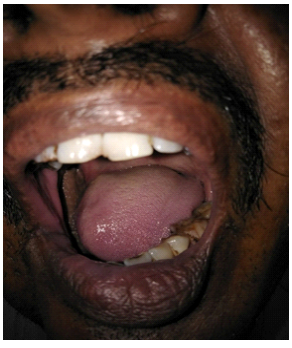

3 months after surgery

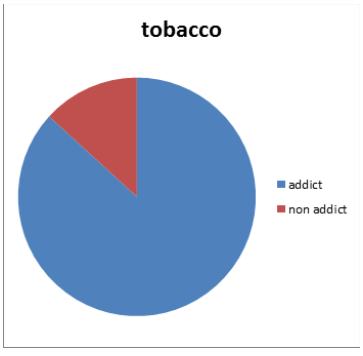

addict	21
Non-addict	4

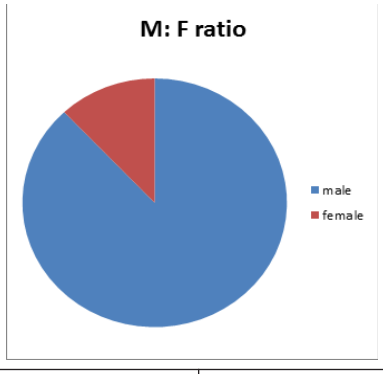

male	22
female	3

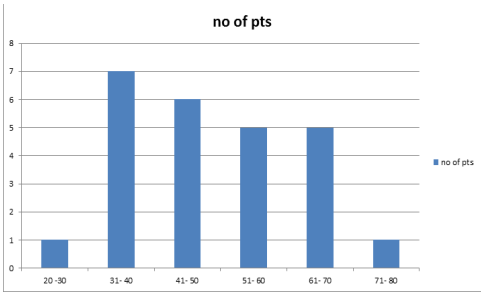

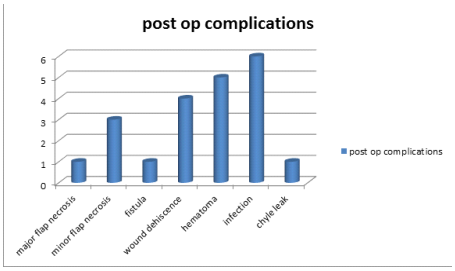

POST OF COMPLICATIONS :

Flap necrosis was observed in 4 pts of which 1 had major partial flap necrosis and 3 has minor partial flap necrosis. Full thickness partial loss which prolonged hospital stay or required surgical intervention were defined as major partial loss and which did not significantly delayed the hospital discharge or required surgical intervention was called minor flap loss. Major flap necrosis was managed with surgical debridement followed by secondary suturing. Patients who had minor flap necrosis were managed conservatively without any surgical intervention. There as no case of total flap necrosis. The patient who had flap necrosis also developed orocutaneous fistula which later on required secondary suturing after debridement. site for fistula formation was at the junction between the flap, mucosa of the floor of mouth. T4 primary disease with major resection is one of the factor contributing to fistula formation.

Suture line dehiscence developed in 4 patients. They were managed conservatively. Common factors associated with wound dehiscence were presence of systemic disease like diabetes mellitus, female gender, old age, and resection of mandible. Wound hematoma of various degreees was recorded in 5 patients. All these 5 patients had undergone mandibular resection with neck dissection. 7 patients developed surgical site infection including superficial and deep surgical site infection. One patient developed complication unrelated to flap. The complication was chyle leak which occurred in patient who has undergone lt neck dissection.

DISCUSSION :

Nowadays with advancement in microvascular surgical techniques the ideal method for oral reconstruction is free flap either as free radial forearm flap, or free fibula osteomyocutaneous flap, or free antero-lateral thigh flap because of better cosmetic and functional outcomes(7). But in centers with high volume of patients and limited resources PMMC flap remains the important flap for reconstruction in oral cancers. Advantage of PMMC flap reconstruction is that it has shorter learning curve and a single team can do the surgery for primary lesion and reconstruction therefore it obviates the need of two teams to work together always(11). PMMC flap has got the importance in primary reconstruction but it is also used as a salvage procedure after free flap necrosis and also in conditions in which free flap is contraindicated due to some medical conditions. PMMC flap is sometimes used along with free flap in cases where large soft tissue defect coverage overlying a major vessel and in patients which have high risk of wound dehiscence(7,8).

In literatures on PMMC flap reconstruction the complications varies from 17% to 63%(3,6,7,9).in our series, we observed a complication rate of 20% with 4% incidence of flap necrosis. There was no incidence of total flap necrosis. Our results are in line with those in literatures(5,7,9). PMMC flap is a very robust flap and its major advantage is its survival capacity(8). This statement does not hold true for free flap reconstruction where even in the hands of an experienced microsurgeon total flap necrosis occurs.

Few factors have been identified which are associated with the occurrence of flap necrosis like use of scalpel versus cautery, preservation versus removal of the clavicular portion of pectoralis major muscle attachment and the presence of random potion of skin at the distal end of the flap, but their exact significance still remain elusive(5,7,9).

In our series one patient had total partial flap necrosis. In this patient the skin paddle was extended beyond the 7th rib as e needed relatively large size of flap for coverage. Rikimaru et al, pointed out that positioning the skin island just medial to nipple, over 4th , 5th , and 6th intercostals spaces, is necessary for including the skin perforator

vessels which arise from the intercostals branches of the internal thoracic artery. Hen blood flow through the internal thoracic artery is interrupted during PMMC flap elevation, these cutaneous vessels are supplied by the pectoralis branch of thoracoacromial artery. So when we respect the the anatomical condition, a totally axial myocutaneous flap is created. The vascular supply of the skin below 7th rib comes from the cutaneous branches of the superficial epigastric artery. So when the portion of skin beyond this limit is included in the flap, then the distal portion of skin is not an axial flap but is a random pattern flap increasing the risk of partial loss.

Cunha-Goms et al, observed that lateral pectoral nerve may lie parallel or oblique to the PMMC flap vascular pedicle. When the flap is rotated through 180 degrees, the lateral pectoral nerve presses against the vascular pedicle, then leading to PMMCflap vascular impairment. These authors observed this anatomical variation in 30% of their cases and recommended the dissection and division of the lateral pectoral nerve hen the above situation is observed. In ours series, we routinely divided the lateral pectoral nerve before the flap is rotated so that the chances of flap necrosis becomes less.

In our series hematoma developed in 2 patients. In one patient surgical exploration was required. We must do proper hemostasis, especially to the cut edges of the pectoralis major muscle paddle. During reexploration, the vascular pedicle must be identified and preserved and should be handled with proper care, otherwise chances of flap necrosis will increase. Oro cutaneous fistula occurred in 1 patient with some degree of flap necrosis. Special attention must be taken care for the tripointer suture in the anterior region between the flap, mucosa of the floor of the mouth, and mucoperiosteum of the cut edges of the mandible. The other point to be taken care of is the intraoral portion of the PMMC flap, which remains in the contaminated environment of saliva and food debris and this area is not easily accessible to patients for mechanical cleaning. Proper maintenance of oral hygiene is very important for flap survival otherwise infection will do more harm to flap. Infection is a major concern in PMMC flap reconstruction. The best way to prevent it is to maintain strict asepsis.

In our study, with overall complication rate of 20%, which is comparable to others studies(2,7) . PMMC flap is a good choice in centers with limited resources and as salvage procedure.

CONCLUSION :

PMMC flap is still one of the most favored approaches for oral reconstruction owing to its versatility, easy learning curve and a constant vascular pedicle with acceptable cosmetic and functional outcome. Our experience in 25 cases has shown a low flap related complications with major flap necrosis in 1 patient and minor partial flap necrosis in 3 patients. PMMC flap is still a workhorse for oral reconstruction in institutes and centers with limited resources with heavy patient load.

REFERENCES

1. Blackwell KE, Buchbinder D, Biller HF, Urken ML. Reconstruction of massive defects in the head and neck: The role of simultaneous distant and regional flaps. Head Neck 1997;19:620-8.
2. Ariyan S. The pectoralis major myocutaneous flap. A versatile flap for reconstruction in the head and neck. Plast Reconstr Surg 1979;63:73-81.
3. Croce A, Moretti A, D'Agostino L, Neri G. Continuing validity of pectoralis major muscle flap 25 years after its first application. Acta Otorhinolaryngol Ital 2003;23:297-304.
4. McCrory AL, Magnuson JS. Free tissue transfer versus pedicled flap in head and neck reconstruction. Laryngoscope 2002;112:2161-5.
5. Milenovic A, Virag M, Uglesic V, Aljinovic-Ratkovic N. The pectoralis major flap in head and neck reconstruction:First 500 patients. J Craniomaxillofac Surg 2006;34:340-3.
6 Liu R, Gullane P, Brown D, Irish J. Pectoralis major myocutaneous pedicled flap in head and neck reconstruction: Retrospective review of indications and results in 244 consecutive cases at the Toronto General Hospital. J Otolaryngol 2001;30:34-40.
7. Vartanian JG, Carvalho AL, Carvalho SM, Mizobe L, Magrin J, Kowalski LP. Pectoralis major and other myofascial/myocutaneous flaps in head and neck cancer reconstruction: Experience with 437 cases at a single institution. Head Neck 2004;26:1018-23.
8. McLean JN, Carlson GW, Losken A. The pectoralis major myocutaneous flap revisited: A reliable technique for head and neck reconstruction. Ann Plast Surg 2010;64:570-3.
9. Liu R, Gullane P, Brown D, Irish J. Pectoralis major myocutaneous pedicled flap in head and neck reconstruction: Retrospective review of indications and results in 244 consecutive cases at the Toronto General Hospital. J Otolaryngol 2001;30:34-40.
10. Freeman JL, Walker EP, Wilson JS, Shaw HJ. The vascular anatomy of the pectoralis major myocutaneous flap. Br J Plast Surg 1981;34:3-10.
11. Talesnik A, Markowitz B, Calcaterra T, Ahn C, Shaw W. Cost and outcome of osteocutaneous free-tissue transfer versus pedicled soft-tissue reconstruction for composite mandibular defects. Plast Reconstr Surg 1996;97:1167-78. .