CASE REPORT

Volume-8 | Issue-1 | January-2019 | PRINT ISSN No 2277 - 8179

INTERNATIONAL JOURNAL OF SCIENTIFIC RESEARCH

ORAL MYIASIS: CASE REPORT AND LITERATURE REVIEW OF AN UNUSUAL DISEASE ENTITY

Oral Medicine

Dr Sudhaa Mani M*	MDS Professor, Department of Oral medicine and Radiology, Vivekanandha dental college for women, Tiruchengode, Namakkal district, Tamilnadu, India *Corresponding Author
Dr Chitra Mohan	Post Graduate Student, Department of Oral medicine and Radiology, Vivekanandha dental college for women, Tiruchengode, Namakkal district, Tamilnadu, India
Dr Yasmeen Ahamed	MDS READER, Department of Oral medicine and Radiology, Vivekanandha dental college for women, Tiruchengode, Namakkal district, Tamilnadu, India
Dr Sivaraman G	MDS Senior Lecturer, Department of Oral medicine and Radiology, Vivekanandha dental college for women, Tiruchengode, Namakkal district, Tamilnadu, India
Dr N Balan	Professor and Head, Department of Oral medicine and Radiology, Vivekanandha dental college for women, Tiruchengode, Namakkal district, Tamilnadu, India
Dr Ambiga Pazhani	MDS Senior Lecturer, Department of Oral medicine and Radiology Vivekanandha dental college for women, Tiruchengode, Namakkal district, Tamilnadu, India

ABSTRACT

Oral Myiasis is an uncommon disease which is caused by the invasion of uncovered body areas in humans by maggots or larvae of certain Dipteran flies. It commonly occurs in under developed and developing countries where the socio economic status is low and among people with poor oral hygiene measures. The presence of larvae confirms the diagnosis of the disease. Basic knowledge about the disease and proper maintenance of hygiene can prevent the disease to certain extent. The Dental Surgeons play a crucial role in treating the disease to destroy the larva. This case report depicts the presentation of a 15 year old young boy with Oral Myiasis in the maxillary anterior region. The removal of the larvae was done manually after topical application of turpentine oil along with surgical debridement and administration of antibiotics.

KEYWORDS

Oral myiasis, Maggots, Larva, Muscidae, Diptera, Hygiene

INTRODUCTION

Oral Myiasis was defined by Zumpt in 1965 as “infestation of live human and vertebrate animals with dipterous larvae which feed on the host's dead or living tissue, liquid body substances, or ingested food”. [1] This is mainly caused by the aggression of the eggs or larvae of parasites from the Dipterian family in living mammalian or vertebrate tissues. [2]

It was derived from a Greek word “Mya” which means “fly” and the word Myiasis was first coined by F. W. Hope in 1840. The first description about Myiasis was given by Laurence in 1909.[3, 4] The incidence of Myiasis is common in third world countries like tropical and subtropical zones of Africa and Asian countries , rural areas, infecting livestock, etc., and oral myiasis is being commonly reported in psychiatric patients, those with poor oral hygiene, drug addicts and in chronic suppurative lesions involving the oral cavity. [5, 6] In 1947 James emphasized that the etiology for myiasis was Diptera order flies commonly from the genus Sacrophaga and Chrysomya. [7]

CASE REPORT

A 15 year old young male patient reported to the Department of Oral Medicine and Radiology and his mother accompanied him. His mother reported that the chief complaint was larvae coming out from the mouth since 10 days and also associated with swelling in the front region of the upper jaw since 4 months. The medical history revealed that the patient was affected with cerebral palsy since birth and he has been bed ridden since then. On general examination, gross motor activity was absent and the head was extended back. The scissoring of legs and thinning of the muscles of the hands could be seen. (FIGURE 1) On extra oral examination, there was a diffuse swelling in the anterior maxillary mid facial region with incompetent lips and obliteration of the nasolabial folds. (FIGURE 2)

On intra oral examination, halitosis was present with poor oral hygiene. There was a solitary, erythematous dome shaped diffuse swelling on the anterior hard palate region crossing the midline in relation to 11, 12, 21, 22 region. On palpation it was tender, soft in consistency and fluctuant. (FIGURE3) On examination of the gingiva, there was detachment of the labial aspect of the attached gingiva in relation to 11, 21, 22, 23 teeth region from the underlying bone associated with bleeding on probing. Mobility was present in relation to 11, 12, 21 and 22. On close observation, multiple larvae were seen moving within the detached gingival segment on the labial aspect in relation to 11, 21, 22, 23 region. (FIGURE 4) Hence based on the history, clinical examination and presence of maggots, the provisional diagnosis was given as Oral Myiasis.

Radiological investigation was done. Standard maxillary occlusal radiograph revealed generalized horizontal bone loss. (FIGURE 5) Hematological investigations were within the normal limits. The patient was admitted to our general surgery department. Management was first done by flushing the area with normal saline and that was ineffective in our case. Then the lesion was treated by impregnating cotton rolls with turpentine oil followed by its topical application over the affected area for about 10-15 minutes. Dozens of maggots whirled out from the lesion site and about 10-20 larvae, grayish white in color with transverse rows of segments were removed manually using tissue holding forceps. (Figure 6) This was done for about two days and then followed by surgical debridement of the area with saline. The viable larvae were identified as that of the common house fly. Iodoform pack was also given. Administration of intravenous infusion of Augmentin 375mg was given twice daily for three days. On follow up, the wound healing was satisfactory. The parents were instructed to maintain proper oral hygiene.

DISCUSSION

Myiasis is an unusual disease entity which occurs mainly in people with low socio economic status and those in warm tropical regions. The patient in our case was of low socio economic status with persistent mouth opening due to incompetent lips and poor oral hygiene. Based on the sites involved, they can be further classified into cutaneous, nasopharyngeal, intestinal, oral and urogenital myiasis. [3] Clinically, myiasis can be classified into either Primary (which feed on living tissues) or Secondary (which feed on dead tissues).[8] Oral myiasis was first reported by Scott in 1964. [9]

The most commonly reported genera are Sacrophagidae and Muscidae flies from the Order Diptera.[10] The eggs are laid by these flies which hatch in less than a week. Once the larvae are formed they get attached to the underlying tissues with the help of segmental hooks. Since they are photophobic, they move to deeper tissues and complete the life cycle by 7-8 days.[3,10] Once they start burrowing into the deeper tissues, there will be separation of the mucoperiosteum from the underlying tissue which was present in our case too. Bacterial organisms which are present in the affected area produce proteolytic enzymes and the larvae feed in this enzymatic environment thereby increasing the infection of the affected site and leading to halitosis.[11]

Local and systemic measures are undertaken to manage this disease condition. Local measures include topical application of turpentine oil, mineral oil, chloroform, ethyl chloride or mercuric chloride after which the maggots are removed manually.[12] Topical application of such asphyxiation agents would create an anaerobic environment which helps in expulsing the maggots out from the deeper tissues.[3] While removing manually, the rupture of the larva should be avoided.[13] Systemic measures include administration of broad spectrum antibiotics like augmentin, metronidazole etc. Another systemic medication being administered is Ivermectin, a semi synthetic macrolide antibiotic, 150- 200 mg/Kg body weight given orally and is found to be effective and safe in the management of Oral myiasis.[7]

CONCLUSION:

Oral Myiasis is a rare disease which should be prevented at an early stage in individuals with debilitating conditions. Maintaining proper hygiene and sanitation can halt the worsening of the condition. An oral physician should have a thorough knowledge about this disease and its management so that education of the common people can be done to maintain proper oral hygiene and cleanliness thereby preventing the occurrence of this disease.

FIGURE 1: General features of the patient



FIGURE 2: PROFILE PICTURE OF THE PATIENT



FIGURE 3: Swelling of the Anterior Hard Palate Region



FIGURE 4: Photograph showing maggots within the detached gingiva in relation to 11, 21, and 22, 23 teeth region



FIGURE 5: Maxillary occlusal radiograph showing generalized bone loss

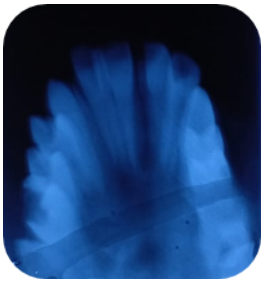

FIGURE 6: LARVA REMOVED FROM THE SITE



REFERENCES

1. Zumpt F. Myiasis in man and animals in the Old world. London: Butterworth. 1965;267.
2. Francesconi F, Lupi O. Myiasis. Clin Microbiol Rev. 2012;25(1):79–105.
3. Koteswara Rao B Oral Myiasis - A Case Report. Ann Essences Dent. 2010 Sep 14;2(4):204–7.
4. Rossi-Schneider T, Cherubini K, Yurgel LS, Salum F, Figueiredo MA. Oral myiasis: A case report. 2007;49:85–8.
5. Baskaran M, Kumar BJ, Geeverghese A. Cutaneous myiasis of face. J Oral Maxillofac Pathol. 2007;11(2):70.
6. Droma EB, Wilamowski A, Schnur H, Yarom N, Scheuer E, Schwartz E. Oral myiasis: a case report and literature review. Oral Surg Oral Med Oral Pathol Oral Radiol Endodontology. 2007 Jan;103(1):92–6.
7. Jain et al. Management of Oral Myiasis. International Journal of current research. 2017;9(3):48530–1.
8. Jimson S, Prakash C, Balachandran C, Raman M. Oral Myiasis: Case report. Indian J Dent Res. 2013;24(6):750.
9. Rodolfo R. Felice, Kalu U.E. Ogbureke Oral Myiasis: Report of Case and Review of Management. J Oral Maxillofac Surg. 1996;54:219–20.
10. Ramli R, Rahman RA. Oral myiasis: Case report. Malays J Med Sci MJMS. 2002;9(2):47.
11. Gupta M, Singh S, Bhagawati B. Oral myiasis: A rare entity. Eur J Gen Dent. 2013;2(3):312.
12. Sankari L, Ramakrishnan K. Oral myiasis caused by Chrysomya bezziana. J Oral Maxillofac Pathol. 2010;14(1):16.
13. Trevielle Periera et al. Oral Myiasis. Contemp clin dent. 2010 Dec;1(4):275–6.