ORIGINAL RESEARCH PAPER
VOLUME-6 | ISSUE-7 | JULY-2017 | ISSN No 2277 - 8179 | IF : 4.176 | IC Value : 78.46
INTERNATIONAL JOURNAL OF SCIENTIFIC RESEARCH

OUTCOME OF ANAPLASTIC OLIGODENDROGLIOMA OF BRAIN-A TERTIARY CENTER EXPERIENCE.

Oncology

Dr.Arunkumar.M.N Assistant professor, Department of Radiation oncology, Cancer Institute (WIA), Adyar, Chennai-20.

Dr.Harishkumar.K Assistant professor, Department of Radiation oncology, Cancer Institute (WIA), Adyar, Chennai-20.

Dr.Selvaluxmy.G Professor/HOD, Department of Radiation oncology, Cancer Institute (WIA), Adyar, Chennai-20.

ABSTRACT

Background
Anaplastic Oligodendroglioma (AO) is a rare malignant tumor which comprises only 0.5 to 1.2% of all primary brain tumors. We analyzed retrospectively demography, treatment and survival outcome of AO patient treated our institute from 2000 to 2015.

Methods
All patients underwent maximal safe surgical resection followed by adjuvant radiation with or without chemotherapy.48% of patients underwent gross total resection and 52% of patients had subtotal resection. Most of the patient (80%) had adjuvant chemoradiation and others had only adjuvant radiation. Prognostic factors were evaluated by univariate analysis.

Result
The 5-year PFS and OS rate of all patients was 50% and 75%.In univariate analysis 5-PFS for patient treated with adjuvant chemo radiation 54.5% and adjuvant radiation was 40% and 5-year OS rate respectively was 81.1% and 60%

Conclusion
The use of adjuvant chemo radiation in Anaplstic Oligodendroglioma after maximal safe surgical resection show good progression free survival and overall survival. Age, sex, site tumor, and extent of the resection also as a factor of prognostic importance, but not statistically significant.

KEYWORDS:

Oligodendroglioma, Anaplastic, chemoradiation, progression free survival

INTRODUCTION

Anapastic Oligodendroglioma is a rare malignant tumour. It is consistent with features of Oligodendroglial linage and histological features corresponding to World Health Organization (WHO) grade 3.(1) The current WHO definition of Anaplastic Oligodendroglioma tumor characterised by focal or diffuse histological features of malignancy and a less favourable prognosis. Only 30% of Oligodendroglial tumours have Anaplastic characteristics (such as high cell density ,mitosis ,nuclear atypical ,microvascular proliferation , and necrosis).The reported annual incidence rates of Anaplstic Oligodendroglioma ranges from 0.07 to 0.18 per 100,000 person –years and comprise only 0.5% to 1.2% of all primary brain tumours .(2,3) Males are more commonly affected with male to female ratio 2:1.No definite inheritance pattern seen, however occasional familial grouping of Oligodendroglioma have been reported. (4) Anaplastic Oligodendroglioma primarily occurs in adults ranging from 45 to 50 years and also occurs in younger age group. Reported median overall survival 5.2 years.

Optimal treatment of Anaplstic Oligodendroglioma is evolving nowadays though adjuvant radiation to adjuvant chemoradiation.We are here to discuss demography,treatment,survival outcome of 25 patients Of Anaplastic Oligodendroglioma treated our institute from 2000 to 2015.

METHODS

This is a retrospective study performed with 25 patients who had maximal safe surgical resection followed by adjuvant radiotherapy with or without chemotherapy for Anaplastic Oligodendroglioma of brain. Patients were treated at Cancer Institute, Adyar, Chennai between 2000 and 2015.

Fourteen patients (56%) were male and eleven (44%) were female. The median age was 36 years (23 -74years). Most common presenting symptom was seizure (48%) followed by headache (44%) and motor deficits (8%).All patients underwent initial examination before start of treatment includes physical examination , blood count, biochemical examination ,chest skiagram, electrocardiogram and magnetic resonance imaging of the brain.

Frontal location was most common site (68%) followed by temporal (20%) and parital (12%).Twelve patients (48%) underwent gross total resection and thirteen patients (52%) had subtotal resection. Out of twelve patients who underwent gross total resection, eight (66.6%)) had tumor in frontal location.

Out of twenty five patients , twenty two patients (88%) had pure Anaplastic Oligodendroglioma and three patients (12%) had mixed Anaplastic Oligodendroglioma.

Table 1 contains clinical summary of the twenty five patients. All patients followed up for median period 96 months (24-180 months).

Table 1 Patient clinical summary.

	N	Percentage
Total no of patients	25	100
Age in median (range)	36 yrs(23-74 yrs)	
Male/Female	14/11	56/44
Histology Pure AO Mixed AO	22 3	88 12
Symptom Seizure Headache Motor deficit	12 11 2	48 44 08
Site Frontal Temporal Parital	17 5 3	68 20 12
Surgical resection GTR STR	12 13	48 52

Details of treatment:

Surgery

All the patients were treated with maximal safe surgical resection either gross total resection or subtotal resection depending of the tumor

location.

Radiotherapy

Out of twenty five, five patients (20%) were treated with adjuvant external beam radiotherapy alone and about twenty (80%) patients were treated adjuvant chemoradiation. Planning target volume (PTV) for Anaplastic Oligodendroglioma encompasses the Magnetic resonance image –defined Gross tumor volume (GTV) with a 1.5 to 2 cm margin. All the patients treated with a dose of 59.4 Gy to 60 Gy in a daily fraction of 1.8 to 2 Gy over 6 -7 weeks. Figure 1 contain summary of adjuvant treatment of twenty five patients.

Figure-1

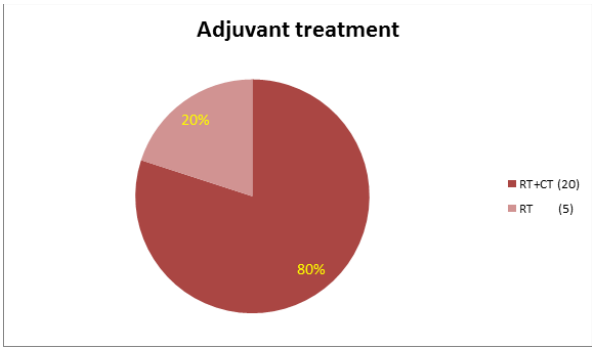

Chemotherapy

Out of twenty patient received chemotherapy, Seventeen patients (85%) treated with adjuvant chemoradiation with Tablet Temozolamide at a dose of 75mg/m2/day for 42 days and had maintenance T.Temozolamide at a dose 150 mg/m2/day for first five day of the months for 6 months.

Out of twenty patients received chemotherapy, three (15%) treated with adjuvant radiation followed by chemotherapy with PCV for 6 months.Figure-2 contains chemotherapy regime.

Figure 2

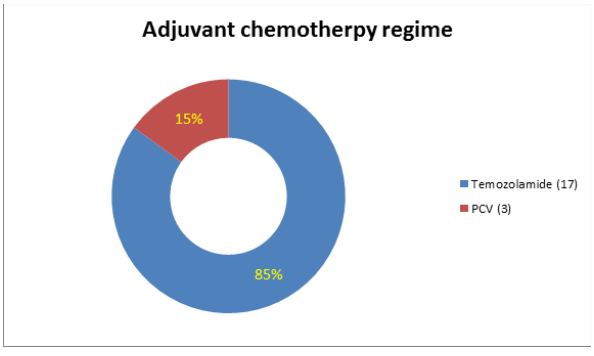

Stastical analysis

Progression free survival was assessed between date of surgery until evidence of recurrence/progression or neuro-deterioration.Stastical study is done with help of chi-square test. The results were statistically significant at the level of $P<0.05$.In univariate analysis, the variable analyzed includes chemotherapy, site of the disease, type of surgical resection, age and sex.

Follow up

After the treatment patients were followed up at 3 months interval for first 3 years, 6 months interval up to 5 years and at 1 year interval thereafter. The patients who presented with recurrence/progression in the follow up time submitted to resection if possible.

RESULTS

Progression free survival

For all 25 patients five year progression free survival was 50 %.Of these treated with chemo radiotherapy was 54.5% and only radiotherapy was 40 %.

Overall survival

The 5 year overall survival for all patients was 75%. The 5 year OS rate of patient treated with chemo radiotherapy was 81.8% and only radiotherapy was 60%.

Univariate analysis

The variable include age , sex, site of disease, type of surgical resection and chemotherapy.

None of the variable statistically significant. Table 2 shows 5 years PFS with variable.

Table 2 Univariate analysis

Parameter	5 years Progression Free Survival (%)	Chi-Square statistic	P-Value
Age <40yrs (n-12) >40yrs (n- 4)	58.3 25	1.33	0.13
Sex Male (n-9) Female (n-7)	33.3 71.4	2.28	0.13
Site Frontal (n-12) Temporal(n-4) Parital (n-0)	58.3 25	1.33	0.24
Surgical resection GTR (n-9) STR (n-7)	55.5 42.8	0.25	0.61
Chemotherapy RT+CT (n-11) RT (n-5)	54.5 40	0.58	0.29

DISCUSSION

Surgery is the primary therapeutic approach for Anaplastic Oligodendroglioma.It requires external beam radiotherapy (or) chemoradiation to improve the progression free survival and overall survival. Since the 1990 s, radiation therapy has represented an integral part of management of Anaplastic Oligodendroglioma. (5) The importance and the efficacy of radiotherapy were demonstrated in retrospective studies and in recent randomized prospective trails. (6,7) It indicates that postoperative external beam radiation is highly recommended in a patients with Anaplastic Oligodendroglioma.External beam radiotherapy is usually administered in standard fractions of 1.8 to 2 Gy and can reach a total dose in a range of 54 -60 Gy .[8]

The role of adjuvant chemoradiation has been widely discussed .It is well known that glioma originating from oligodendrocytes are highly sensitive to nitrosurea –based concurrent chemo radiation such as PCV schedule. (9) Originally chemo sensitivity was demonstrated in patients who relapsed after external beam radiotherapy, (10-15) than, PCV become the subject of study in numerous clinical trials as chemotherapeutic regimen used as first line approach . (16,17) A retrospective long term analysis of two large randomized trails, EORTC 26951 and RTOG 9402 (18,19) has demonstrated that patients with newly diagnosed Anaplstic Oligodendroglioma /Anaplasit Oligoastrocytoma ,which harbors 1p/19q co-deletion , benefit from addition of PCV to standard RT. In contrast, in patients without deletion, Overall survival dose not differ significantly. Recently , a large retrospective study of > 1000 anaplastic glioma conducted by Lassman et al showed that in patients treated with chemo radiation or chemotherapy alone, temozolamide (TMZ) was used far more often than PCV from 2005 to 2007 (87% vs 2%). (20) There is no formal comparisons between PCV vs TMZ . TMZ is generally preferred nowadays its ease of administration , good tolerability and minimal myelotoxicity . It makes TMZ is a good alternative.

In our study 5 year progression free survival and overall survival respectively 50 % and 75%.In particular patient treated with adjuvant chemo radiation 5 year progression free survival and overall all survival respectively 54.5%and 81.1%. A retrospective study (21) also shows patients treated with adjuvant chemo radiation 5 year progression free survival and overall survival respectively 55.1% and 83.5%.

Our study revealed that tumor located in the frontal lobe had better 5 years progression free survival than other sites. Some studies have shown that patients with frontal lobe Oligodendrogliomas live significantly longer than patients with tumor located elsewhere (22-24) , while others (25) fails to demonstrates the relevance. There is association between 1p/19 q co-deletion and tumor location also explained.(26) Our study also shows 8/12 (66.6%) frontal location tumor had gross tumor resection.

Our study shows that gross tumor resection had better progression free survival compare to sub-total resection 55.5% and 42.8%.In particular a resection of >90% of the contrast- enhancing volume appears to improve both PFS and OS. (27) In the literature, a prospective study conducted on 560 patients with high grade gliomas demonstrated that resection is a strong prognostic factor (P<0.001) compare to with biopsy. [5]

Our study we identified sex and age also as factors of prognostic importance in univariate analysis. Patient less than 40yrs had better progression free survival (58.3%vs25%). Some studies have demonstrated that patients younger than 40 or 50 years survive longer than older patients (28) ,while this has not been confirmed by others. (29)Female sex also had better progression free survival compare to male sex. Sex is rarely reported a prognostic variable in glioma , although female patients with high grade glioma have a better prognosis than their counter parts and that hormones (or) tumor suppressor gene on the X chromosome may be associated with longer survival. [30]

Our study had some limitation as its retrospective study not analyzed on 1p/19 q co – deletion as lack of some data.

CONCLUSION

The use of adjuvant chemo radiation in Anaplstic Oligodendroglioma after maximal safe surgical resection show good progression free survival and overall survival. Age, sex, site tumor, and extent of the resection also as a factor of prognostic importance but not statistically significant.

REFERENCE

1. Reifenberger G, Kros J, Louis D, Collins V, editors. Anaplastic oligodendroglioma. 3rd ed. Lyon: WHO Press; 2007.
2. Ohgaki H, Kleihues P. Populationbased studies on incidence, survival rates, and genetic alterations in astrocytic and oligodendroglial gliomas. J Neuropath Exp Neurol.2005;64:47989.
3. Dolecek TA, Propp JM, Stroup NE, Kruchko C. CBTRUS statistical report: primary brain and central nervous system tumors diagnosed in the United States in 2005–2009. Neuro Oncol. 2012;14(suppl 5):v1v49
4. Kros JM, Lie ST, Stefanko SZ. Familial occurrence of polymorphous oligodendroglioma. Neurosurgery. 1994;34(4):732–736.
5. Roth P, Wick W, Weller M. Anaplastic oligodendroglioma: a new treatment paradigm and current controversies. Curr Treat Opt Oncol. 2013;14(4):505–513.
6. van den Bent MJ, Carpentier AF, Brandes AA, et al. Adjuvant procarbazine, lomustine, andvincristine improves progression free survival but not overall survival in newly diagnosed anaplastic oligodendrogliomas and oligoastrocytomas: a randomized European Organisation for Research and Treatment of Cancer phase III trial. J Clin Oncol. 2006;24:2715–2722.
7. Cairncross G, Berkey B, Shaw E, et al. Phase III trial of chemotherapy plus radiotherapy compared with radiotherapy alone for pure and mixed anaplastic oligodendroglioma: Intergroup Radiation Therapy Oncology Group trial 9402. J Clin Oncol. 2006;24:2707–2714.
8. Brandes A. Linee Guida Neoplasie Cerebrali. Milano: Associazione Italiana di Oncologia Medica (AIOM); 2014.
9. Cairncross JG, Macdonald DR, Ramsay DA. Aggressive oligodendroglioma: a chemosensitive tumor. Neurosurgery. 1992;31(1):78–82.
10. Brandes AA, Tosoni A, Vastola F, et al. Efficacy and feasibility of standard procarbazine, lomustine, and vincristine chemotherapy in anaplastic oligodendroglioma and oligoastrocytoma recurrent after radiotherapy. A Phase II study. Cancer. 2004;101:2079.
11. Cairncross G, Macdonald D, Ludwin S, et al. Chemotherapy for anaplastic oligodendroglioma. National Cancer Institute of Canada Clinical Trials Group. J Clin Oncol. 1994;12:2013.
12. van den Bent MJ, Kros JM, Heimans JJ, et al. Response rate and prognostic factors of recurrent oligodendroglioma treated with procarbazine, CCNU, and vincristine chemotherapy. Dutch Neurooncology Group. Neurology. 1998;51:1140.
13. Soffietti R, Rudà R, Bradac GB, Schiffer D. PCV chemotherapy for recurrent oligodendrogliomas and oligoastrocytomas. Neurosurgery. 1998;43:1066.
14. Mason WP, Krol GS, DeAngelis LM. Low grade oligodendroglioma responds to chemotherapy. Neurology. 1996;46:203.
15. Buckner JC, Gesme D, Jr, O'Fallon JR, et al. Phase II trial of procarbazine, lomustine, and vincristine as initial therapy for patients with low grade oligodendroglioma or oligoastrocytoma: efficacy and associations with chromosomal abnormalities. J Clin Oncol. 2003;21:251.
16. Brandes AA, Tosoni A, Cavallo G, et al. Correlations between O6methylguanine DNA methyltransferase promoter methylation status, 1p and 19q deletions, and response to temozolomide in anaplastic and recurrent oligodendroglioma: a prospective GICNO study. J Clin Oncol. 2006;24:4746.
17. van den Bent MJ, Taphoorn MJ, Brandes AA, et al. Phase II study of firstline chemotherapy with temozolomide in recurrent oligodendroglial tumors: the European Organization for Research and Treatment of Cancer Brain Tumor Group Study 26971. J Clin Oncol. 2003;21:2525.
18. van den Bent MJ, Brandes AA, Taphoorn MJ, et al. Adjuvant procarbazine, lomustine, and vincristine chemotherapy in newly diagnosed anaplastic oligodendroglioma: longterm followup of EORTC brain tumor group study 26951. J Clin Oncol. 2013;31(3):344–350.
19. Cairncross G, Wang M, Shaw E, et al. Phase III trial of chemoradiotherapy for anaplastic oligodendroglioma: long term results of RTOG 9402. J Clin Oncol. 2013;31(3):337–343.
20. Lassman AB, Iwamoto FM, Cloughesy TF, et al. International retrospective study of over 1000 adults with anaplastic oligodendroglial tumors. Neuro Oncol. 2011;13(6):649–659.
21. Subhash Gupta, Haresh Kunhiparambath, Rony Benson,etal. Long term outcomes of patients with anaplastic oligodendroglioma treated in a tertiary care centre in India. J Clin Oncol 34, 2016 (suppl; abstr e13517)
22. Engelhard HH, Stelea A, Mundt A. Oligodendroglioma and anaplastic oligodendroglioma: clinical features, treatment, and prognosis, Surg Neurol , 2003, vol. 60 (pg. 443-456)
23 Kros JM, Pieterman H, Van Eden CG, Avezaat CJ. Oligodendroglioma: the Rotterdam-Dijkzigt experience, Neurosurgery , 1994, vol. 34 (pg. 959-966).
24 Shaw EG, Scheithauer BW, O'Fallon JR, Tazelaar HD, Davis DH. Oligodendrogliomas: the Mayo Clinic experience, J Neurosurg , 1992, vol. 76 (pg. 428-434).
25. Mork SJ, Lindegaard KF, Halvorsen TB, et al. . Oligodendroglioma: incidence and biological behavior in a defined population, J Neurosurg , 1985, vol. 63 (pg. 881-889).
26. Zlatescu MC, TehraniYazdi A, Sasaki H, et al. . Tumor location and growth pattern correlate with genetic signature in oligodendroglial neoplasms, Cancer Res , 2001, vol. 61 (pg. 6713-6715).
27. Polivka J, Jr, Polivka J, Rohan V, et al. New treatment paradigm for patients with anaplastic oligodendroglial tumors. Anticancer Res. 2014;34(4):1587–1594.
28. Kros JM. Oligodendrogliomas: clinicopathological correlations, J Neurooncol , 1995, vol. 24 (pg. 29-31)
29. Mork SJ, Lindegaard KF, Halvorsen TB, et al. . Oligodendroglioma: incidence and biological behavior in a defined population, J Neurosurg , 1985, vol. 63 (pg. 881- 889)
30. Shinojima N, Kochi M, Hamada J, et al. . The influence of sex and the presence of giant cells on postoperative long-term survival in adult patients with supratentorial glioblastoma multiforme, J Neurosurg , 2004, vol. 101 (pg. 219-226)