Volume : 3 | Issue : 1 | January 2014 • ISSN No 2277 - 8179

Research Paper

P Wave Morphological Changes in Ecg and its Correlation with Clinical, Radiological and 2 D Echo Profile in Cardiovascular Disorders

Medical Science

KEYWORDS : P wave, ECG, 2D Echo, Cardiovascular diseases

Dr. Bhavesh K. Patel	Assistant Professor ,Department of Medicine., SBKS MIRC , Piparia, Vadodara
Dr. Bhavita B. Patel	Resident Doctor in Department of Cardiology, U.N.Mehta Heart institute & Research Center ,Ahmedabad
Dr. Nirmit V. Yajnik	Professor , Department of Medicine., SBKS MIRC , Piparia, Vadodara
Dr. Priyank Mody	Assistant Professor ,Department of Medicine., SBKS MIRC , Piparia, Vadodara
Dr. Jit Brahmbhatt	Resident Doctor,Department of Medicine., SBKS MIRC , Piparia, Vadodara
Dr. Rajesh Patel	Resident Doctor,,Department of Medicine., SBKS MIRC , Piparia,Vadodara

ABSTRACT

Title: P wave morphological changes in ECG and its correlation with clinical, radiological and 2 D Echo profile in cardiovascular disorders

Introduction: ECG is the easiest diagnostic tool. P wave morphological changes are found in cardiovascular disorders. These changes suggest many changes in heart and correlated with echocardiography. and can be used as diagnostic tool and severity of condition.

Aims and objectives: 1)To study P wave morphological changes in ECG in cardiovascular disorders.2)To Establish correlation between P wave morphological changes in ECG with clinical, radiological, and Echo profile in cardiovascular disorders.

Materials and methods: A prospective study of 100 cardio-vascular disorders cases having P wave changes in ECG from March 2011 for one and half year in Dhiraj Hospital. All P wave changes were correlated with clinical, radiological and 2 D Echo profile.

Results: Amongst 50 cardiac cases 40 had RHD and 10 had IHD. Amongst cardiac cases P wave duration in lead II and P terminal force in lead V1 were significantly co related with LA in RHD cases (p value<0.05), while in IHD cases with P wave changes they were not correlated (p value>0.05).In RHD cases P wave duration in lead II had moderate correlation with LA (r value =0.6), while P terminal force in lead V1 has poor correlation with LA (r value=0.38) .

Conclusion: To conclude from this study, P wave morphology changes in ECG has significant correlation with severity of disease and chamber enlargement in left sided valvular heart disease, but not in IHD.

INTRODUCTION

Cardiovascular disorders are the major health problem across the globe and more in developing countries . Delay in diagnosis and treatment is one of the key factors for early morbidity and mortality associated with it.

Poor hygiene and lifestyle are associated with conditions like Rheumatic heart diseases, Ischemic heart diseases, Hypertension etc.

Electrocardiogram (ECG) is the one of the basic diagnostic tool which can be helpful in early diagnosis and delaying morbidity and mortality associated with cardiovascular disorders.

ECG is the record of time-varying bio-electric potential generated by the electrical activity of heart. It is used to measure the functional activity of heart. Nobel Laureate, William Einthoven has first recorded the ECG in 1903. Due to the ease of use and non invasiveness, ECG is not only used as a prime tool to diagnose the various cardio- respiratory disorders affecting the heart but also to monitor it.[1]

P wave abnormalities on the resting ECG have been associated with abnormal atrial size in pulmonary or cardiovascular disease. Abnormalities of P wave morphology have a limited sensitivity for echocardiographic findings and have been associated with left sided heart diseases or severe lung disease. [2]

Morris and co-workers[9] found that the algebraic product of the duration and amplitude of the terminal portion of the P wave in V_1 (P terminal force) allowed them to separate patients with left sided valvular heart disease from normal subjects in 92% of their series. Hence they used the nonspecific term "left atrial involvement" as a definition of P wave changes associated with left sided heart diseases.[3]

Calatayud and co-workers found P amplitude has shown a positive correlation with radiological evidence of chronic obstructive lung disease.[4]

P pulmonale has been used as indirect evidence of right ventricular hypertrophy by various authors and is also helpful in diagnosing chronic obstructive lung disease and pulmonary hypertension and cor pulmonale associated with it.[5]

Thus P wave abnormalities are common findings that should not be ignored. And various P wave parameters can be useful with its diagnostic and prognostic value. And these P wave morphology changes are also helpful in early diagnosis and delaying morbidity and mortality in cardiovascular and respiratory disorders.[2]

AIMS AND OBJECTIVES

To study P wave morphological changes in ECG in Cardiovascular disorders. And to study clinical, radiological and Echo profile of those cases.

Establish correlation between P wave morphological changes in ECG with clinical, radiological, and Echo profile in Cardiovascular disorders.

MATERIAL & METHODS:

This is a prospective observational study of 50 patients admitted over one and a half year between 2011-12 in Dhiraj Hospital & SBKS MIRC ,Vadodara.

Patients of cardiac disorders who were admitted in ICU & ICCU were screened and such patient who had P wave morphology changes in their ECG were taken into study. Cases who were taken were evaluated on history, symptomatology, examination, investigations, radiology (chest X ray), 2D ECHO mainly (Right Ventricle (RV), Right Ventricle systolic pressure (RVSP), Left atrium (LA), Ejection fraction (EF) & other parameters), P wave morphology is evaluated and correlated in detail with above mentioned parameters.

All 2D ECHO were done by cardiologist with GE Vivid-echo-machine. All ECG were taken by automated BPL ECG machine. All recordings were confirmed manually. IHD cases that have

Volume : 3 | Issue : 1 | January 2014 • ISSN No 2277 - 8179

P wave morphology changes in ECG and were taken in to study were proven by coronary angiography also.

METHOD:
Each patient first will be evaluated and history will be taken and will be investigated for the routine labs. And re- evaluated in detail.

ECG- All P wave parameters were evaluated in detail. All ECGs were evaluated with magnifying glass and if needed then scanned copies were evaluated with zooming in with the software. As P wave is best seen in lead II and V_1, both leads were evaluated in detail under following parameters.

1) P wave duration in lead II
2) P wave amplitude in lead II
3) P: PR segment in lead II (*Marcus Index:* The ratio between duration of P wave and P-R segment)
4) P axis
5) P inclination in lead V1
6) P terminal force in lead V1 (*Morris index:* The "P" terminal force in lead V_1. Morris index is derived by multiplying the depth of the terminal "P" wave deflexion in mm in V_1 by the duration (in seconds). The value is expressed in millimeter-seconds (mm.sec). Normally up to 0.03 mmsec)

Chest X-Ray- to see cardiomegaly, emphysema, mitralzation of heart etc

2D ECHO – is useful in both diagnosis and for correlation of parameters. M-mode is used where Left atrium, interventricular septum and posterior wall are visualized. Left ventricular end diastolic and systolic pressures are measured to calculate fractional shortening and EPSS which all in turn helps in assessing systolic dysfunction. In 2D echo- ejection fraction-visual is measured in addition to RV, LV and LA sizes which help in assessing diastolic dysfunction. In Doppler Mitral Regurgitation (MR), Tricuspid Regurgitation (TR) and changes of Pulmonary arterial hypertension PAH (RVSP) are noted in addition to mitral valve study (E/A). If tissue Doppler is done then it helps in assessing mitral valve for E'/A'**.** Planimetry is used to calculate mitral valve area and for gradation of mitral stenosis.

CBC, RFT, LFT, RBS, Electrolytes are routine investigations. Other investigations if required.

INCLUSION CRITERIA
Patients of Cardiovascular disorders who had P wave morphology changes in their ECG admitted in ICU & ICCU.

Patients who are 18yrs or older in age, and give consent to be part of this study.

EXCLUSION CRITERIA:
Patients below 18 yrs of age.
Patients who do not give their consent to be a part of this study

STATISTICAL METHODS :
Data was cleaned, Validated and Analyzed by SPSS 20.0 & Epi. Info 7 software.

Descriptive Statistics:
For continuous variable range, mean and standard deviation were calculated and for categorical variables proportion and percentage were obtained.

Bi-Variate analysis:
To know the association between dependent and independent variable chi-square and correlation applied accordingly.

In our study we have taken following ECG and 2D Echo parameters as significant parameters;

ECG :
P wave duration in lead II > 0.12 second.
P amplitude >2.5 mm in lead II (P pulmonale)
P:PR segment >1.6 in lead II
P inclination >1.5 in lead V_1
Negative P terminal force >=0.04 in lead V_1
P axis >=+90^0 in RS cases and LAD of P axis for CVS cases

2D Echo:
Left Atrial Enlargement (LAE) : LA > 38 mm or > 3.8 cm

Right Ventricular Enlargement (RVH) : RV > 25 mm or > 2.5 cm

Pulmonary hypertension (PAH): Right Ventricular Systolic Pressure (RVSP)>35 mmHg

Ejection Fraction : <50%

RESULTS
Out of 50 patients of cardiovascular system who had P wave changes in ECG, 20(40%) were male and 30(60%) were female. Out of that 40(80%) patients had RHD while 10 (20%) had IHD. In RHD cases out of 40 cases 28(70%) were Females , while in IHD out of 10 cases only 2 (20%) were females. Amongst 40 RHD, all have mainly mitral senosis with or without other lesion. All 10 IHD cases were proven by coronary angiography. Amongst 40 cases of RHD with P wave changes, dyspnoea was presenting complaint in 35 (88%)cases, palpitation in 19 (48%) cases, while 12 (30%) presented with oedema also as a presenting complaint. All 10 cases of IHD with P wave changes presented with chest pain as only complaint.

Chest x ray Amongst 40 cases of RHD with P wave changes, mitralization of heart was found in 20 (50%) patients, while cardiomegaly was found in 11 (28%) cases. Amongst 10 cases of IHD with P wave changes, cardiomegaly was found in 2 (20%) cases.

P wave changes distribution.

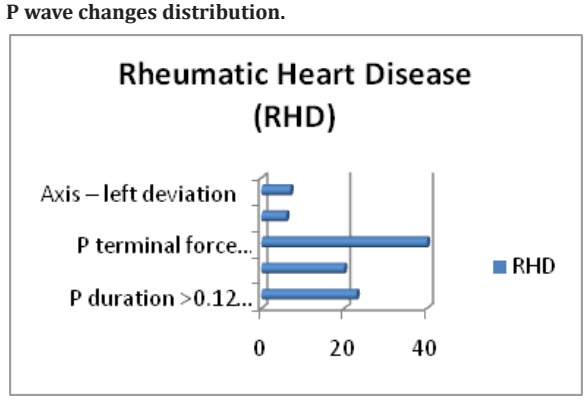

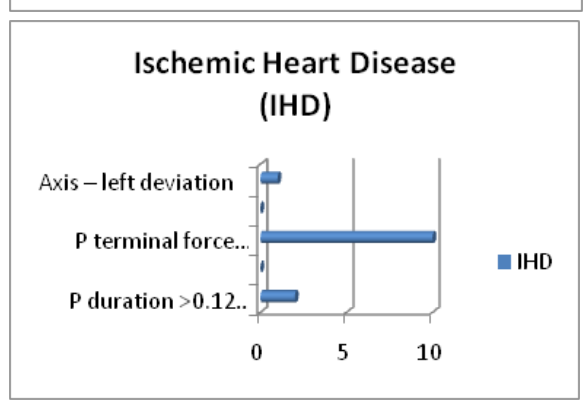

P wave changes in RHD
Out of 40 cases of RHD who had P wave changes P terminal force>=0.04 mmsec was found in all 40 cases, followed by P duration >0.12 sec in lead II was found in 23 cases and P: PR >1.6 in lead II was found in 20 cases. Axis deviation to Left was found in 7 cases.

P wave changes in IHD
Out of 10 cases of IHD who had P wave changes, P terminal

force>=0.04 mmsec was found in all 10 cases , followed by P duration >0.12 in lead II was found in 2 cases and Axis deviation to Left was found in 1 case.

2D ECHO Findings:

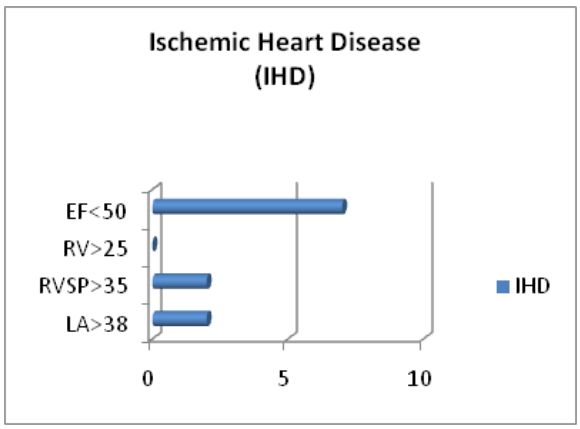

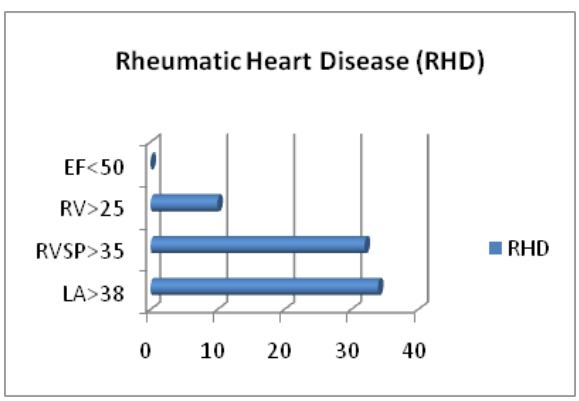

2D ECHO findings in RHD: All 40 cases of RHD with P wave changes have primarily mitral valve involvement in the form of stenosis or regurgitation, associated tricuspid regurgitation was found in few patients.

2D Echo assesment of RHD with P wave changes : Most common findings were, LA>38 mm was found in 34(85%) cases ,while RVSP>35mmHg was found in 32(80%) cases, RV>25 mm was found in 10(25%) cases, while no patient of RHD had EF < 50%.

2D Echo findings in IHD: In 2D Echo assesment of IHD with P wave changes ,most common findings were EF< 50% was found in 7(70%) cases ,while RVSP>35 mmHg and LA > 38 mm was found in 2 patients.

Correlation between P wave changes & 2D Echo in CVS.

Cases with LA>38mm	P duration >0.12 sec in lead II	P:PR segment> 1.6 in lead II	P terminal force >= 0.04 mmsec in lead V_1	P axis deviation to left
RHD(34)	23	19	34	7
IHD (2)	0	0	2	1
Total (36)	23	19	36	8

Out of 40 RHD cases. Left atrial enlargement (LAE) (LA>38 mm) was found in 34 cases. Amongst those 34, P wave changes were P terminal force>0.04 mmsec in lead V_1 was found in all cases, followed by P duration >0.12 sec was in 23 cases, P: PR >1.6 in 19 cases, and P axis deviation to left was found in 7 cases. While in 10 IHD cases. LAE (LA>38 mm) was found in 2 cases. Amongst those 2, P wave changes were P terminal force>0.04mmsec in lead V_1 was found in both the cases , followed P axis deviation to left in 1 case.

Statistical analysis :
Correlation between P wave and LA parameters.
Table 2.13- Statistical analysis in CVS cases.

Parameters	RHD	IHD
	LA	
P wave duration in lead II	p =0.01 r =0.6	p = 0.1 r = (-0.4)
P terminal force in lead V_1	p =0.01 r = 0.38	p =0.2 r =(-0.4)

P wave duration in lead II and P terminal force in lead V_1 were significantly correlated with LA in RHD cases (p value<0.05), while in IHD cases with P wave changes, they were not correlated (p value>0.05). In RHD cases P wave duration in lead II had moderate correlation with LA (r value =0.6), while P terminal force in lead V_1 has poor correlation with LA (r value=0.38).

DISCUSSION:
In a study by Morris et al, 21 patients with normal-sized left atria on x ray and proven left-sided valvular lesions, 15 had abnormal P terminal forces. Thus, the presence of a large left atrium (radio graphically) was unnecessary to produce an abnormal P terminal force. In present study also, out of 40 RHD (MS) cases mitralization of heart was found in 20 cases while LAE was in 34 cases; however an abnormal P terminal force was found in all 40 cases.[15]

In a study of 37 cases by M. B. Shirley Rubler et al, 32 cases had left side valvular disease. Majority of which had mitral valve involvement which showed good correlation between P wave duration in lead II and P terminal force in V_1 with LA diameter. In our study also, all cases of RHD (mainly mitral valve involvement) showed moderate correlation with P wave duration in lead II and poor correlation in P terminal force in lead V_1 with LA diameter.[7]

In a study of 307 patients by Waggoner et al between P wave parameters(mainly P wave duration in lead II and P terminal force in lead V_1) showed that P wave morphology may be used as a reasonably specific but less sensitive indicator of left atria enlargement. In our study also both P wave duration in lead II and P terminal force in lead V_1 correlated moderately and poorly with left atria enlargment.[8]

Reliable ECG evidence of atria abnormality and the precise differentiation of right and left atria overloading can be extremely useful in the differential diagnosis of cardiac lesions. In more recent years, several criteria have been proposed for the conventional 12-lead electrocardiogram (ECG). The terminal P forces in the right precordial leads have been widely accepted as indicative of left atria overload (LAO).

In a study of 213 patients by James Morris et al 100 patients with valvular heart disease, P terminal force was abnormal in 75% of left sided valvular heart diseases and correlated 92% with left sided valvular heart diseases and suggested once a given valve lesion is suspected clinically, this measure enables one to make an estimation of the severity of that lesion from the degree of the abnormality of the P terminal force at V_1. In our study also P terminal force > or = 0.04 mmsec was found in all left sided valvular heart diseases patients and also correlated with left atrial enlargement. This signifies high abnormal prevalence of abnormal P terminal force in lead V_1 in left sided valvular heart diseases(out of which majority having severe mitral stenosis) and helps to make an estimation of the severity of the lesion from the degree of the abnormality of the P terminal force in lead V_1.[3,9]

Changes in the pattern of atrial depolarization have long been recognized as reflecting haemodynamic or anatomical changes affecting the atria. Changes in the morphology of the P wave in the electrocardiogram have been considered useful indications of left and right atrial abnormalities. The validity

of these assumptions in the estimation of left atrial size has been tested against direct observations at the time of surgery (Saunders et al., 1967; Martins de Oliveira and Zimmerman, 1959), measurements from various radiological views of the heart (Arevalo,Spagnolo, and Feinstein, 1963), and from postmortem studies (Abildskov, 1957). These techniques, however, have significant drawbacks, namely, that x-ray studies measure only gross changes in the atria and postmortem studies are nonphysiological, static measurements. By cineangiography, however a better demonstration of left atrial contour has permitted more accurate measurements to be made (Soloff and Zatuchni, 1958; Kasser and Kennedy, 1969). But in view of the invasive nature and complexity of this procedure its utility in evaluating a large population is limited. Echocardiography, on the other hand, has been shown to provide a good measure of the left atrium (LA) when compared with careful angiographic studies (Hirata et al., 1969), hence providing us with an accurate noninvasive technique for obtaining anatomical measurements. In their study the validity of various electrocardiographic measurements believed to reflect left atrial enlargement was tested against echocardiographic measurements of the left atrium.

In a study of 48 patients by Raul Chirife et al between left atrial enlargement and P wave morphology showed good correlation between P wave duration in lead II and moderate correlation with P terminal force in lead V_1 with LA size. In our study also both the parameters, P wave duration in lead II correlated moderately with LA size and P terminal force in lead V_1 correlated poorly with LA size.[10]

In a study of 52 patients of ischemic heart diseases by U. R. Shettigar et al between P wave parameters and 2D echo showed no correlation between P terminal force and LA size. However, P terminal force > 0.02 was noted in 69% of the coronary artery diseases' patients. In our study also though P terminal force in lead V_1 was >= 0.04 in all cases of ischemic heart diseases, P terminal force in lead V_1 was not correlated with LA size.[11]

CONCLUSION

Since after the discovery of ECG, still it has maintained its role as a basic screening, diagnostic and monitoring tool.

P wave changes in ECG by various parameters should not be neglected and can be used as a screening, diagnostic and monitoring parameter in various cardio- respiratory disorders. These P wave parameters will be helpful in early diagnosis and delaying morbidity and mortality associated with cardiovascular disorders.

Because of significant correlation between P wave parameters in ECG with radiological and echocardiography parameters, these ECG changes can be used as a screening, diagnostic and monitoring parameter.

In cardiovascular diseases negative P terminal force in lead V_1>=0.04 mmsec, P wave duration >0.12 sec in lead II, and P:PR segment >1.6 can be helpful in diagnosing Left sided heart disease mainly Left sided valvular diseases like MS,MR etc

REFERENCE

1. Geddes L. A. et al, the first electronic electrocardiograph, cardiovascular engineering, an international journal, 2002 v-2, n-2, pp 73-79. | 2. Amir kaykha et al, the prognostic importance of isolated P wave abnormalities, journal of clinical cardiology, may 2010:1-7. | 3. Morris J. et al P-Wave Analysis in Valvular Heart Disease, AHA journals 1964;29: 242-248 | 4. Calatayud J.B. et al , P wave changes in COPD, American heart journal , 1970 79, 444. | 5. Padmavati S. et al, ECG in chronic cor pulmonale, British heart journal ,1972,34, 658-667 | 6. Harrisons et al, book on internal medicine, 17th edition, chapter 9, section 2,221. | 7. M.D. Shirley Rubler et al, Comparison of left atrial size and pulmonary capillary pressure with P wave of electrocardiogram, American Heart Journal, , July 1976,Volume 92, Issue 1, Pages 73–78 | 8. Waggoner et al, LA Enlargement: ECHO-ECG Correlation/. AHA journals , OCTOBER 1976,VOL 54, No 4, | 9. Morris et al ,P-Wave Analysis in Valvular Heart Disease, AHA journals 1964;29:248-252 | 10. Raul Chirife et al,Electrocardiographic detection of left atrial enlargement Correlation of P wave with left atrial dimension by echocardiography ,British Heart journal, 1975, 37, 1281-1285. | 11. U. R. SHETTIGAR et al, P wave analysis in ischemic heart disease An echocardiographic, haemodynamic, and angiographic assessment, British Heart Journal, 1977, 39, 894-899 | 12. Leo Schamroth, Colin Schamroth. An introduction to Electrocardiography. 7th edition, 1990, 52, 54, 78, 211, 234pp. |